











Cite this article as: Czerny M, Grabenwöger M, Berger T, Aboyans V, Della Corte A, Chen EP *et al.* EACTS/STS Guidelines for diagnosing and treating acute and chronic syndromes of the aortic organ. *Eur J Cardiothorac Surg* 2024; doi:10.1093/ejcts/ezad426.

## EACTS/STS Guidelines for diagnosing and treating acute and chronic syndromes of the aortic organ

**Authors/Task Force Members:** Martin Czerny <sup>a,b,x,t</sup> (Co-Chairperson) (Germany), Martin Grabenwöger<sup>c,d,x,t</sup> (Co-Chairperson) (Austria), Tim Berger<sup>a,b</sup> (Task Force Coordinator), Victor Aboyans<sup>e,f</sup> (France), Alessandro Della Corte <sup>g,h</sup> (Italy), Edward P. Chen<sup>i</sup> (USA), Nimesh D. Desai<sup>j</sup> (USA), Julia Dumfarth <sup>k</sup> (Austria), John A. Eleftheriades<sup>l</sup> (USA), Christian D. Etz<sup>m</sup> (Germany), Karen M. Kim<sup>n</sup> (USA), Maximilian Kreibich<sup>a,b</sup> (Germany), Mario Lescan <sup>o</sup> (Germany), Luca Di Marco<sup>p</sup> (Italy), Andreas Martens <sup>q,r</sup> (Germany), Carlos A. Mestres <sup>s</sup> (South Africa), Milan Milojevic <sup>t</sup> (Serbia), Christoph A. Nienaber <sup>u,v</sup> (UK), Gabriele Piffaretti<sup>w</sup> (Italy), Ourania Preventza<sup>x</sup> (USA), Eduard Quintana<sup>y</sup> (Spain), Bartosz Rylski <sup>a,b</sup> (Germany), Christopher L. Schlett<sup>b,z</sup> (Germany), Florian Schoenhoff<sup>aa</sup> (Switzerland), Santi Trimarchi<sup>ab</sup> (Italy) and Konstantinos Tsagakis <sup>ac</sup> (Germany), EACTS/STS Scientific Document Group

<sup>a</sup> Clinic for Cardiovascular Surgery, Department University Heart Center Freiburg Bad Krozingen, University Clinic Freiburg, Freiburg, Germany

<sup>b</sup> Faculty of Medicine, Albert Ludwigs University Freiburg, Freiburg, Germany

<sup>c</sup> Department of Cardiovascular Surgery, Clinic Floridsdorf, Vienna, Austria

<sup>d</sup> Medical Faculty, Sigmund Freud Private University, Vienna, Austria

<sup>e</sup> Department of Cardiology, Dupuytren-2 University Hospital, Limoges, France

<sup>f</sup> EpiMaCT, Inserm 1094 & IRD 270, Limoges University, Limoges, France

<sup>g</sup> Department of Translational Medical Sciences, University of Campania "L. Vanvitelli", Naples, Italy

<sup>h</sup> Cardiac Surgery Unit, Monaldi Hospital, Naples, Italy

<sup>i</sup> Division of Cardiovascular and Thoracic Surgery, Duke University Medical Center, Durham, NC, USA

<sup>j</sup> Division of Cardiovascular Surgery, University of Pennsylvania, Philadelphia, PA, USA

<sup>k</sup> University Clinic for Cardiac Surgery, Medical University Innsbruck, Innsbruck, Austria

<sup>l</sup> Aortic Institute at Yale New Haven Hospital, Yale University School of Medicine, New Haven, CT, USA

<sup>m</sup> Department of Cardiac Surgery, University Medicine Rostock, University of Rostock, Rostock, Germany

<sup>n</sup> Division of Cardiovascular and Thoracic Surgery, The University of Texas at Austin/Dell Medical School, Austin, TX, USA

<sup>o</sup> Department of Thoracic and Cardiovascular Surgery, University Medical Centre Tübingen, Tübingen, Germany

<sup>p</sup> Cardiac Surgery Unit, IRCCS Azienda Ospedaliero-Universitaria di Bologna, Bologna, Italy

<sup>q</sup> Department of Cardiac Surgery, Klinikum Oldenburg, Oldenburg, Germany

<sup>r</sup> The Carl von Ossietzky University Oldenburg, Oldenburg, Germany

<sup>s</sup> Department of Cardiothoracic Surgery and the Robert WM Frater Cardiovascular Research Centre, The University of the Free State, Bloemfontein, South Africa

<sup>t</sup> Department of Cardiac Surgery and Cardiovascular Research, Dedinje Cardiovascular Institute, Belgrade, Serbia

<sup>u</sup> Division of Cardiology at the Royal Brompton & Harefield Hospitals, Guy's and St. Thomas' NHS Foundation Trust, London, UK

<sup>v</sup> National Heart and Lung Institute, Faculty of Medicine, Imperial College London, London, UK

<sup>w</sup> Vascular Surgery Department of Medicine and Surgery, University of Insubria School of Medicine, Varese, Italy

<sup>x</sup> Division of Cardiothoracic Surgery, Department of Surgery, University of Virginia, Charlottesville, VA, USA

<sup>y</sup> Department of Cardiovascular Surgery, Hospital Clinic de Barcelona, University of Barcelona, Barcelona, Spain

<sup>z</sup> Department of Diagnostic and Interventional Radiology, University Hospital Freiburg, Freiburg, Germany

<sup>aa</sup> Department of Cardiac Surgery, University Hospital Bern, Inselspital, University of Bern, Bern, Switzerland

<sup>ab</sup> Department of Cardiac Thoracic and Vascular Diseases, Fondazione IRCCS Cà Granda Ospedale Maggiore Policlinico, Milan, Italy

<sup>ac</sup> Department of Thoracic and Cardiovascular Surgery, West German Heart and Vascular Center, University Medicine Essen, Essen, Germany

\*Corresponding authors. Albert Ludwigs University Freiburg–Faculty of Medicine, University Heart Center Freiburg–Bad Krozingen, Südring 15, 79189 Bad Krozingen, Germany. Tel: +49 7633 2600; E-mail: martin.czerny@universitaets-herzzentrum.de (M. Czerny); Department of Cardiovascular Surgery, Clinic Floridsdorf, Brünnerstrasse 68, 1210 Vienna, Austria. Tel: +43 1 27700 4308; E-mail: martin.grabenwoeger@gesundheitsverbund.at (M. Grabenwöger).

**EACTS/STS Committee Reviewers:** Matthias Siepe<sup>a</sup>, Anthony L. Estrera<sup>b</sup>, Joseph E. Bavaria<sup>c</sup>, Davide Pacini<sup>d</sup>, Yutaka Okita<sup>e</sup>, Arturo Evangelista<sup>f</sup>, Katherine B. Harrington<sup>g</sup>, Puja Kachroo<sup>h</sup>, G. Chad Hughes<sup>i</sup>

<sup>a</sup>EACTS Review Coordinator; Department of Cardiac Surgery, University Hospital Bern, Inselspital, University of Bern, Bern, Switzerland

<sup>b</sup>STS Review Coordinator; Department of Cardiothoracic and Vascular Surgery, McGovern Medical School at UTHealth Houston, Houston, TX, USA

<sup>c</sup>Department of Cardiovascular Surgery, Hospital of the University of Pennsylvania, Philadelphia, PA, USA

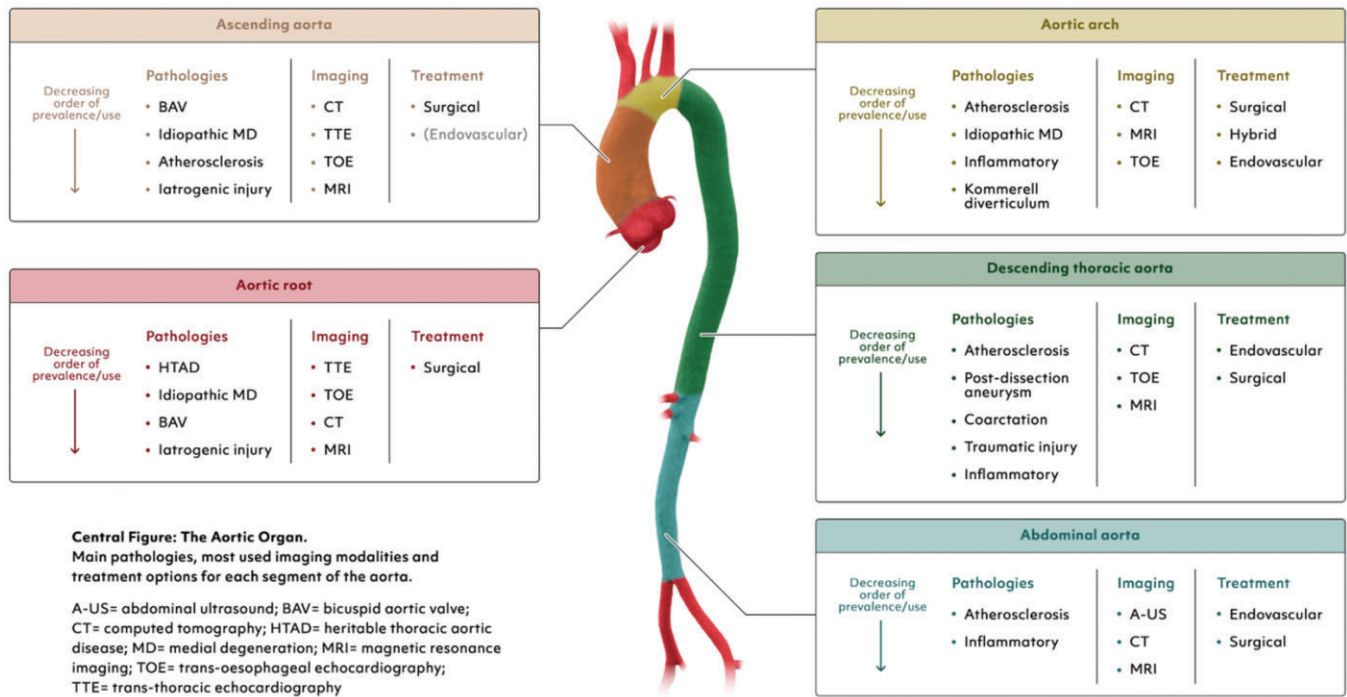
<sup>d</sup>Division of Cardiac Surgery, S. Orsola University Hospital, IRCCS Bologna, Bologna, Italy

<sup>e</sup>Cardio-Aortic Center, Takatsuki General Hospital, Osaka, Japan

<sup>†</sup>The first two authors contributed equally to this work.

This article has been co-published with permission in the *European Journal of Cardio-Thoracic Surgery*, and *The Annals of Thoracic Surgery*. All rights reserved.

© 2024 European Association for Cardio-Thoracic Surgery, and The Society of Thoracic Surgeons. The articles are identical except for minor stylistic and spelling differences in keeping with each journal's style. Either citation can be used when citing this article.



<sup>†</sup>Department of Cardiology, Hospital Universitari Vall d'Hebron, Barcelona, Spain; Vall d'Hebron Institut de Recerca, Barcelona, Spain; Biomedical Research Networking Center on Cardiovascular Diseases, Instituto de Salud Carlos III, Madrid, Spain; Departament of Medicine, Universitat Autònoma de Barcelona, Bellaterra, Spain; Instituto del Corazón, Quirónsalud-Teknon, Barcelona, Spain

<sup>§</sup>Department of Cardiothoracic Surgery, Baylor Scott and White The Heart Hospital—Plano, Plano, TX, USA

<sup>††</sup>Division of Cardiothoracic Surgery, Washington University School of Medicine, St Louis, MI, USA

<sup>‡</sup>Division of Cardiovascular and Thoracic Surgery, Department of Surgery, Duke University Medical Center, Duke University, Durham, NC, USA

**Disclaimer:** A clinical guideline aims to apply to all patients with a specific condition. However, there will inevitably be situations where its recommendations aren't suitable for a particular patient. While healthcare professionals and others are encouraged to consider these guidelines in their professional judgement, they don't override the responsibility of healthcare professionals to make decisions tailored to each patient's unique circumstances. Such decisions should be aligned with the latest official recommendations, guidelines from relevant public health authorities, and applicable rules and regulations. It is important that these decisions are made in collaboration with, and agreed upon by, the patient and/or their guardian or carer.

**TABLE OF CONTENTS**

PREAMBLE .....	4	Bicuspid aortic valve aortopathy .....	13
INTRODUCTION .....	5	REPORTING STANDARDS AND QUALITY INDICATORS .....	14
METHODOLOGY .....	5	Reporting standards .....	14
Organization of the writing committee .....	5	Quality indicators .....	15
Literature review .....	5	AORTIC TEAMS AND HEALTHCARE IMPLICATIONS .....	15
Class of recommendation and level of evidence .....	5	Impact of aortic disease on health care .....	16
PATHOPHYSIOLOGY AND NATURAL DISEASE COURSE—		Aortic teams, aortic centres and involved specialties .....	16
WHEN AND WHERE TO INTERVENE .....	6	Definition of aortic team .....	16
The aortic organ .....	6	Members of the aortic team .....	16
Development of the aorta and the mechanisms of aortic		Communication .....	16
disease .....	6	Teaching and training .....	17
Epidemiology .....	7	Aortic centres .....	17
NOMENCLATURE AND RISK STRATIFICATION .....	8	DIAGNOSTIC WORK-UP AND IMAGING .....	17
How to speak a common language .....	8	Diagnostic work-up for acute aortic syndromes .....	18
Acute aortic dissections .....	9	Clinical risk assessment .....	18
Extent of disease by Ishimaru zones .....	10	What to look for to reduce the risk of neurologic	
The GERman Registry for Acute Aortic Dissection type A		complications .....	18
score .....	10	Imaging—morphology and function .....	19
Do we still need De Bakey or should we remain with the		Computed tomography .....	19
type, entry, malperfusion classification and/or the		Magnetic resonance imaging .....	20
Ishimaru extent? .....	10	Transthoracic echocardiography .....	20
		Transoesophageal echocardiography .....	20
		Endovascular ultrasound .....	20

Ultrasound of the abdominal aorta . . . . .	20	Aortic arch . . . . .	48
Conventions for imaging-based assessment and measurements . . . . .	21	Aortic arch with and without affection of proximal and distal aortic segments . . . . .	49
Emerging fields in imaging . . . . .	22	Open surgical arch replacement . . . . .	49
Automated measurements of aortic dimensions . . . . .	22	Endovascular arch repair . . . . .	50
Length of the ascending aorta . . . . .	22	Descending aorta . . . . .	50
4-Dimensional magnetic resonance imaging . . . . .	22	Thoraco-abdominal aorta . . . . .	52
Extended reality in the context of vascular surgery . . . . .	23	Cannulation and extracorporeal circulation . . . . .	52
Photon-counting computed tomography . . . . .	23	Specifics in patients with parietal thrombi . . . . .	52
ACUTE AORTIC DISEASES—NATURAL COURSE OF THE DISEASE AND WHEN TO INTERVENE . . . . .	23	Conceptual considerations . . . . .	52
Acute aortic syndromes . . . . .	23	Clamping strategies . . . . .	52
Type A aortic dissection . . . . .	24	Specifics in thoraco-abdominal aortic aneurysm repair without extracorporeal circulation . . . . .	53
Preoperative evaluation . . . . .	24	Fenestrated endovascular aneurysm repair . . . . .	53
Surgical management . . . . .	25	The principle of branched or fenestrated endovascular aneurysm repair . . . . .	53
Non-A non-B aortic dissection . . . . .	25	Design and anatomical preferences for branched and fenestrated endovascular repair . . . . .	53
Type B aortic dissections . . . . .	27	Results of branched/fenestrated endovascular aortic repair . . . . .	55
Intramural haematoma . . . . .	28	Infrarenal . . . . .	56
Type A intramural haematoma . . . . .	28	Abdominal aortic aneurysm . . . . .	56
Type B intramural haematoma . . . . .	29	Management of infrarenal abdominal aortic aneurysm (infrarenal neck length > 10mm) . . . . .	56
Penetrating atherosclerotic ulcer . . . . .	29	Open surgery . . . . .	56
Blunt traumatic aortic injury . . . . .	31	Endovascular repair . . . . .	56
CHRONIC DILATATIVE AORTIC DISEASE . . . . .	32	Open surgery versus endovascular repair . . . . .	56
Root and ascending aorta . . . . .	32	Management of short-neck (infrarenal neck length 5–10 mm) and juxtarenal AAA (infrarenal neck length <5 mm). . . . .	57
Maximum diameter and maximum length . . . . .	34	Open surgery . . . . .	57
Aortic arch . . . . .	35	Endovascular repair . . . . .	57
Chronic aortic dissection . . . . .	35	Management of ruptured abdominal aorta aneurysms . . . . .	57
Heritable thoracic aortic disease . . . . .	36	Management of mycotic abdominal aorta aneurysms . . . . .	57
Non-syndromic heritable thoracic aortic disease . . . . .	37	Management of saccular abdominal aorta aneurysms . . . . .	57
Aortic aneurysm in adults with congenital heart disease . . . . .	37	Management of abdominal aortic dissection . . . . .	57
Difference between genotype and phenotype . . . . .	38	First branch vessels . . . . .	57
Descending aorta . . . . .	38	Endoleaks . . . . .	58
Thoraco-abdominal . . . . .	38	RARE CONDITIONS . . . . .	59
Abdominal aorta . . . . .	40	Graft Infections . . . . .	59
Chronic infrarenal obliterative arteriopathy . . . . .	40	Definitions and diagnostic criteria . . . . .	60
HOW TO MONITOR END-ORGAN FUNCTION AND HOW TO AVOID END-ORGAN INJURY . . . . .	41	General treatment . . . . .	60
Perfusion and cannulation . . . . .	42	Aortic surgical options . . . . .	61
Temperature management in aortic arch surgery . . . . .	43	Anatomical repair: in situ reconstruction . . . . .	61
Problem definition . . . . .	43	Extra-anatomic reconstruction . . . . .	61
Definitions of profound, deep, moderate and mild hypothermia . . . . .	43	Management of patients with aortoenteric or aortobronchial fistula . . . . .	61
Deep hypothermia versus moderate hypothermia . . . . .	43	Adjunct strategies . . . . .	61
Organ protection—heart . . . . .	44	Kommerell diverticulum . . . . .	62
Organ protection—lungs . . . . .	44	Diagnosis and follow-up . . . . .	62
General considerations . . . . .	44	Indication for surgery . . . . .	63
Organ protection—brain . . . . .	44	Operative strategy . . . . .	63
Organ protection—spinal cord . . . . .	45	Coarctation of the aorta . . . . .	64
Organ protection—viscerals and renals . . . . .	45	Burden of disease . . . . .	64
Visceral arteries . . . . .	45	Diagnosis . . . . .	64
Visceral protection during aortic arch surgery . . . . .	45	Treatment . . . . .	64
Visceral protection during thoraco-abdominal aortic surgery . . . . .	46	Endovascular intervention . . . . .	65
Renal arteries . . . . .	46	Open surgery . . . . .	65
Extremities . . . . .	47		
Monitoring lower limb function . . . . .	47		
Avoiding end-organ injury . . . . .	47		
THERAPEUTIC OPTIONS . . . . .	47		
Aortic root . . . . .	47		
Ascending aorta with or without proximal arch . . . . .	48		

Inflammatory disease of the aorta .....	65
Takayasu arteritis .....	65
Giant cell arteritis .....	66
Infectious aortitis .....	66
AORTIC DISEASE IN WOMEN: PREGNANCY AND POST PARTUM .....	67
Aortic disease in women .....	67
Pregnancy .....	68
Assisted delivery in pregnant patients with a risk of aortic dissection .....	68
Surgery before pregnancy in women with aortic conditions or hereditary connective tissue disorders .....	68
Aortic dissection and aortic surgery in pregnancy .....	68
RADIATION PROTECTION .....	69
INTENSIVE CARE UNIT POSTOPERATIVE MANAGEMENT OF PATIENTS UNDERGOING AORTIC SURGERY .....	69
Basic postoperative monitoring .....	70
Clinical assessment on arrival and reassessment protocol ...	70
Detection of clinical and subclinical malperfusion .....	70
Coagulation management, thromboelastography and transfusion .....	70
Special consideration for certain aortic procedures .....	71
Aortic arch replacement .....	71
Endovascular and open repair of the descending aorta ...	71
LIVING WITH AORTIC DISEASE .....	72
Exercise and sports .....	73
Returning to work .....	73
Rehabilitation .....	73
Surveillance and follow-up .....	73
FUTURE DIRECTIONS AND GAPS IN KNOWLEDGE .....	74
KEY MESSAGES .....	74
ACKNOWLEDGEMENTS .....	74
FUNDING .....	75
REFERENCES .....	75

#### ABBREVIATIONS AND ACRONYMS

<sup>18</sup> F-FDG	<sup>18</sup> F-fluorodeoxyglucose
3D	3-dimensional
4D flow MR	4-dimensional magnetic resonance
AAA	Abdominal aorta aneurysms
AAE	Acute aortic event
AAS	Acute aortic syndrome
AC	Aortic centre
AD	Aortic disease
AKI	Acute kidney injury
AR	Augmented reality
ATAAD	Acute type A aortic dissection
BAV	Bicuspid aortic valve
BEVAR	Branched endovascular repair
BMT	Best medical therapy
BSGs	Bridging stent grafts
BTAI	Blunt thoracic aortic injury
CI	Confidence interval
CIA	Common iliac artery
CN	Collateral network
CoA	Coarctation of the aorta
CPB	Cardiopulmonary bypass
CR	Cardiac rehabilitation
CSF	Cerebrospinal fluid

CT	Computed tomography
CTA	Computed tomography angiography
DHCA	Deep hypothermic circulatory arrest
dSINE	Distal stent graft-induced new entry
DSZ	Distal sealing zone
EACTS	The European Association for Cardio- Thoracic Surgery
ECC	Extracorporeal circulation
ECG	Electrocardiogram
ECM	Extracellular matrix
EIA	External iliac artery
EVAR	Endovascular aortic aneurysm repair
FET	Frozen elephant trunk
FEVAR	Fenestrated endovascular repair
GCA	Giant cell arteritis
GERAADA	German Registry of Acute Aortic Dissection Type A
HCA	Hypothermic circulatory arrest
HTAD	Heritable thoracic aortic disease
IA	Infectious aortitis
ICU	Intensive care unit
IIA	Internal iliac artery
ILT	Intraluminal thrombi
IMH	Intramural haematoma
ISB	Iliac side branch
KD	Kommerell's diverticulum
LoE	Level of evidence
LSA	Left subclavian artery
LV	Left ventricular
MEPs	Motor evoked potentials
MRI	Magnetic resonance imaging
NIRS	Near-infrared spectroscopy
OR	Odds ratio
PAU	Penetrating aortic ulcer
PET	Positron emission tomography
PETTICOAT	Provisional Extension To Induce Complete Attachment
POC	Point of care
PSZ	Proximal sealing zone
RCT	Randomized controlled trial
RTAD	Retrograde type A aortic dissection
SCI	Spinal cord injury
SSEPs	Somatosensory evoked potentials
STS	The Society of Thoracic Surgeons
SVS	Society for Vascular Surgery
TA	Takayasu arteritis
TAA	Thoracic aortic aneurysms
TAAA	Thoracoabdominal aortic aneurysm
TAAR	Total aortic arch replacement
TAR	Total arch replacement
TAV	Tricuspid aortic valve
TBAD	Type B aortic dissection
TEM	Type, entry, malperfusion
TEVAR	Thoracic endovascular aortic repair
TGFβ	Transforming growth factor-β
TOE	Transoesophageal echocardiography
TTE	Transthoracic echocardiography
VARC	Valve Academic Research Consortium
VUS	Variants of unknown significance
WSS	Wall shear stress

## PREAMBLE

Clinical practice guidelines summarize and assess all relevant evidence on a specific topic at the time of their creation, with the goal of assisting physicians in selecting the best management strategies for individual patients with a given condition. These guidelines take into consideration the impact on patient outcomes as well as the risk–benefit ratio of different diagnostic or therapeutic methods. Although these guidelines do not replace textbooks, they complement them and cover topics pertinent to contemporary clinical practice. They serve as a vital tool to aid physicians in making decisions in their daily practice. However, in essence, although these recommendations serve as a valuable resource to guide clinical practice, their application should always be tailored to the needs of the individual patient. Each patient's case is unique, presenting its own set of variables and circumstances. The guidelines are a tool designed to support, but not supersede, the decision-making process of physicians, based on their knowledge, expertise and understanding of their patients' individual situations. Furthermore, these guidelines should not be interpreted as legally binding documents. The legal responsibilities of healthcare professionals remain firmly grounded in applicable laws and regulations, and the guidelines do not alter these obligations.

The European Association for Cardio-Thoracic Surgery (EACTS) and The Society of Thoracic Surgeons (STS) selected a task force composed of professionals working in the field of this particular pathological condition. In an effort to maintain transparency and uphold integrity, all experts involved in the development and review of these guidelines provided declarations of interest, detailing any possible conflicts. Any changes to these declarations during the writing process had to be immediately reported to the EACTS and the STS. The EACTS and the STS provided all financial support for this task force, with no involvement from the healthcare industry.

Building upon this collaborative work, the clinical practice guidelines committees of the EACTS and the STS oversaw the creation, refinement, and approval of these new guidelines. A comprehensive review of the draft was carried out by an external panel of experts in the field. Their feedback informed the necessary revisions. After this thorough review and updating process, the final document received approval from all the experts on the task force and the governing bodies of the EACTS and the STS. This approval made it possible for the guidelines to be published simultaneously in the *European Journal of Cardio-Thoracic Surgery* and *The Annals of Thoracic Surgery*.

These guidelines, endorsed by both the EACTS and STS, represent the official viewpoint on this topic. They show a commitment to ongoing improvement, as regular updates will be made to keep the guidelines relevant and useful in the constantly evolving field of clinical practice.

## INTRODUCTION

'The obvious is imperceptible until it is perceived'

For centuries, the field of medicine has centred its attention on the function of end organs. The shift in perception that recognizes the 'aorta as an organ' in its own right is a recent development. This transformative perspective was first captured in a pioneering document about the 'vessel aorta' by Raimund Erbel for the European Society of Cardiology in 2001 [1]. This groundbreaking work led to an uptick, or 'hausse', sparking a series of guidelines and expert consensus documents.

The scientific community has recently realized the unique function of the 'organ aorta'. They have come to understand its critical importance, necessitating an update of our current knowledge on its physiology and pathophysiology. This change led to the creation of a comprehensive document detailing all known aspects of the natural history, diagnosis and treatment of both acute and chronic aortic pathologies.

This guideline addresses areas of interest both to specialists in aortic diseases (ADs) and to clinicians involved in diagnosis; endovascular, open surgical or hybrid treatment; and surveillance of patients with AD. Moreover, it provides a transparent basis for informed patients to comprehend the treatment offered by their specialists.

## METHODOLOGY

### Organization of the writing committee

To develop clinical practice guidelines with a primary focus on the management of AD, a multidisciplinary task force was established by the governing bodies of the European Association for Cardio-Thoracic Surgery (EACTS) and The Society of Thoracic Surgeons (STS). This selection and development adhered to processes outlined in the EACTS Methodology manual for clinical practice documents [2]. The societies involved endeavoured to ensure diversity in the composition of the writing group and adequate transparency in disclosing relationships with industry and other entities. Disclosure of any conflicts of interest was required from the task force members and the peer reviewers at the outset of the project and in the event of any change during the writing process.

### Literature review

Once the task force agreed upon the project's scope and developed the final table of contents, sections were assigned to task force members who had no relevant conflicts of interest. Chapter leaders, with assistance from their institutional biomedical specialists, carried out a scoping review of the literature. The appraisal of evidence prioritized the most recent data to ensure the relevance of clinical practice documents to contemporary clinical practice. However, essential publications were also included, irrespective of their publication date. This document focuses on adult cardiac surgery and primarily includes studies published in English. Due to resource constraints for an official translation, including entire articles and study protocols, the task force was unable to incorporate studies in other languages. The methodological quality of these studies was evaluated with a particular emphasis on study type and the risk of underlying biases. The review process favoured the randomized controlled trial (RCT), prospective studies and their meta-analyses over retrospective observational studies and case series. If required, the evidence was critically appraised for quality by task force members with the assistance of a clinical epidemiologist.

### Class of recommendation and level of evidence

All chapters were written, reviewed and edited in close collaboration among the task force members. Following this evaluation, a provisional set of recommendations was developed during a face-to-face meeting. Cost analyses were not considered or delivered due to the high variability in economic parameters and a lack of cost-effectiveness data in this setting.

**Table 1:** Levels of evidence

<b>Level of evidence A</b>	<b>Data derived from multiple randomized clinical trials or meta-analyses.</b>
<b>Level of evidence B</b>	<b>Data derived from a single randomized clinical trial or from large non-randomized studies.</b>
<b>Level of evidence C</b>	<b>The consensus of expert opinion and/or small studies, retrospective studies and registries.</b>

**Table 2:** Classes of recommendations

<b>Class of recommendations</b>	<b>Definition</b>	<b>Suggested wording</b>
<b>Class I</b>	<b>Evidence and/or general agreement that a given treatment or procedure is beneficial, useful and effective.</b>	<b>Is recommended/is indicated</b>
<b>Class II</b>	<b>Conflicting evidence and/or a divergence of opinion about the usefulness/efficacy of the given treatment or procedure.</b>	
<b>Class IIa</b>	<b>Weight of evidence/opinion is in favour of usefulness/efficacy.</b>	<b>Should be considered</b>
<b>Class IIb</b>	<b>Usefulness/efficacy is less well established by evidence/opinion.</b>	<b>May be considered</b>
<b>Class III</b>	<b>Evidence/general agreement that the given treatment/procedure is not useful/effective and may sometimes be harmful.</b>	<b>Is not recommended</b>

The level of evidence (LoE) and the class of recommendation were weighed and graded according to predefined scales, as outlined in the EACTS process development document (Tables 1 and 2) [2]. The class of recommendation denotes the strength of the recommendation by weighing the health risks and benefits associated with the specific intervention, whereas the LoE reflects the quality of the supporting evidence based on the quantity and consistency of data from clinical trials and other research studies. In accordance with EACTS policies for voting recommendations, each recommendation was voted on anonymously after the face-to-face meeting via an online voting platform. Although the consensus threshold was set at 75%, the average consensus for all recommendations was 96%. The draft document underwent internal validation and approval by all writing committee members before proceeding to external validation by anonymous reviewers chosen by the governing bodies and journal editors.

## **PATHOPHYSIOLOGY AND NATURAL DISEASE COURSE—WHEN AND WHERE TO INTERVENE**

### **The aortic organ**

**Recommendation Table 1: The aortic organ**

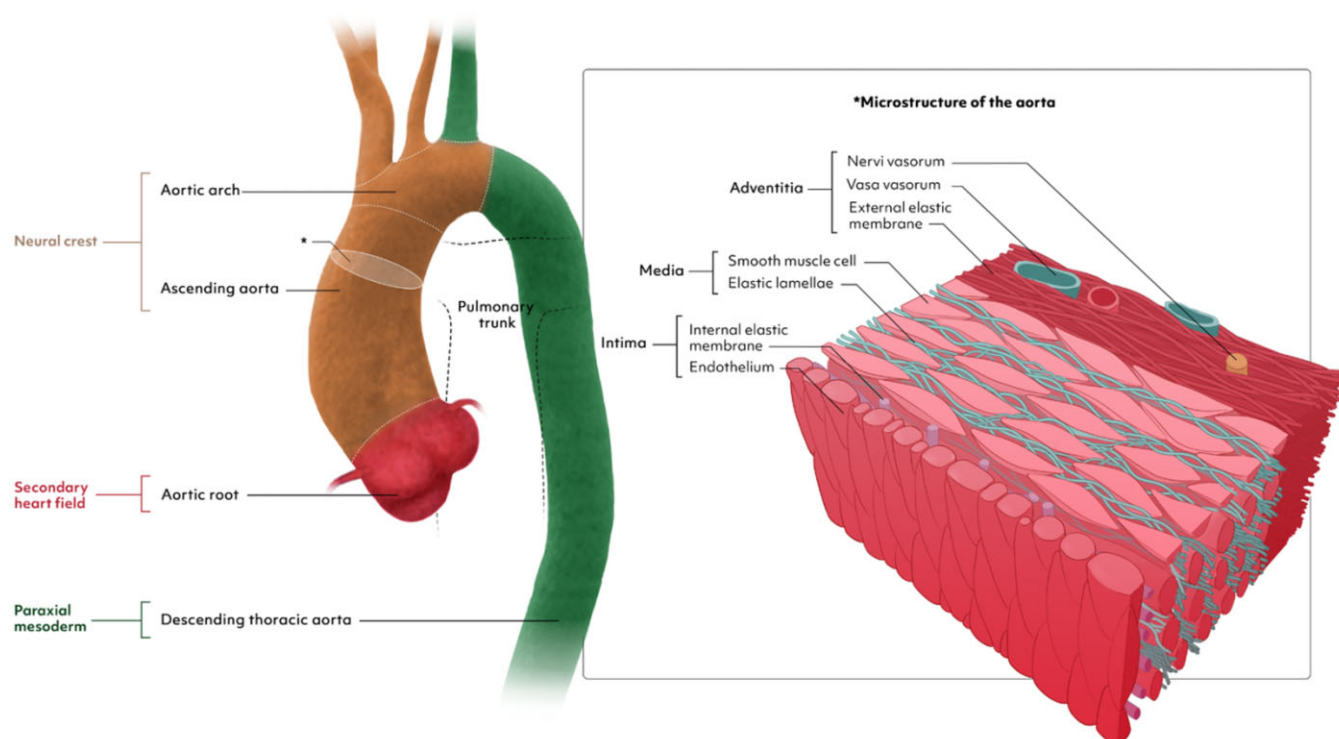
<b>Recommendation</b>	<b>Class<sup>a</sup></b>	<b>Level<sup>b</sup></b>	<b>Ref<sup>c</sup></b>
It is recommended to view, interpret and treat the aorta in the context of an organ, whereby diagnosis, treatment and surveillance should be approached with this perspective.	<b>I</b>	<b>C</b>	-

<sup>a</sup>Class of recommendation.

<sup>b</sup>Level of evidence.

<sup>c</sup>References.

There is no better description of the aortic organ than the universal definition of an organ being 'part of an organism which is typically self-contained and has a specific vital function'; in other words, a functional unity. Although our perception of the aorta in this context is new and might well be due to the historical perspective of specialties handling only segments and not the entire functional unity, the current viewpoint that this guideline aims to provide is a holistic one from the embryologic origin from proximal to distal (secondary heart field, neural crest and mesoderm), which forms the basis of our understanding of tissue texture; the development of the embryologic arches, which are fundamental



**Figure 1:** The origin and microstructure of the aorta.

to understanding arch anomalies as well as the quantity of elastic fibres that decrease from proximal to distal and that form the basis of our understanding of disease mechanisms and the effect of treatment modalities and their impact on adjacent organ systems.

### Development of the aorta and the mechanisms of aortic disease

The aorta exhibits a heterogeneous developmental origin. The aortic root derives from cells of the secondary heart field, and the ascending aorta and part of the aortic arch stem from the neural crest. The more distal part of the aorta is of mesenchymal origin [3]. The origin and microstructure of the aorta is illustrated in Fig. 1. Initially, a paired aorta is formed by the fusion of isolated vascular islands. The aortic sac develops by fusion of the 2 ventral aortae and the descending aorta, by fusion of the dorsal aortae. Six paired aortic arches develop consecutively and connect the aortic sac with the dorsal aorta. The arches develop and regress at different times, thereby forming the aortic arch, supra-aortic branches, the pulmonary artery and the ductus arteriosus. Most congenital anomalies of the great vessels are the result of either persistence of segments that normally regress or vice versa [4].

Vascular smooth muscle cells are the predominant cell population in aortic tissue and interact with the extracellular matrix (ECM) in maintaining aortic homeostasis. Different models of AD describe changes that lead to the loss of contractile function of smooth muscle cells and a phenotypic switch towards similar cells of different origins such as mesenchymal cells or myofibroblasts. Decreased expression of smooth muscle cell proteins and increased expression of inflammatory proteins such as matrix metalloproteinases have been described in the context of thoracic AD [5].

Fibrillin-1 is an important component of the ECM and plays a key role in transducing mechanical stress between the ECM and

vascular smooth muscle cells. Current data suggest that the interplay between vascular smooth muscle cells and mechanical stimuli in the ECM is a key factor in the development of AD [6]. Ageing as well as AD in general lead to loss of distensibility, which in turn is associated with an increase in glycosaminoglycans and extracellular collagens as well as a loss of elastin content [7].

Variants in genes associated with the transforming growth factor- $\beta$  (TGF $\beta$ ) signalling pathway have been implicated in aneurysm formation in the context of heritable connective tissue disorders, with Marfan syndrome and Loeys-Dietz syndrome being the most prominent ones. TGF $\beta$  is a ubiquitous cytokine in most mammalian cells that controls proliferation and cellular differentiation [8].

The administration of TGF $\beta$  antibodies prevented aneurysm formation in a mouse model of Marfan syndrome and therefore established a cause-effect relationship for the development of thoracic AD at the molecular level. Over the past decade, several TGF $\beta$ -associated vasculopathies have been identified and have turned the TGF $\beta$  signalling pathway into a promising target for therapeutic interventions [9].

### Epidemiology

The epidemiology of the thoracic aorta in the population is poorly studied because such studies would require adequate consecutive imaging [at least transthoracic echocardiography (TTE) or at best computed tomography (CT) scans or magnetic resonance angiography] of a large number of individuals in a specific geographic area. An aortic aneurysm is defined as 1.5-fold its normal vessel diameter for descending and abdominal aortic aneurysms and >45 mm for the aortic root and ascending aorta [10, 11]. Aortic dilation in the aortic root and ascending aorta is defined as diameters ranging 40–45 mm. In a population

study in Canada, the incidence of thoracic aortic aneurysms (TAA) increased between 2002 and 2014 from 3.5 to 7.6 per 100 000 persons [12]. In a prospective cohort study in Sweden, the incidence rate per 100 000 patient-years at risk was 15 for an aortic dissection, 27 for an abdominal aortic aneurysm and 9 for a TAA [13]. In a review of 11 studies, TAA incidence ranged from 5 to 10 per 100 000 person-years [14]. In a recent study, an increased aortic size of the ascending aorta (>36 mm) was found among 12% of participants in Iran, whereas the prevalence of an aneurysm (>45 mm) was 1.2% [15]. All these data need to be read with caution because the methodology for measuring the size of the aorta by ultrasound varies (outer-to-outer vs inner-to-inner or edge-to-edge methods). The results of a recent study suggest that the normal values of the aorta may be different in Africans, requiring ethnic-specific normal values [16].

Data on the epidemiology of acute aortic syndromes (AAS) are limited. In autopsy studies the prevalence of aortic dissection ranges from 0.2% to 0.8% [17], whereas in most population series the incidence of aortic dissection ranges from 0.61 to 7.2/100 000 people [18–27]. In one study in the USA performed during the 2010–2015 period, the incidences of AD, intramural haematoma (IMH) and penetrating aortic ulcer (PAU) were 4.4, 1.2 and 2.1 per 100 000 person-years, respectively [28]. However, these rates plausibly underestimate the actual incidence because many victims die undiagnosed or before arriving at the hospital with accurate diagnostic imaging. One study in Japan reports a much higher incidence (17.6 per 100 000), which is probably more accurate because the authors performed systematic CT scans on all out-of-hospital deceased persons without a clear cause of death [24]. The reported 30-day mortality varies from <11% to almost 75%, the latter rate reported in Japan using the post-mortem imaging approach [24]. In a recent analysis in Spain and Ontario, surgery rates increased and mortality rates decreased after diagnosis of AD during the past 2 decades [26, 29]. However, trends in mortality related to AD vary from one country to another and may be affected by the ability in each country to diagnose AD in a timely manner and determine accurately the causes of deaths in their populations [30].

Data on the epidemiology of the abdominal aorta aneurysm (AAA) are less scarce, not only because of the ease of diagnosis using abdominal echography but also because of several national population screening studies. Overall, the prevalence of AAA is decreasing: Whereas population studies and screening trials in the late 20th century reported a prevalence around 4–5% in men [31], more recent studies report lower rates, often used to counter-argue national screening plans. In a vascular screening trial in Denmark, 3.3% of participants had AAA [32]. In the Swedish nationwide AAA screening programme proposed to men >65 years of age, the prevalence of AAA was 1.5% [33]. Over 25 years of a screening programme in Gloucestershire, the prevalence of AAA decreased from 5% to 1.3% [34], equalling the rates reported among the first 700 000 men screened (2009–2013) in the UK national screening programme [35]. A reduction in smoking rates and improved management of cardiovascular risk factors may plausibly explain this evolution. As a consequence, decreases in hospitalization and mortality related to AAA are reported in several countries [36, 37].

## NOMENCLATURE AND RISK STRATIFICATION

**Recommendation Table 2: Nomenclature and risk stratification**

Recommendations	Class <sup>a</sup>	Level <sup>b</sup>	Ref <sup>c</sup>
In patients with aortic dissection, Ishimaru zones are recommended for use as a reporting standard of disease extent.	I	C	-
The use of the TEM <sup>d</sup> classification should be considered in any acute aortic syndrome to determine the type of disease and an initial treatment strategy.	Ila	C	-
The use of the GERAADA <sup>e</sup> score should be considered in patients with acute type A aortic dissection undergoing surgery to determine 30-day mortality.	Ila	C	-

<sup>a</sup>Class of recommendation.

<sup>b</sup>Level of evidence.

<sup>c</sup>References.

<sup>d</sup>Type, entry, malperfusion [38].

<sup>e</sup>German Registry for Acute Aortic Dissection Type A [39].

GERAADA: German Registry for Acute Aortic Dissection Type A; TEM: type, entry, malperfusion.

## How to speak a common language

The need to use a common language in aortic medicine is growing, the main reasons being: (i) aortic medicine is now a subspecialty in which the aorta is viewed more and more as a complex organ and not simply as a large vessel distributing blood; (ii) patients with AD are followed life-long, with many requiring several aortic interventions over time, and a common language facilitates long-term follow-up and reporting of results; and finally (iii) aortic medicine is multidisciplinary, so a common language is essential for effective communication among a vast array of specialties including cardio-vascular surgery, cardiology, radiology, anaesthesiology, rheumatology, genetics and endocrinology.

Several groups of experts have tried to harmonize language in aortic medicine, initially with best practice guidelines for reporting treatment results after thoracic endovascular aortic repair (TEVAR) [40]. More recently, the *European Journal of Cardio-Thoracic Surgery* editors published STORAGE guidelines, defining standards of reporting in both open and endovascular aortic surgery [41]. They provided definitions of aortic pathologies and instructions on how to analyse and report results of imaging studies including the most fundamental measurements such as aortic diameter. Furthermore, STORAGE guidelines include information on how to report on open and endovascular procedures, including treatment techniques and their outcome. Several other documents contain recommendations on reporting standards, including one for acute type B aortic dissection (TBAD) published by the Society of Vascular Surgeons and the STS [42] and another on endovascular repair of an aortic aneurysm involving the renal-mesenteric arteries [43].

*Categorization of tears in aortic dissection.* The writing committee suggests that the terms multiple entries and re-entries be removed from clinical use and be replaced by the wording most

proximal tear, communications between lumina and most distal tear in addition to the term primary entry tear. This proposed wording should help create a better understanding of the pathophysiology as well as help standardize communication among physicians describing the pathological categories.

**Aortic arch replacement of various extents.** When referring to aortic arch treatment, qualitative and semi-quantitative statements should be avoided. Due to the rising number of patients receiving open and endovascular therapy, it seems reasonable to refer to the treatment-based classification using the terminology 'zones 0–4' when describing surgery on the aortic arch. Again, 'distal arch aneurysm' covers a wide range of anatomical variations. Replacing the arch using the frozen elephant trunk (FET) with an anastomosis proximal to the left carotid artery and selective reimplantation using separate grafts is not adequately covered in the current definitions.

One notable exception is the term 'hemiarch', which has been widely used for decades even if it also covers a wide range of surgical strategies. The writing committee refers to hemiarch as replacing the ascending aorta and performing an open distal anastomosis to resecting the entire concavity of the arch down to the proximal descending thoracic aorta. For the purpose of this guideline, total aortic arch replacement (TAR) is defined as replacing the entire aortic arch—or excluding it from the circulation as is the case when using the FET technique (TAR with an

antegrade stent graft implant in the distal aortic arch and proximal descending aorta using a single hybrid prothesis)—from the innominate artery to a point beyond the left subclavian artery (LSA). Reimplantation or revascularization of the supra-aortic branches can be performed in different ways, and the method used is not part of the definition of TAR. To facilitate communication and to harmonize the standards of reporting, defining TAR as replacing (or excluding from circulation) aortic zones 0–2 (or beyond) seems reasonable. All other procedures on the arch should be named partial arch replacement.

**Residual dissection after type A repair.** The chronic dissected state of aortic segments distal to the proximal repair is defined as 'residual dissection after type A repair'. The writing committee uses the term 'parallel grafts' to refer to chimneys, snorkels and periscopes. A 'hybrid approach' is the combination of an open vascular surgical technique and an endovascular procedure performed simultaneously or on a sequential basis to treat AD.

### Acute aortic dissections

The location of the primary entry tear and the extent of the aortic wall dissection (e.g. the separation process) determine both the pathoanatomical classification and essentially the treatment strategy [44] (Fig. 2). A proximal or a type A aortic dissection involves the

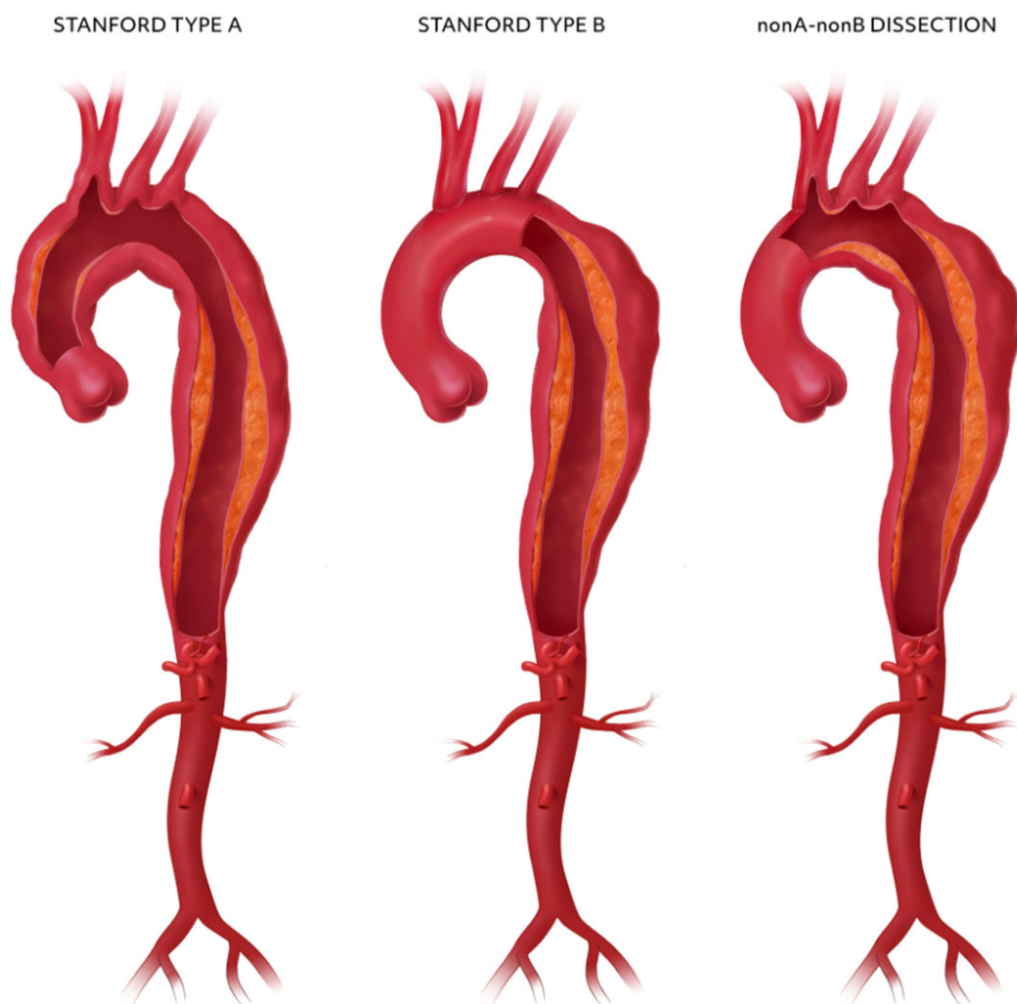


Figure 2: Type classification of aortic dissections.

ascending segment of the aorta and requires open surgery in almost every patient, whereas a TBAD excludes the ascending aorta and could be managed medically in combination with endovascular interventions in many patients [45–47]. Improving diagnostics and imaging quality recently identified a subgroup of non-A non-B dissections with a separation of media layers encompassing the aortic arch but sparing the ascending aorta [48], with an entry tear often found in the region between the brachiocephalic and left subclavian arteries. These characteristics should be clearly separated from an earlier version of a non-A non-B dissection defined by an entry tear in the arch with retrograde extension, which is nothing but an overlap and subset of type A dissection [49].

Whereas a proximal or a type A aortic dissection constitutes 59–67% of all AAS cases, a type B dissection accounts for around 31% and a non-A non-B dissection for 3–10%, with a minority showing an entry tear located not in the arch region but rather in the descending aorta with retrograde propagation of the false lumen [38, 48, 50].

With the recent interest in non-A non-B dissection, the view on best treatment is blurred, with options ranging from open surgical resection of the arch [with or without an elephant trunk] and hybrid debranching and/or endovascular intervention to medical management only. Aortic dissection is further subclassified based on symptom/dissection onset: (i) acute (up to 14 days after dissection onset); (ii) subacute (15–90 days after dissection onset) and (iii) chronic (91 days after dissection onset and later).

### Extent of disease by Ishimaru zones

The aorta is divided into the following zones: the aortic root, the ascending aorta, the aortic arch, the descending thoracic aorta and the abdominal aorta. Ishimaru zones (Fig. 3) have enabled a more detailed classification of aortic segments by dividing the aorta into 12 zones (0–11) [51]. The use of Ishimaru zones is recommended when reporting on both open and endovascular aortic treatment extension, AD extension (such as aneurysm or dissection) and location of communications between aortic lumens in patients with an aortic dissection.

We recommend referring to the types I, II and III aortic arch configurations when reporting on aortic arch anatomy (Fig. 4). In a type I aortic arch, all supra-aortic branch origins are at the same horizontal level. In type II, the innominate artery originates between the horizontal planes of the outer and inner curvatures of the aortic arch. If the innominate artery originates below the horizontal plane of the inner curvature of the aortic arch, it is a type III aortic arch [41]. In particular, a type III aortic arch generates a unique abnormal helical flow and may therefore account for its high prevalence in patients with TBAD [52].

### The GERman Registry for Acute Aortic Dissection type A score

Acute type A aortic dissection (ATAAD) is a critical surgical emergency that necessitates immediate intervention in most cases. Despite significant advancements in surgical techniques and perioperative management, the repair of type A dissection remains associated with substantial mortality and morbidity, with reported mortality rates exceeding 20%, depending on the presenting characteristics and operator experience [53–56]. The survival of patients after type A dissection repair relies heavily on

their presenting haemodynamic status and the presence of end-organ ischaemia [57, 58].

Although the majority of patients with acute type A dissection will benefit from immediate surgery, the development of dissection-specific risk models that enable rapid risk assessment at the bedside has provided clinicians with additional tools to optimize care. Such models may pave the way for advanced decision-making in situations where the surgical risk is exceptionally high, potentially favouring endovascular therapies to address malperfusion before proceeding with open aortic repair or even performing an endovascular primary repair in the future [59, 60]. Risk stratification also provides a simple and reproducible method for risk-adjusted outcome assessment for quality improvement, performance measurement or evaluations of the comparative effectiveness of different techniques. Commonly used bedside tools for cardiac surgery risk assessment, such as the STS score and the EuroSCORE II, are not calibrated to be used to estimate risk in patients with ATAAD [61, 62].

Two risk assessment methods are currently used in type A dissection: the German Registry for Acute Aortic Dissection Type A (GERAADA) score and the Penn classification [39, 63]. The GERAADA score is calculated using a Web-based application and stratifies patients into low-risk (<15%), intermediate-risk (15–30%) and high-risk (>30%) mortality groups ([https://www.dgthg.de/de/GERAADA\\_Score](https://www.dgthg.de/de/GERAADA_Score)). The inputs in the GERAADA score include sex, age, resuscitation before surgery, previous cardiac surgery, intubation, catecholamine support at referral, grade of aortic regurgitation, organ malperfusion, hemiparesis, extension of aortic dissection and location of primary tear (Fig. 5). The GERADA score can effectively predict the 30-day mortality rate and has been validated in various cohorts, although it may overestimate overall risk in some populations [64, 65].

The Penn classification is a very parsimonious categorization of patients based on the total body burden of ischaemia, with classifications ranging from none (Penn class A) to local or regional ischaemia (Penn class B), global ischaemia or shock (Penn class C) or combined local and global ischaemia (Penn class BC) [63]. This system has been validated and emphasizes total physiologic ischaemic burden and considers haemodynamic collapse in the absence of localized ischaemia. A recent publication from the home institution of the Penn class showed a baseline mortality rate of 5% in Penn class A patients [66]. Penn class B patients had an increased odds ratio (OR) for mortality of 2.4 [95% confidence interval (CI) 1.4–4.3], Penn class C patients had an increased OR of 3.4 (95% CI 1.9–6.0) and finally Penn class BC patients had a markedly increased OR of 13.1 (95% CI 7.9–22.2) [66]. The Penn classification has remained internally consistent over time and has been verified as a strong predictor of perioperative mortality at several institutions [67, 68].

### Do we still need De Bakey or should we remain with the type, entry, malperfusion classification and/or the Ishimaru extent?

The Stanford and DeBakey systems have been used to classify aortic dissection for the last 7 decades. Several new dissection classification systems have been proposed, including one suggested by Roux and Guilmet [69], DISSECT (Duration, Intimal tear, Size, Segmental Extent, Clinical complications, Thrombosis) [70] and the PENN classification [71]. Due to their complexity, they have not been widely adopted in clinical practice.

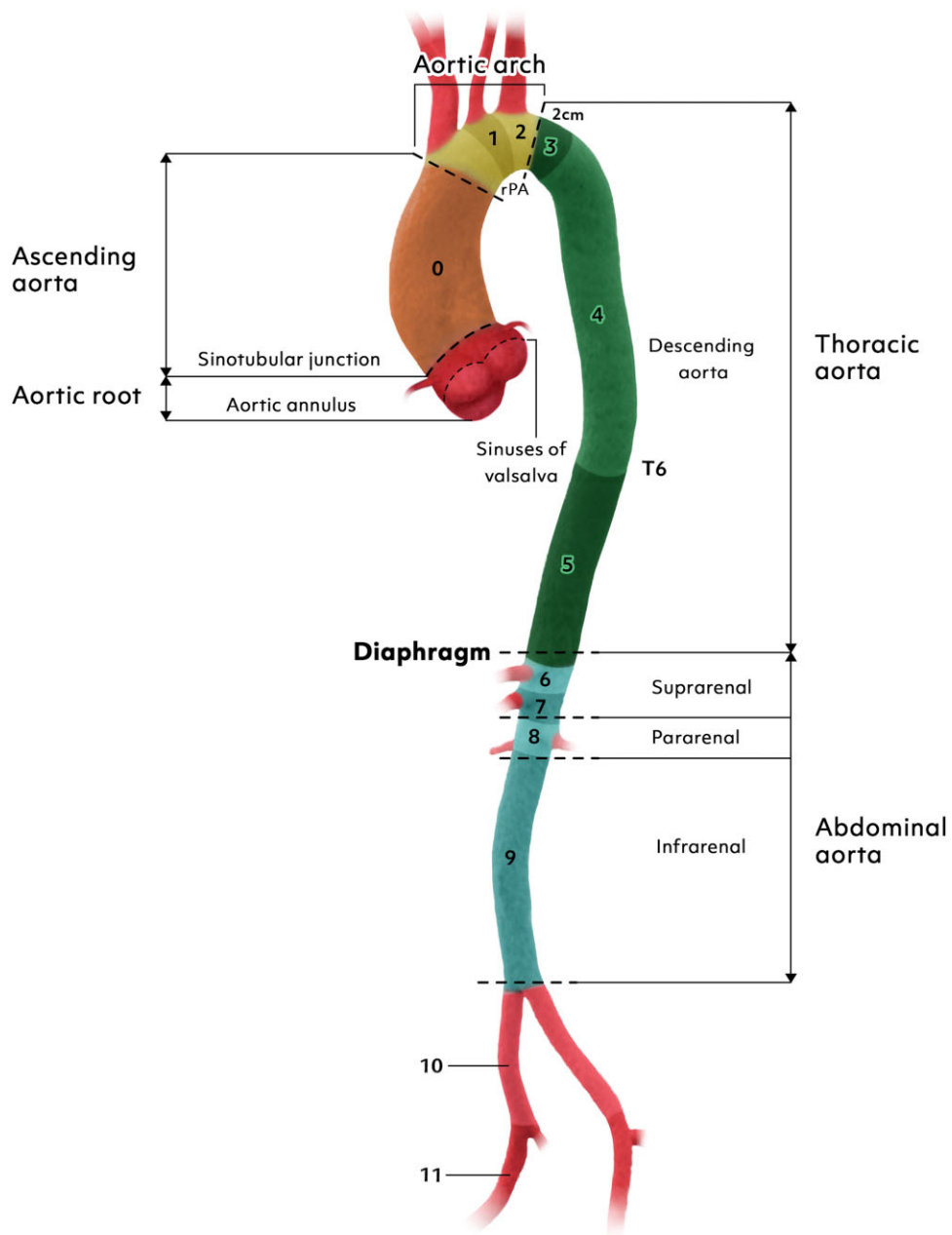


Figure 3: Aortic segments based on Ishimaru zones.

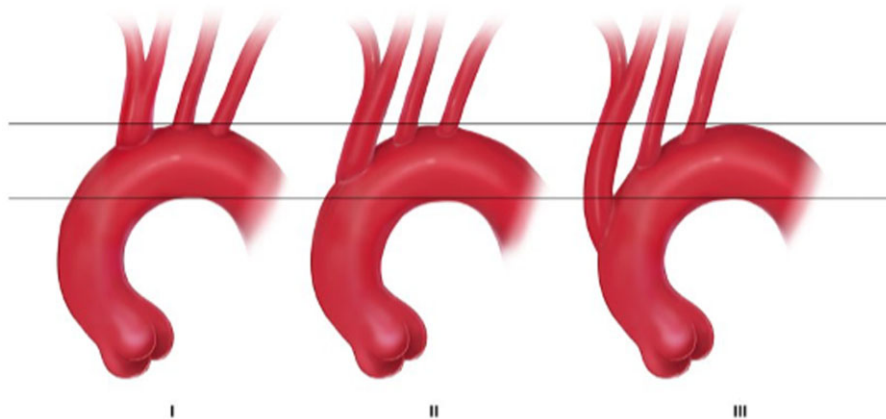


Figure 4: Classification of aortic arch types.

## Predicted 30-day mortality in patients undergoing surgery for acute type A aortic dissection - the GERAADA score

**Age:**

**Sex:**

**Resuscitation before surgery:**

**Previous cardiac surgery:**

**Intubation/ventilation at referral:**

**Catecholamines at referral:**

**Aortic valve regurgitation:**

**Preoperative organ malperfusion:**

- no
- coronary malperfusion
- visceral malperfusion
- peripheral malperfusion
- unknown or other

**Preoperative hemiparesis:**

**Extension of dissection:**

- aortic arch
- supraaortic vessels
- descending or further downstream
- unknown or other

**Location of primary entry tear within aortic arch:**

**Figure 5:** Web interface for GERAADA score calculation. GERAADA: German Registry for Acute Aortic Dissection Type A. Reproduced from Czerny *et al.* [39] with permission from Oxford University Press.

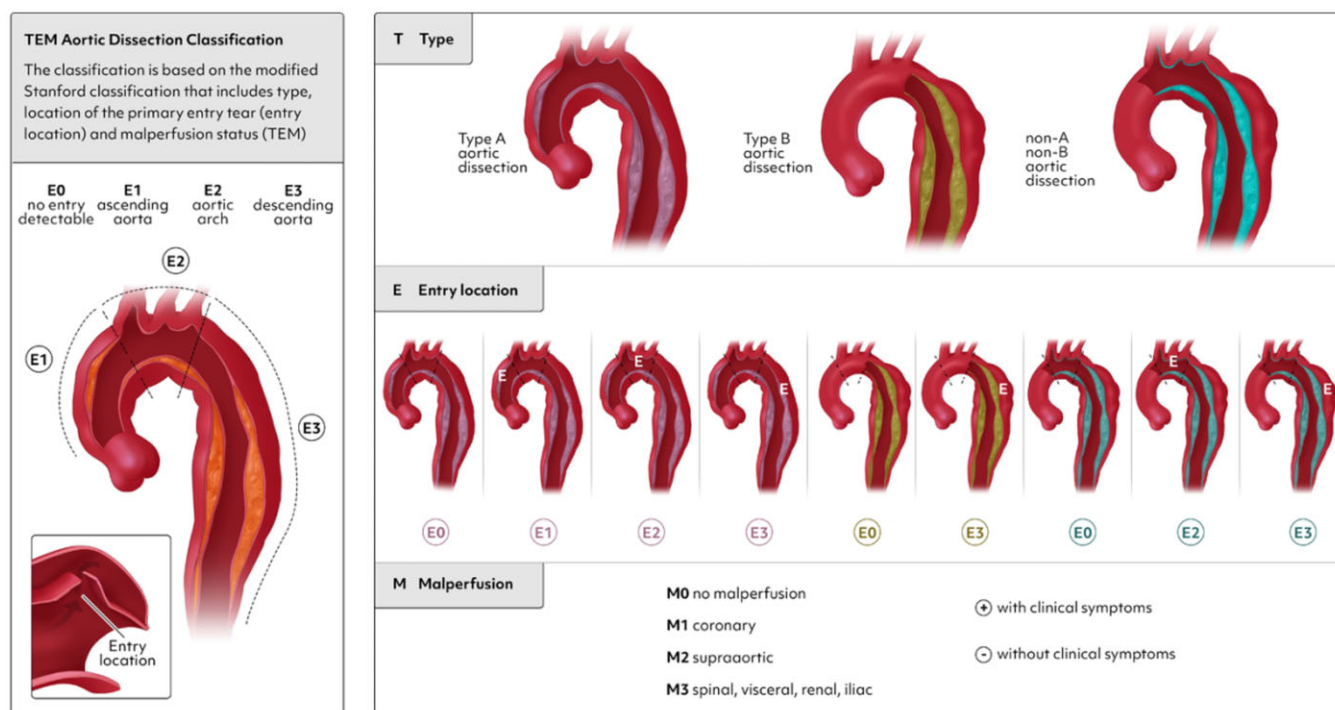


Figure 6: Type, entry, malperfusion classification for acute aortic dissection. TEM: type, entry, malperfusion.

The Society for Vascular Surgery (SVS) together with the STS recently proposed a new classification that includes the Stanford nomenclature [42]. In this new SVS/STS classification, aortic dissection is defined not by the dissection extension but by the entry location. If a patient has an entry in the aortic arch or the descending aorta and the dissection extends down to the aortic valve, it is an aortic dissection type B. Aortic dissections type A are only those dissections with entry in the ascending aorta and proximal arch.

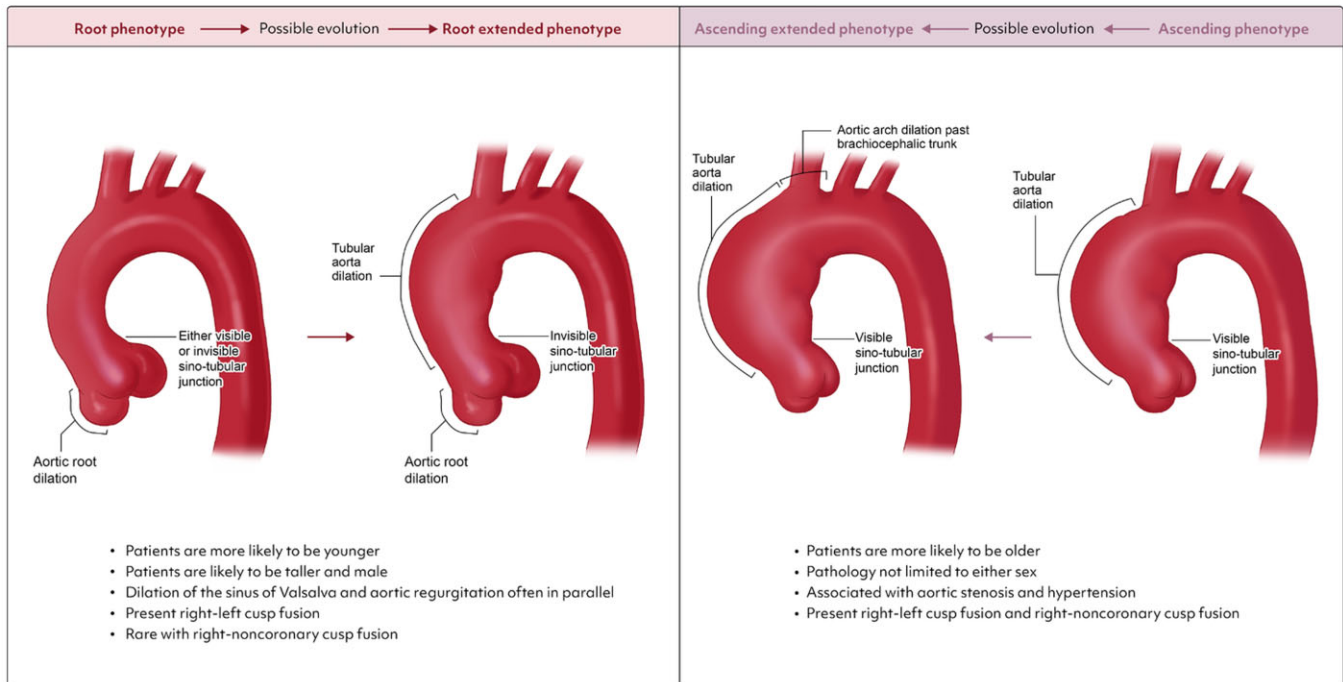
The European update of the Stanford classification—the type/entry/malperfusion (TEM) classification—has been recently proposed [38] (Fig. 6). In the TEM classification dissection, type (T) is defined by dissection extension as proposed by the Stanford classification and not by entry location. TEM provides for the first time a separate term for dissections involving the aortic arch but not the ascending aorta: non-A non-B aortic dissection [38, 50, 72]. It gives information on the location (E) of the primary entry tear and malperfusion status (M). The entry location ‘0’ is given if the primary entry tear is not visible; ‘1’ if it is in the ascending aorta; ‘2’ if in the arch; and ‘3’ if in the descending aorta (E0, E1, E2 and E3). Malperfusion status is noted by a ‘0’ if malperfusion is absent; ‘1’ if coronary arteries are affected; ‘2’ if supra-aortic vessels are dissected; and ‘3’ if the visceral/renal and/or a lower extremity are affected (M0, M1, M2 and M3). A plus (+) is added if malperfusion is clinically present and a minus (-) is added if it is a radiological finding.

The DeBakey classification and the binary Stanford classification do not allow the precise classification of different dissection subgroups, which is important given the new evidence on treatment outcomes in different aortic dissection subtypes involving different malperfusion status and different dissection anatomies. Therefore, the TEM classification or the descriptive approach defining the dissection anatomy according to Ishimaru zones (for example, aortic dissection with entry in zone 0 extending down to zone 6) is recommended to be used in clinical practice and in the literature.

## Bicuspid aortic valve aortopathy

The aortopathy associated with the bicuspid aortic valve (BAV) has in the past been the object of intense scientific debate, especially concerning its pathogenesis, whether it is genetically determined or haemodynamically driven. The lack of a definite answer to this question has yielded discrepancies in surgical attitudes and even in official guidelines [73–76]. Only when the clinical and phenotypic heterogeneity of this disease began to be highlighted and systematically addressed by research studies could the hypothesis that the 2 mechanisms could coexist, with different respective weights of different phenotypical forms, lead to new interest in classifying BAV aortopathy [73–77]. However, initially different systems were suggested based on different criteria, possibly causing general confusion [77–79]. Most recently, a large group of international experts developed a consensus statement on nomenclature and classification of BAV and the associated aortopathy: The valve should be described as ‘fused’, ‘2-sinus’ or ‘partial-fusion’ type, whereas the aortopathy has been classified as ‘root phenotype’ (15–20% cases, dilatation prevailing at the level of the sinuses), ‘ascending phenotype’ (70–75%, dilatation prevailing at the tubular tract) or ‘extended phenotypes’ (5–10%, either root dilatation with significant extension into the tubular tract or tubular dilatation involving also the proximal arch) [80]. This system was a modified version of the classification first proposed by Della Corte *et al.* [77], who inferred that the different phenotypes, each showing peculiar associations with clinical features (Fig. 7), might represent forms with different degrees of severity in prognostic terms [81]. Later, the root phenotype has shown an association with the faster growth of the ascending diameter [82], the higher prevalence of aortic dilatation in relatives [83], the greater risk of acute aortic events (AAEs) in post-aortic valve replacement follow-up [84], the higher propensity to dissect [85–87] and potentially aortopathy-related gene variants [88]. Patients with clinical characteristics of

## Bicuspid aortic valve aortopathy (BAVA) phenotypes



**Figure 7:** Phenotypes of root and ascending aortic morphology in bicuspid aortic valve aortopathy. RL: right-left coronary; RN: right-noncoronary.

the root phenotype (or the root extended) should undergo stricter surveillance and an earlier operation.

Few studies have selectively addressed the ascending phenotype: In that setting, aortic wall morphometric and molecular changes are localized in the areas with maximal flow-related wall shear stress (WSS) (usually at the outer curvature of the tubular tract) [89, 90], and growth rates after aortic valve replacement are extremely slow [91]. Typical features that are associated with an extended phenotype include an ascending dilatation with stenotic right-noncoronary leaflet fusion type BAV [77, 80, 92] ('ascending extended' into the arch); a root dilatation with regurgitant BAV and effacement of the sinotubular junction [77, 82] (progression to 'root extended' to the ascending aorta).

**Classification of bicuspid aortic valve aortopathy:** Two main phenotypes are depicted, with the respective typical associations with the patient's characteristics. The 2 pathogenetic mechanisms of aortopathy development (genetic variants, haemodynamic derangements) probably coexist in both phenotypes, but their respective contributions might differ. The extended phenotypes can be the evolution of either a root or an ascending phenotype as the disease progresses over time.

## REPORTING STANDARDS AND QUALITY INDICATORS

### Reporting standards

Reporting standards for the treatment of TBAD were formulated jointly by the SVS and the STS in response to the evolving understanding of the anatomy and physiology of TBAD and the growing body of literature on endovascular intervention for TBAD across different specialties that disparately reported on aetiology/risk factors, diagnoses, interventions and outcomes, preventing

comparisons of data and study results [42]. The document combines clinical and technical end-points and suggested a novel classification system to describe TBAD, borrowing from the Stanford classification but adding location of intimal tear and proximal and distal extent of the dissection, because these anatomical features helped define arch involvement with more granularity and impacted open and endovascular options for treatment. These issues have become even more important in the setting of devices that combine surgical grafts with endovascular stents to facilitate open arch replacement with the FET and a strategy that focuses on treatment of both the intimal tear and the re-entry tears in the arch and proximal descending thoracic aorta. It also harmonized into consensus terms such as acute, chronic, complicated, high risk and types of malperfusion.

During open surgery, reporting of cardiopulmonary bypass (CPB), hypothermic circulatory arrest (HCA) and cerebral perfusion times is essential. In order to provide uniformity in reporting these substantial factors during the operation, the writing committee suggests the following differentiation in the reporting of (i) CPB time, (ii) selective antegrade cerebral perfusion time (right/left/double/triple), (iii) aortic cross-clamp time, (iv) lower body HCA time, (v) HCA, and (vi) myocardial perfusion or arrest time. Moreover, the writing committee recommends that reporting the neuromonitoring strategies such as near-infrared spectroscopy (NIRS) or measurement of cerebral perfusion pressure if applied.

The 30-day mortality and in-hospital mortality outcomes are considered early dissection-related deaths. Neurologic outcomes, including stroke and spinal cord injury (SCI), are characterized in the STS/SVS document by the modified Rankin scale and modified Tarlov scoring system, respectively, with timing, severity and recovery as important features. The Valve Academic Research Consortium (VARC) definition for stroke, which combines the National Institutes for Health Stroke Scale and the modified Rankin Score, has been updated in the VARC-3 [93]. We

recommend reporting results of endovascular repair according to both the SVS/STS reporting standards and the VARC-3 documents. However, we recognize that the VARC-3 document does not address SCIs and neither considers how to parse out complications in procedures that include both open and endovascular components, whether performed concomitantly or in a staged fashion (e.g. FET, hybrid arch). Other efforts, for example, by the Arch Academic Research Consortium, to address these unresolved issues in an expert consensus document are ongoing.

Long-term follow-up has been difficult to achieve in existing large database registries but is extremely important in assessing the durability and efficacy of aortic interventions. Not only should the intervened-upon segment be followed for healing or disease progression, pseudoaneurysm, endoleak, stent-induced new entry or antegrade/retrograde dissection, but the native aorta, whether normal or residually diseased (e.g. dilated, aneurysmal, dissected) can also progress to a state requiring intervention. The number and frequency of future interventions captured in follow-up may provide insights into the long-term superiority of open versus endovascular approaches, the appropriate sequence of interventions or important patient-specific risk factors to consider. Pooling of resources among centres and societal registries may be required to create these long-term granular, clinical databases that contain information not captured by claims data or by governmental registries that capture status as just alive or dead. Completeness of follow-up is of utmost importance in supporting study validity [94].

## Quality indicators

Although the widely used and validated EuroSCORE II (euroscore.org) [61] does include surgery on the thoracic aorta as a variable, its applicability for comparative studies is limited by its procedure-non-specific broad inclusion of aortic procedures, including arch, descending and thoraco-abdominal replacement, development of the model with a small number of thoracic aortic procedures ( $n=1636$ ) and the only measured outcome of in-hospital mortality. Data collection for a second recalibration exercise for EuroSCORE III is underway. The STS has well-developed risk models/scores for a portfolio of the most common open cardiac surgical procedures but lacks one for aortic procedures, because procedures for an aortic aneurysm have comprised only 5.5–7% of the total procedures in the Adult Cardiac Surgery Database over the past several years [95] and more precise aortic-specific variables did not exist until version 2.9 was implemented in July 2017. A subsequent iteration (version 4.20) was implemented in July 2020. With enough data for risk modelling, current efforts by the STS Aortic Task Force focus on a risk model for elective proximal aortic operations involving the ascending aorta in combination with replacement of the aortic root or aortic valve. Risk models for the aortic arch—beyond hemiarch replacement included with ascending aortic replacement—were excluded due in part to the complexity of arch operations and the smaller number of cases. The model is currently undergoing development and validation. The JapanSCORE proved to be a reliable tool for estimating operative mortality in open aortic procedures. Nevertheless, observed mortality was lower in endovascular cases, requiring an additional risk score for these procedures [96].

Studies have shown that maximum diameter does not solely predict rupture risk of a thoracic aortic aneurysm [97]. Liang *et al.*

[98] combined machine-learning algorithms for statistical shape modelling with previous work on finite element analysis of ascending aortic aneurysms [99] to develop a risk model that predicted ascending aortic rupture with an accuracy >95%; however, work on the model is ongoing to refine it and make it more easily accessible and practical for clinical application.

For aortic dissection-specific risk prediction, the GERAADA score for ATAAD, though it combines both preoperative and intraoperative variables, effectively predicts 30-day mortality for patients undergoing surgery for ATAAD [39] and is accessible via a Web-based tool. The Penn classification system for malperfusion in ATAAD is straightforward to apply and provides excellent discrimination for 30-day mortality after surgical repair, even in a cohort with more contemporary patients undergoing a variety of surgical procedures involving the ascending aorta and arch and differing cerebral protection strategies [66]. Older models include the International Registry for Acute Aortic Dissection risk prediction models for ATAAD [100] and TBAD [101] and lack an online calculating tool.

With advances in our understanding of anatomy, malperfusion, hypothermia and cerebral protection, evolving surgical and endovascular techniques and new hybrid and branched endovascular devices, the number and conduct of procedures that can be performed for aortic pathology have increased dramatically. The corresponding increase in expertise needed to be able to perform these procedures and maintain quality outcomes should be considered. The current literature has shown volume-outcome relationships impacting both low-mortality elective proximal aortic surgery [102] and those for higher mortality ATAAD [103, 104]. Further study is required, but, eventually, regional specialization for the treatment of AD, while maintaining adequate access to care, may optimize outcomes, especially for high-mortality conditions and high-risk procedures.

## AORTIC TEAMS AND HEALTHCARE IMPLICATIONS

**Recommendation Table 3: Aortic teams and healthcare implications**

Recommendations	Class <sup>a</sup>	Level <sup>b</sup>	Ref <sup>c</sup>
Shared decision-making for the optimal treatment of aortic pathologies by a multidisciplinary aortic team is recommended.	I	C	-
In patients with multisegmental aortic disease, treatment is recommended in aortic centres providing open and endovascular cardiac and vascular surgery on site.	I	C	-
Transfer to an aortic centre should be considered for patients with complex aortic pathologies.	IIa	B	[105–118]
For endovascular aortic procedures, a hybrid operating room, including an integrated imaging system, is recommended.	I	C	-

<sup>a</sup>Class of recommendation.

<sup>b</sup>Level of evidence.

<sup>c</sup>References.

## Impact of aortic disease on health care

The incidence and prevalence of AD is increasing and is driven by demographic changes in the population at large, increased awareness (especially in low- and lower-middle income countries) [119] and improved access to aortic imaging with a significant proportion of aortic aneurysms being diagnosed incidentally [120–122]. Recent studies of the global burden of aortic aneurysms and dissections have found distinct patterns in the epidemiology of AD: (i) The total number of AD-related deaths is continuously increasing (projected at +42% until 2030). (ii) Age-standardized mortality rates have decreased over the past 2 decades and will level out in high-income countries or increase in low- and lower-middle income countries over the next decade. (iii) Aortic disease-related age-standardized mortality rates remain lowest in low- and lower-middle income countries, most likely due to age distribution and under-recognition of AD. (iv) High systolic blood pressure [123] and smoking [124] remain the most important risk factors for AD. (v) Overall, high systolic blood pressure has surpassed smoking as the most important risk factor [121, 122].

In line with this epidemiological development, cardiovascular surgery societies report increasing annual numbers of aortic procedures with a current rate of approximately 5% per year [125]. At the same time, patients having aortic surgery are now older and exhibit more comorbidities [125, 126]. In comparison with other cardiac procedures, aortic surgery has a significantly higher risk of perioperative mortality and morbidity [125, 127].

The economic burden of AD is high and AD-related health-care costs are rising at a higher pace than the inflation rate [126]. The 1-year healthcare cost of patients treated for thoracic AD is approximately 50% higher in comparison to matched controls [126]. At the same time, a multitude of endovascular and hybrid solutions have become available over the past decade [126, 128]. As a consequence, high-risk patient populations, historically deemed inoperable, are more likely to receive treatment for aortic pathologies [126, 129]. In addition, the high economic burden of AD is mostly driven by post-hospital discharge costs for rehabilitation, long-term care and re-interventions [126, 130, 131]. These facts underscore the complexity of AD in terms of disease extension and progression [132].

## Aortic teams, aortic centres and involved specialties

Although interest has been growing over the past 2 decades in creating specialized teams to treat AD [115–118, 133, 134], the positive impact on clinical outcomes of an aortic team in the diagnosis, management and follow-up of patients with AD has yet to be demonstrated.

Aortic disease has traditionally been managed by a variety of specialists without a coordinated care model while attempts to establish an aortic team have been conducted at an institutional level with occasional conflicting outcomes [112–114]. The ultimate aim of an aortic team should be to provide a comprehensive care model designed to streamline an earlier and more accurate diagnosis and to implement appropriate timely therapy, including optimal medical therapy, open surgical intervention or an endovascular procedure and ultimately to produce optimal clinical outcomes.

There are numerous complex clinical and radiological patterns of AD, which justify establishment of a multidisciplinary team.

Despite large accumulated experiences in the treatment of AD, its protean and complex clinical and imaging manifestations, the diversity of clinical conditions across all segments of the aorta and the lack of well-designed and robust controlled studies still raise controversy regarding the optimal level of services [135]. Furthermore, the LoE supporting clinical decisions and procedures is relatively lacking and needs to be strengthened [136]. Ultimately, the aortic team should embrace a multidisciplinary approach according to the patient's needs, specific aortic segment involved, clinical presentation, proposed therapeutic options and estimated risks according to the experience of the surgical team [137–140].

**Definition of aortic team.** An aortic team should encompass a variety of expert specialists as a comprehensive service line whose knowledge and expertise are available on a 24/7 basis to treat all types of acute and chronic thoracic and abdominal aortic conditions in elective and emergency settings, using surgical and endovascular interventions. As stated, these concepts have been a matter of both study and controversy in a number of departmental, institutional and societal documents [136, 141, 142].

**Members of the aortic team.** Members may vary depending on the type of centre and the institutional resources. Although the patient with AD can be initially evaluated at every layer of the health-care system, core members of the aortic team should include cardiovascular surgeons, cardiologists and radiologists because all have relevant roles in the treatment of AD [128, 142, 143]. Moreover, for the routine practical approach to the patient and for specific clinical questions, anaesthesiologists, perfusionists, critical care specialists, geneticists, genetic counsellors, neurologists, pulmonologists, renal specialists, specialized nurses and social workers should also be considered as part of the aortic team.

The aortic team deals with a disease process that requires life-long surveillance to oversee the natural history of treated and untreated aortic segments as well as potential complications that arise during follow-up after a given procedure [143, 144]. The role of genetic screening for heritable aortic conditions in individuals or entire families is an essential component of the aortic team care model [80, 145].

**Communication.** Standard operating procedures of the aortic team, including a regular meeting schedule and agenda and a regional network organized around a specific aortic centre (AC) should be defined locally [105]. This paradigm is critical for patients with chronic conditions and elective interventions. Patients with AAs who present outside regular work hours must be assessed by the on-call specialists.

Rapid communication and sharing of vital clinical and anatomical information with other regional institutions would ideally be achieved by digital solutions. Decisions on interhospital transfer of patients for acute assessment or outpatient extended evaluation can be then expedited to avoid delays in diagnosis and treatment. However, availability of digital image transfer platforms or a teleradiology infrastructure varies significantly among referring hospitals. In addition, interoperability of existing image transfer platforms is limited [146].

Communication within the aortic team after hours markedly depends on local policy. Even reference centres cannot always provide a dedicated aortic surgical team 24/7 [140]. On call

cardiovascular specialists will ultimately need to decide upon appropriate triage of emergency cases within the existing multidisciplinary team. Backup communication with aortic specialists is often provided by colleagues on an individualized private basis but is rarely institutionalized.

**Teaching and training.** As with many surgical domains, outcomes after aortic procedures depend significantly on clinical experience [140, 147]. Learning curves are inevitable, and, as a result, assistance or proctoring by experienced surgeons is an essential part of training within the aortic team in disseminating knowledge on AD [140]. Because multiple multidisciplinary teams are being organized to cover essentially every aspect of AD [106, 107, 148, 149], it is essential that, in a structured aortic team, transfer of knowledge and adequate exposure to theoretical and practical aspects of AD be encompassed. These educational concepts also apply to hands-on practice in low- and high-fidelity simulators of different interchangeable capabilities [150–154], an integral part of current and future core curricula across all professional profiles involved in the provision of care for AD [155, 156].

Establishment and development of an aortic team in an AC is the consequence of the evolutionary improvement in the knowledge of AD. Accumulated experience dictates the reorganization of service provisions and continuation of care through the collaborative efforts of a variety of professionals. This concept has been discussed for a long time [157], and increasing amounts of data support the clinical benefit of a multidisciplinary team approach modelled around numerous institutions and health systems [143].

**Aortic centres.** The concept of ‘Centers of Excellence’ originated in the establishment of national cancer centres in North America following the National Cancer Act of 1971 [108]. Such centres were ultimately looked upon to establish the standard of care, and patients with cancer had improved outcomes when treated at ‘Centers of Excellence’ [108]. For patients with cardiovascular disease, the concept of comprehensive heart valve centres was recently introduced and emphasized numerous essential components including physician expertise and experience, adequate institutional facilities and resources and adequate skills for research, innovation, and education [141].

Although there is some debate as to the optimal manner in which to regionalize care in patients with AD [134], the existence of an AC has merit and should be balanced against the need for optimal timing in the treatment of aortic pathology for maximal patient benefit [53].

Several characteristics have been described that should distinguish an AC from its institutional counterpart, which include providing the highest-level quality of patient care, innovation through research, education of both learners and colleagues and defining standards of care [108]. The specific clinical components may differ from centre to centre. Distinguishing features of a comprehensive AC should encompass the following:

1. The presence of cardiac and vascular surgical expertise as well as endovascular specialists with extensive experience in managing all aspects of complex AD in the setting of a high volume of aortic interventions.
2. Imaging specialists and expertise to perform and interpret CT, magnetic resonance imaging (MRI) and echocardiography imaging.
3. Adequate anaesthesiology expertise in the management of acute AD.

4. Intensive care unit with experience in management of AD.
5. Organization of outpatient management of pre- and postoperative patients.
6. Onsite availability 24/7 of all experts with digital imaging and digital transfer capability to treat both elective and emergency cases.

Implementation of an AC using the described essential elements has been associated with improved outcomes in terms of both emergency [112, 137] and elective settings [158]. In addition, implementation of strategic workflow processes and systems can result in significant increases in aortic volume for both elective and emergency cases as well as sustainable improvements in transfer centre and emergency medical service efficiency [108, 135, 136].

## DIAGNOSTIC WORK-UP AND IMAGING

**Recommendation Table 4: Diagnostic work-up and imaging**

Recommendations	Class <sup>a</sup>	Level <sup>b</sup>	Ref <sup>c</sup>
<b>Clinical risk assessment</b>			
Preoperative risk assessment is recommended.	I	B	[159–162]
TTE is recommended as part of the preoperative work-up.	I	B	[163–166]
Coronary evaluation/assessment should be considered to rule out coronary artery disease.	IIa	B	[167]
<b>Imaging–morphology and function</b>			
As the first line diagnostic modality, CTA from the common carotid to the common femoral arteries is recommended for imaging the aorta and its pathologies.	I	C	-
For repetitive imaging of the aorta, it is recommended that the same imaging modality be used, with a similar method of measurement to assess change in diameter.	I	C	-
Assessment of patency and morphology of the circle of Willis should be considered prior to total aortic arch replacement.	IIa	C	-
In patients with known or suspected aortic disease, it is recommended that aortic diameters be measured at reproducible anatomical landmarks (and its maximal diameter) perpendicular to the axis of blood flow.	I	C	-
In asymmetric or oval contour cases, reporting the longest diameter and its perpendicular diameter should be considered.	IIa	C	-
When performing CT or MRI, one should consider measuring the aorta from the outer edge to the outer edge, if the vessel wall is visible.	IIa	C	-

Continued

One should consider measuring the aortic root from sinus to sinus, and the largest diameter measured should be considered as a reference value.	IIa	C	-
Assessment of the risk of radiation exposure is recommended, especially in younger adults and in those undergoing repetitive imaging.	I	C	-
For CT or MRI techniques involving the entire aorta, it is recommended that motion artefacts of the ascending aorta be minimized and that the entire aorta should be acquired in a single data set.	I	C	-

<sup>a</sup>Class of recommendation.

<sup>b</sup>Level of evidence.

<sup>c</sup>References.

CTA: computed tomography angiography; MRI: magnetic resonance imaging; TTE: transthoracic echocardiography.

## Diagnostic work-up for acute aortic syndromes

The diagnostic work-up to confirm or to rule out AD is highly dependent on the a priori risk of this condition, which can be stratified into 3 groups of variables using the Aortic Dissection Detection Risk Score: predisposing factors (e.g. Marfan syndrome), pain characteristics (e.g. chest, back or abdominal pain) and high-risk clinical examination features (perfusion deficit, new aortic insufficiency murmur). The risk score can easily be accessed online (<https://www.mdcalc.com/calc/4060/aortic-dissection-detection-risk-score-add-rs>). However, beyond this clinical risk score, a constellation of first-line simple examinations, including the electrocardiogram (ECG), the chest X-ray, TTE and biomarkers, is performed primarily in patients with chest pain in the emergency room and can be useful to rule out alternative diagnoses (e.g. myocardial infarction or pericarditis) or even, in the case of TTE, point to the diagnosis of AD by detecting an aortic intimal flap, aortic wall thickening and/or dilatation, major aortic valve regurgitation with or without cusp prolapse, as well as pericardial effusion [168, 169]. Especially when inconclusive, TTE can be finished by looking at the abdominal aorta, which may be helpful to detect a flap not visualized at the thoracic level. A CT scan of the entire aorta is the mainstay imaging technique for confirmation, except when the patient is highly unstable and intubated. Transoesophageal echocardiography (TOE) can be a reasonable alternative for patients under sedation in the intensive care unit (ICU) to make the diagnosis if TTE is inconclusive. Otherwise, TOE can be performed in the operating room for type-A aortic dissection because it is useful to complete the information provided by TTE+CT.

## Clinical risk assessment

Risk stratification of patients is crucial for identifying appropriate candidates for specific aortic procedures. The risk constellation and case mix are no less heterogeneous in patients with AD than in the cardiac surgical populations. Recently, the European Society of Cardiology published an excellent outline (endorsed by the European Society of Anaesthesiology and Intensive Care)

on the cardiovascular assessment and management of patients who undergo noncardiac surgery [170]. Others have documented the importance of tailored anaesthesia and haemodynamic monitoring for noncardiac surgery in patients with valvular disease [171]. Several risk scores are available as shown previously (Chapter on 'Nomenclature and risk stratification'). But an important limitation of the available scores is their inability to determine futility of care. Unfortunately, there is to date no standardized and objective definition for surgical unfitnes [159]. Evaluation by experienced surgeons and multidisciplinary aortic teams may be an important way to avoid arbitrary denial of surgery to patients who may benefit from an operation. Of note, invasive therapeutic options should be weighted individually in each patient. Hence, general health status, life expectancy and frailty have to be assessed and form the basis for offering invasive treatment.

Frailty is one of the most important elements not routinely included in risk models. Grip strength and gait speed can be captured in the overall functional status assessment. Age, body mass index, preoperative anaemia and hypoalbuminemia have also been recognized as indicators of frailty [160]. Daily activities and weight (loss) could provide additional information about the overall health of the patient [172–174]. Sarcopenia, identified through psoas muscle mass measurement by preoperative CT imaging, has been proposed as a possible objective measure for frailty assessment [161]. Assessing baseline neurologic function is important for the initial risk stratification, and systemic cognitive assessment by experts should be part of the evaluation. A prior stroke could contribute to frailty and therefore should be added to the frailty index used to assess the patient's ability to perform independent daily activities. A previous stroke can contribute significantly to neurologic morbidity [175].

A preoperative workup that includes pulmonary function tests may be beneficial, and blood work (including kidney and liver function tests) is necessary for patients undergoing any elective aortic procedure [175]. Peripheral vascular disease and prior intervention, including radiation therapy, are important determinants of clinical outcome. Coronary artery disease and cardiac function are crucial in patients who undergo elective cardiac and aortic interventions. An invasive coronary angiogram is recommended in patients with known coronary artery disease, whereas non-invasive testing, such as cardiac CT, may be sufficient in selected patients without symptoms of coronary artery disease [175].

The overall frailty and geriatric risk burden include cognitive, social, functional and nutritional status. These variables should be considered for stratification of surgical risk, particularly in elderly patients.

## What to look for to reduce the risk of neurologic complications

Initial imaging plays a crucial role both in assessing the extent and morphologic expression of the respective AD and in decision-making and planning of the most suitable treatment option when indicated.

The focus is not only on the respective aortic pathology but also on the anatomy of the supra-aortic vessels including the cerebral supply of the circle of Willis and on its structure or variations. In addition, the assessment of the spinal cord perfusion is of enormous importance. Evaluation of both is essential before

beginning any treatment in order to minimize the risk of neurologic complications using CT angiography as the method of choice [162].

It is crucial that the entire aorta is imaged including the supra-aortic vessels down to the femoral bifurcation irrespective of the underlying aortic pathology. In case of planned procedures on the aortic arch, the circle of Willis should also be imaged to assess its morphology and patency. This approach enables optimal treatment planning and, in case of open surgery, also perfusion planning and minimizes the burden on the patient from repetitive examinations.

In patients with aortic pathologies, anatomical variants, especially of the aortic arch, such as a bicarotid trunk, aberrant right subclavian artery or an isolated left vertebral artery are common and increase the risk of postoperative neurologic deficits [162, 176]. A unilateral hypoplastic vertebral artery is often the sole supplier of blood to an isolated cerebral region and does not form the basilar artery as usual. In many cases there is even an absence of visible collaterals. Moreover, data suggest that 50% of patients with AD have aortic arch anomalies, and in 9% of these, hypoperfusion could have been caused by unilateral selective antegrade cerebral perfusion. This situation affects the left posterior communication artery in particular, because it identified aplasia or hypoplasia in 35.6% of these patients [177]. A recent meta-analysis evaluating 4 commonly used cerebral protection strategies revealed superior outcomes in terms of in-hospital mortality and stroke for unilateral cerebral perfusion in moderate hypothermia [178]. Of note, this study also includes hemiarth procedures and only 40% were total arch procedures. Nevertheless, high-moderate hypothermia with selective antegrade cerebral perfusion seems to be the safest concept for cerebral protection for total arch replacement. Accordingly, variants of the aortic arch can significantly influence the perfusion strategy and technical implementation in open and endovascular treatments, which makes meticulous planning based on the anatomical conditions necessary.

In addition to the detailed cerebral perfusion conditions, the assessment of the anatomical and functional supply of the spinal cord is essential. The supply is based on 2 essential interrelated components that must be assessed before each procedure: (i) the 4-territory concept that describes the large extraspinal inflows, comprising the left subclavian, intercostal, lumbar and internal iliac arteries [176]; (ii) the intraspinal/paraspinal arterial collateral network (CN) [179, 180]. In addition to other factors, the maximum possible preservation of both structures is crucial to prevent SCIs. With regard to the 4 vascular territories, registry data have shown that eliminating 1 territory alone has minimal impact on the development of SCIs, whereby eliminating 2 territories is extremely relevant, especially in combination with intraoperative hypotension [176]. Recent data on the spinal cord's CN suggest that both para- and intraspinal components are crucial and that both need to be adequately supplied. The anterior radiculomedullary arteries (ARMAs) play an important role in components. It turned out that no single major artery is decisive, but rather the total number and distances between the ARMAs are. A larger number with smaller distances seems to be associated with the lowest risk for an SCI [179, 180]. Moreover, the knowledge of the exact location of large suppliers is crucial in order to determine where exactly to implant the stent grafts or to preserve them during open replacement.

Thus, the preservation of the left subclavian and internal iliac arteries in open and endovascular procedures, but also of the

larger segmental arteries supplying the intraspinal/paraspinal network in open thoraco-abdominal aortic replacement, is of particular importance. Exact knowledge of the anatomical and functional conditions enables the form of treatment to be adapted (open vs endovascular) but also enables preparation for an intervention using priming through prior targeted coiling of segmental arteries [181, 182].

## Imaging—morphology and function

Most imaging can be performed nowadays non-invasively; the most commonly used modalities are CT, MRI, TTE, TOE and abdominal aortic ultrasound. But invasive imaging such as invasive coronary angiography may also provide an important assessment of the coronary arteries and can be performed safely in patients with chronic ADs [167].

The choice of imaging modality is based on patient- and institution-specific factors including haemodynamic stability, availability, local expertise, allergy to contrast media, renal function and patient tolerance. However, CT has been established as the predominant modality due to its high-resolution, 3-dimensional (3D) image data sets and rapid acquisition. Further, CT scanners are omnipresent, and, with improved CT technology, the administered radiation dose has decreased significantly. Although low, the radiation dose can accumulate with repeated imaging and should be prevented in young patients by using radiation-free modalities. Further, it is important that the same imaging technique be used for repeated imaging, if possible, given otherwise the increased risk for inter-scanner and even more for inter-modality variability [183].

**Computed tomography.** Most recent CT technology, such as a dual-source, photon-counting CT scanner, allows image acquisition with a spatial resolution of isotropic 0.2 mm, a temporal resolution of 66 ms and a coverage of 2 m in <3 s [184]. As a minimum standard for imaging of the aorta, an isotropic resolution of 1 mm should be available in the CT scanner system used. For imaging the aortic root and the ascending aorta, ECG-triggered and/or fast acquisition techniques are recommended to minimize pulsation artefacts and increase measurement accuracy and diagnostic reliability. Furthermore, it is advantageous if the aorta is visualized as a whole, which can be challenging depending on the available CT technology and acquisition technique.

The use of an intravenous, iodine-based contrast agent is suggested for most aortic imaging because it allows delineation of the aortic lumen and improves the assessment of aortic wall changes. If not otherwise possible or desired, non-contrast CT imaging can yield accurate assessment of aortic aneurysm diameter for e.g. follow-up.

In addition, procedure-related risk factors include the high volume and/or repeated administration of contrast agents in a short period of time. Dual-energy and so, even more, photon-counting CT can reduce the necessary contrast agent volume due to improved contrast-to-noise using low-keV virtual monoenergetic reconstructions [185]. Nevertheless, these techniques should only be used if they do not negatively impact the minimal requirements (e.g. spatial/temporal resolution, ECG-gating) of CT imaging of the aorta.

Computed tomography has a very high sensitivity and specificity for AAS (including acute aortic dissection, IMH, PAU) and traumatic aortic lesions as well as aneurysms and silent

dissections [186]. In addition, CT can detect concomitant coronary artery and/or branch vessel involvement as well as pericardial involvement and help identify entry tears. In patients suspected of having AAS, a CT scan is also useful to identify alternate diagnoses if the former is not visualized [187]. Furthermore, cardiac CT serves as a non-invasive alternative to invasive angiography to rule out coronary artery disease [188].

A contrast-enhanced arterial-phase series extending from the thoracic inlet to the level of the femoral artery is recommended in most cases. If the cerebral arterial circulation is not known, the scan can be extended cranially to cover the circle of Willis if the surgical procedure requires selective cerebral perfusion. Furthermore, there is an association of an aortic and an intracranial aneurysm [189, 190]; although the radiologist should be aware of this association while reading the CT scan, the scientific evidence is not strong enough to recommend a screening test for an intracranial aneurysm in patients with an aortic aneurysm.

If an AAS is suspected, a non-contrast series prior to the arterial-phase series is usually performed to better distinguish a possible IMH from other causes of aortic wall thickening; further, a portal venous-phase series can be useful to determine malperfusion of the abdominal organ. Also, a native CT series should be performed prior to the arterial-phase series at the first postoperative scan to reliably distinguish foreign material from contrast agent. Additionally, a venous-phase series using computed tomography angiography (CTA) can provide important information to assess false lumen flow particularly after an operation for type A or in type B with a small entry tear size and in the diagnosis of endoleaks after TEVAR implantation.

**Magnetic resonance imaging.** Magnetic resonance imaging is the only other modality besides CT that can provide 3D images with sufficient temporal/spatial resolution and anatomical coverage of the aorta to determine vessel enlargement and vessel wall changes. Due to its better soft-tissue contrast, MRI is the preferred modality to characterize aortic wall changes associated with inflammation. Further, MRI provides physiological assessment of ventricular and valvular function and quantification of blood flow. Similar to CT, ECG-triggered acquisition should be chosen if the aortic root and ascending aorta require imaging. An MRI does not require ionizing radiation. Therefore, MRI is often the first choice for the evaluation of congenital aortic malformations and is recommended for serial imaging in young patients or in patients in whom a radiation dose should be avoided (e.g. during pregnancy).

Limitations of MRI include the occurrence of artefacts in patients with stents and other metallic implants or devices. In addition, it has much longer acquisition times and lower spatial resolution compared to CT. Further, MRI has a limited ability to monitor and treat unstable patients in the scanner. Therefore, this modality is rarely used with patients suspected of AAS, especially when the patient is unstable.

Gadolinium-based intravenous contrast agents can be used to enhance MRI and are often used for MR angiography. Gadolinium-based intravenous contrast agents carry some risk for nephrogenic systemic fibrosis in patients with impaired renal function. The risk differs significantly between different types of gadolinium-based contrast agents. For agents with the lowest risk (like macrocyclic agents), assessment of renal function prior to MR scanning is not mandatory, and a patient should be

encouraged not to refuse a clinically well-indicated enhanced MR examination to avoid a contrast agent [191].

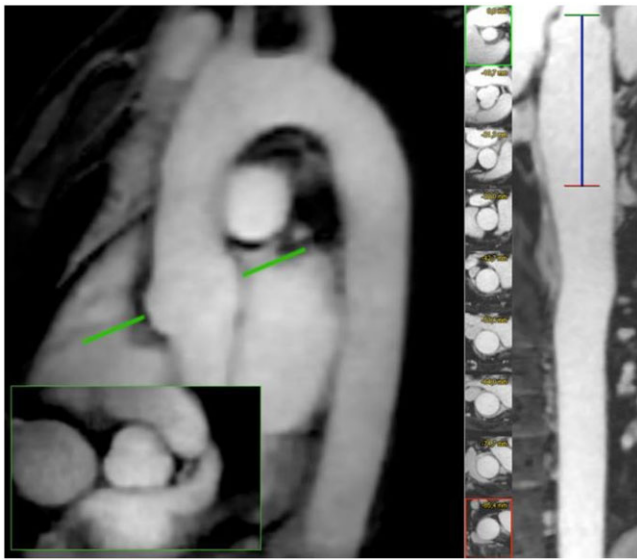
An MRI can be performed without intravenous contrast, even for MR angiography. However, dedicated sequences such as native 3D TrueFISP or magnetization-prepared 3D non-balanced dual-echo Dixon are available to examine the aorta in the MR scanner without contrast agent (Fig. 8).

**Transthoracic echocardiography.** Transthoracic echocardiography is the most commonly used imaging modality for the initial examination of the thoracic aorta. It is particularly useful for visualizing the aortic root and ascending aorta as well as for assessing the anatomy and function of the aortic valve [164]. To visualize the mid-distal ascending aorta, it may be necessary to move the transducer to the upper intercostal spaces, whereas right parasternal views might help visualize the distal portion of the ascending aorta. Although TTE is not ideal for imaging the aortic arch, it can often visualize the vascular branches of the aortic arch and proximal descending aorta and aid in the diagnosis of coarctation of the aorta (CoA) and ductus arteriosus. Transthoracic echocardiography is portable and can be performed at the bedside with high spatial and temporal resolution. It is useful in the evaluation of complications such as aortic regurgitation, left ventricular (LV) dysfunction and cardiac tamponade. It is useful in the longitudinal monitoring of the aortic root and ascending aortic dilatation, provided these aortic segments are well visualized. Moreover, TTE is crucial for providing important information on ventricular as well as valve abnormalities in patients undergoing endovascular treatment [163, 166].

**Transoesophageal echocardiography.** Transoesophageal echocardiography provides high-resolution images of most of the thoracic aorta, except for a small segment of the ascending aorta distally due to acoustic shadowing of the trachea. It is also useful for a detailed understanding of aortic valve anatomy and function. Transoesophageal echocardiography is particularly useful in the intraoperative evaluation of patients with AAS to guide both surgical and endovascular repair strategies and to assess true and false lumens before and immediately after aortic repair. This imaging modality is very useful in intubated patients in the ICU, especially if the transfer of the patient to the radiology unit is hazardous because of haemodynamic instability.

**Intravascular ultrasound.** Intravascular ultrasound is useful in guiding the endovascular treatment of complex lesions of the thoraco-abdominal aorta because, in addition to assessing the landing zone, it can visualize aortic size, tortuosity, plaque burden, calcification, vascular branching and endovascular filling defects (e.g. thrombosis, entrapment valves). It is also useful in aortic dissection to differentiate between true and false lumen dissection. Thus, endovascular ultrasound can be used to guide endovascular or open repair. However, this imaging method is not widely used because of alternate possibilities and its cost.

**Ultrasound of the abdominal aorta.** Ultrasound is recommended for screening and monitoring of an abdominal aortic aneurysm [192], which is defined as >30 mm in diameter, using primarily an anterior-posterior diameter, and using the outer edge-to-outer edge measurement. Although it is an effective imaging modality with high diagnostic accuracy for detecting

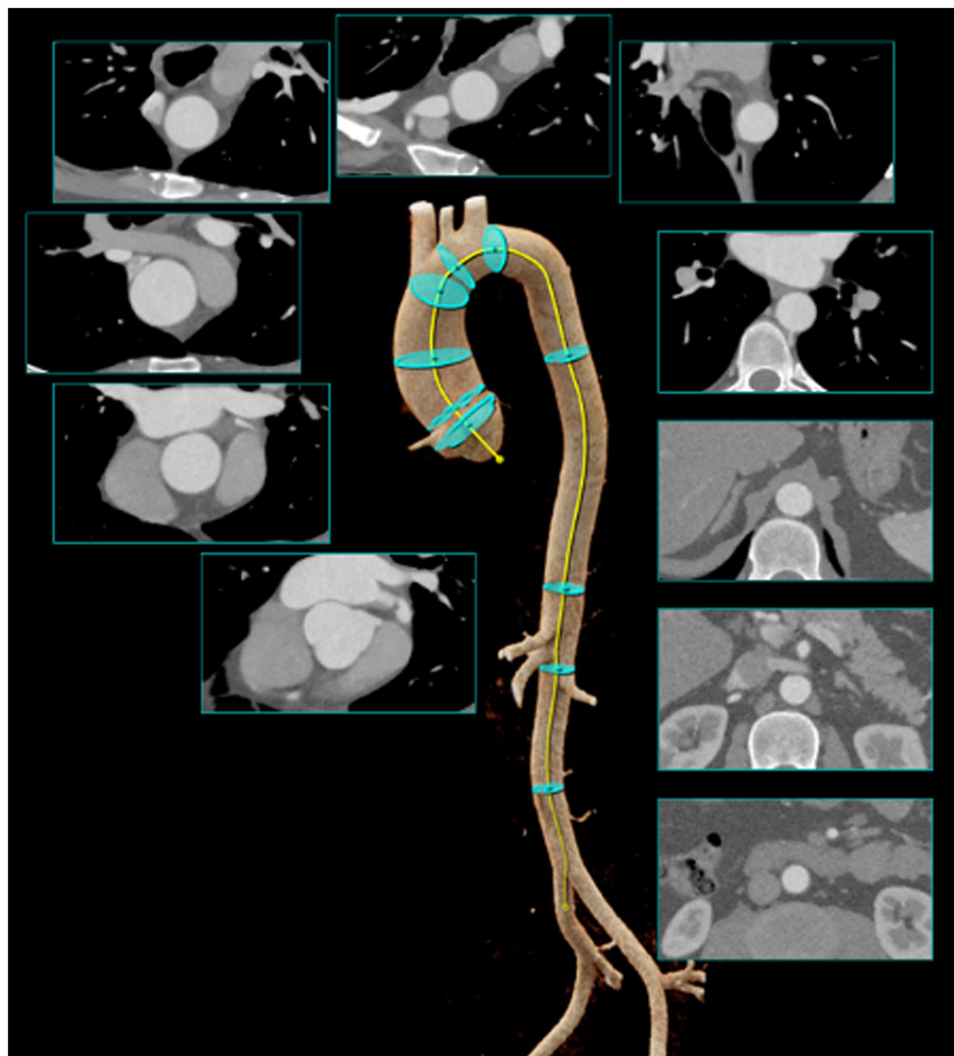

**Figure 8:** Contrast-free 3-dimensional magnetic resonance angiography of the thoracic aorta. Using accelerated acquisition magnetic resonance techniques allows electrocardiographic and breathing-gated isotropic imaging of the aorta with an isotropic resolution of 1.2 mm within 3–6 min.

aneurysms, interobserver variability exists and accuracy can be limited by obesity and intestinal gas overlay.

Comprehensive abdominal aortic ultrasound can also pick up other aortic pathologies such as plaque formation, mural thrombosis, rupture or aortic fistula, findings that require further imaging using CT or MRI. Abdominal ultrasound can also be used to monitor patients undergoing abdominal endovascular aortic aneurysm repair (EVAR), where contrast media may improve its performance, especially to detect endoleaks.

**Conventions for imaging-based assessment and measurements.** Accurate measurements of the aorta are essential for characterizing AD and making treatment decisions. In addition to accuracy, reproducibility of measurements is critical for longitudinal assessment. Measurements should be performed perpendicular to the long axis of the aorta at specific segments, usually 8 measurements in the thoracic aorta (Fig. 9). In addition, measurements are taken at the site of the abnormality and at the point of maximum enlargement, if an aneurysm is present. Whereas reconstructing perpendicular to the long axis is relatively simple (and can be reviewed/ revised at a later time) in imaging modalities delivering 3D data sets such as CT or MRI, this procedure is



**Figure 9:** Systematic assessment of the aortic dimensions including the length of the ascending aorta. The diameter should be derived from cross-sectional images.

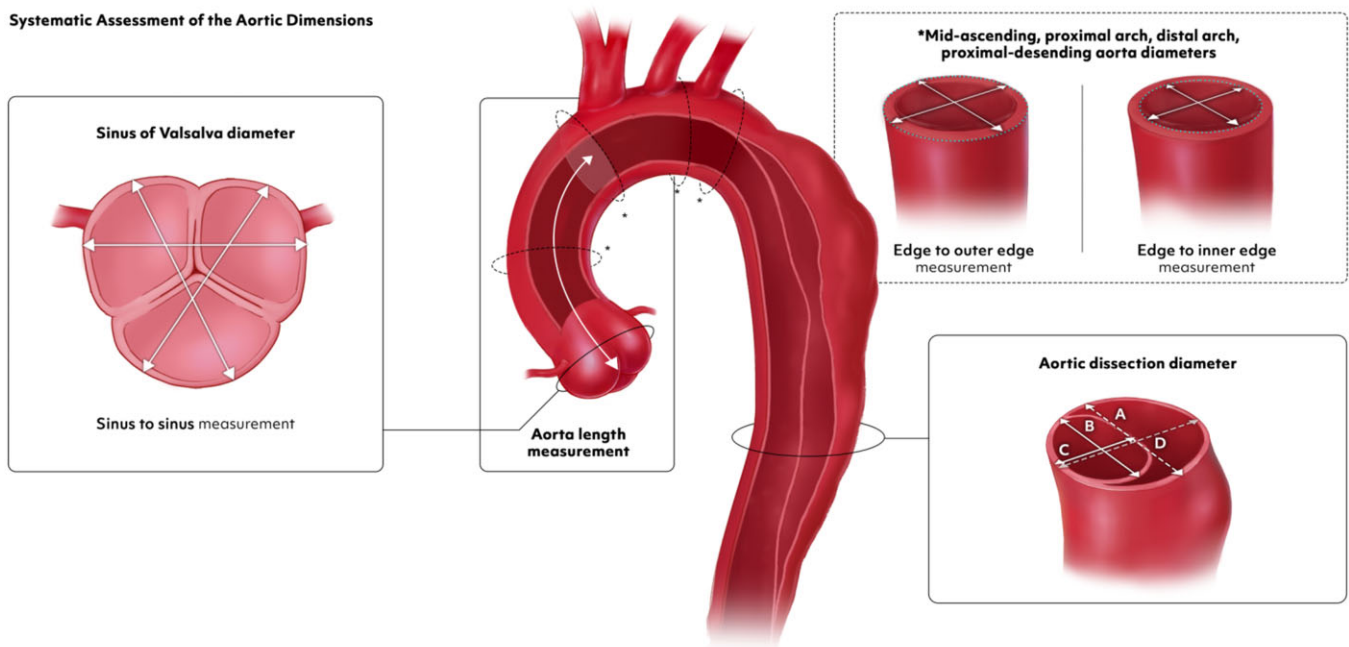
more difficult and subject to diameter overestimation and variability when using TTE.

Due to technical differences among the available imaging modalities, the standard for measuring aortic dimensions varies significantly. One major aspect is the precise definition of the start/end-point for the aortic diameter. In the past, it was argued that one should measure the aortic diameter from inner-edge to inner-edge as long as no wall changes were present. Because wall changes are common (e.g. discrete thickening from atherosclerosis, IMH, aortitis or other processes), maximum diameter should be measured including the aorta wall using the outer-to-outer edge method. However, visualization of the aortic wall may be difficult by the applied imaging modality, particularly in the ascending aorta. In case no aortic wall is visible, the outer-to-outer edge method is identical to the inter-to-inner-edge method.

Another major aspect is the definition of aortic root measurements. In TTE, the aortic root can be measured from the leading edge of the anterior wall to the leading edge of the posterior wall. On CT and MRI, the typical approach is to measure the aortic root from the commissure to the opposite sinus or from sinus to sinus, which results in slightly larger dimensions. Both methods can be used, but consistency is necessary for longitudinal evaluation. Not surprisingly, the aortic dimensions vary also across the heart cycle, which should be considered in the report and in the longitudinal analyses. Detailed illustrations of aortic measurements are summarized in Fig. 10.

Aortic diameter has been shown to be a good risk factor for the development of aortic dissection and rupture. More complex assessment matrices have been discussed, using either area or volume instead of diameter or by height or by body surface area indexing measurements.

#### Systematic Assessment of the Aortic Dimensions



**Figure 10:** Systemic assessment of aortic dimensions. (A) Maximum total aortic diameter, (B) maximum true lumen diameter, (C) minimum true lumen diameter and (D) minimum total aortic diameter.

## Emerging fields in imaging

**Automated measurements of aortic dimensions.** Improved availability of 3D imaging data sets, especially for CT, and of growing computational power has yielded multiple analytic tools, which provide (semi-)automatic measurements of vascular dimensions [193, 194]. The automated measurements of the thoracic aorta are possible with high accuracy even in CT scans without contrast medium [195]. Beside accuracy, automated measurements have the potential to reduce interobserver variability. Thus, these software tools should be inserted into the clinical workflow, if possible, even if none are available for aorta-dedicated imaging, to reduce the risk of a missed aneurysm.

**Length of the ascending aorta.** Most software tools that determine aortic dimensions using 3D data sets fit a centreline in the aorta. The centreline should be parallel to the potential blood flow, in the middle of the true lumen and perpendicular to the cross-sectional measurements. Performing measurements along the centreline can derive length parameters of different vascular segments, which can be helpful e.g. for interventional planning.

The length of the ascending aorta illustrates the natural history of the ascending aortic aneurysm, and its measurement should be used to improve the risk stratification ('see above'). It is defined as the distance from the aortic annulus to the origin of the innominate artery [196]; however, it is not used consistently. Nevertheless, the length of the ascending aorta should be part of the imaging reports (Fig. 9) and in perspective included in the assessment.

**4-Dimensional magnetic resonance imaging.** Four-dimensional magnetic resonance (4D flow MR) imaging has been

around for some time but has become increasingly clinically available in recent years due to faster MR acquisition sequences and commercial post-processing/analysis software. This method is an extremely powerful, non-invasive tool that allows visualization of complex flow patterns and quantification of parameters related to flow dynamics in the aorta [197]. Thus, 4D flow MR imaging helps to understand the pathological haemodynamics related to aneurysm formation, such as that in patients with BAV. Bissell *et al.* [198] found that, by comparing 95 patients with BAVs to 47 healthy controls, increased right-handed helical flow is the most common flow alteration in the ascending aorta, possibly leading to increased rotational WSS and subsequent complications.

Further, 4D flow MR imaging is desired to improve risk prediction in patients with chronic aortic dissection. Most recent key publications found that the false lumen ejection fraction, which is defined as the ratio of retrograde flow rate at the dominant entry tear during diastole over the antegrade systolic flow rate, was an independent predictor of aortic growth [199, 200] and that high-volume turbulent flow in the false lumen can signify a high risk of late complications [201]. All major studies advocate quantification of flow volume and velocity and/or visualization of flow alteration in the false lumen as potential markers of risk stratification for delayed aortic complications in patients with chronic aortic dissection.

Several 4D flow MR imaging studies in patients with aortic prosthetic grafts showed significantly higher levels of altered flow patterns relative to healthy volunteers. These flow patterns were related to the surgically altered aortic geometry with noncompliant artificial grafts or graft kinking leading to pressure gradients and nonuniform stress distributions [202].

4D flow MR imaging is a promising diagnostic tool for ADs allowing (patho)physiological measurements. However, standardization is missing, which makes clinical applicability complex at the moment.

### **Extended reality in the context of vascular surgery.**

Improved visualization of the acquired image data and novel access to this data are required to extract the maximum information from these data and make them understandable for the benefit of the patient. Although volume-rendering techniques have become standard, even with ray-tracing light simulation, the technical advancement of extended reality makes applications in the clinical context possible with reasonable effort.

Augmented reality (AR) in surgery in general relies on the registration of a virtual image or object onto the real patient using a co-registration method, which can trace the real environment and projects virtual objects in the correct position and orientation. Image overlay technologies are increasingly used in vascular surgery, with their value being reported in the endovascular treatment of AD [203]. There is evidence that they can improve technical success while reducing contrast volume, radiation dose and overall procedural times. However, concerns remain regarding the accuracy of image registration, especially with more complex anatomies [203]. A common problem is distortion of vascular structures due to breathing, surgical manipulation or the use of rigid stenting systems leading to stretched

vessels. New technologies offer new solutions to improve the real-time accuracy using robust deformable registration algorithms or real-time intraoperative 3D intraoperative scanners to enhance AR-guided surgery [204]. In particular, 3D and intravascular ultrasound provide non-radiometric and non-contrast modes to produce real-time images for intraoperative use, while electromagnetic tracking provides simultaneous spatial information about catheter devices.

Similarly, 3D printing is also explored in the context of vascular surgery, and most use cases supported by evidence are discussed in the field of preoperative planning and surgeon training [205]. More research and development are necessary to overcome barriers between different methods of extended reality such as AR, virtual reality or 3D printing and to shift such technology into clinical practice.

**Photon-counting computed tomography.** Photon-counting CT is emerging in clinical service and is a technology with the potential to overcome major limitations of the current CT scanners, improving and expanding the clinical applicability of CT imaging. Photon-counting CT uses new energy-resolving x-ray detectors, counting the number of incoming photons and measuring photon energy [206, 207]. This technique results in CT data at very high spatial resolution, without electronic noise and with improved image contrast. Moreover, photon-counting CT can reduce radiation exposure, reduce artefacts, e.g. from metal implants and optimize the use of contrast agents. It could also make simultaneous images with multiple contrast agents. Initial clinical results are promising and show particular strengths in cardiovascular imaging [184].

## **ACUTE AORTIC DISEASES—NATURAL COURSE OF THE DISEASE AND WHEN TO INTERVENE**

### **Acute aortic syndromes**

Acute aortic syndromes encompassing aortic dissection, IMH and PAU are life-threatening conditions requiring urgent evaluation and treatment. Acute aortic syndromes can present with a variety of manifestations, ranging from bleeding within the media with varying degrees of medial disruption—from localized, isolated disruption in IMH to widespread, propagating medial disruption in classical aortic dissection. Irrespective of the sub-variety, all AASs require prompt diagnosis and immediate institution of optimal medical therapy in order to prevent acute complications (organ ischaemia or aortic rupture) and death. Medical therapy includes strict blood pressure management to reduce aortic wall stress, coupled with pain control. A targeted systolic pressure of 100–120 mmHg and a heart rate of 60–80 bpm are recommended [208, 209]. Administration of intravenous beta-blockers prior to intravenous vasodilators (e.g. sodium nitroprusside, clevidipine) is efficacious, blunting the impulse of cardiac contraction, lowering the blood pressure and decreasing wall stress on the adventitia [210]. Adequate invasive monitoring should be provided in an intermediate or ICU setting.

## Type A aortic dissection.

**Recommendation Table 5: Acute aortic diseases: Type A aortic dissection**

Recommendations	Class <sup>a</sup>	Level <sup>b</sup>	Ref <sup>c</sup>
Initiation of emergency surgery is recommended in patients presenting with acute type A aortic dissection.	I	B	[211, 212]
A tear-oriented approach with exclusion or resection of the primary entry tear in the ascending aorta and arch is recommended.	I	B	[213, 214]
Inspection and coverage of communications between lumina in the proximal descending aorta may be considered in specialized centres for prognostic reasons.	IIb	C	-
Despite preoperative neurologic dysfunction or non-haemorrhagic stroke, open repair should be considered.	IIa	B	[215–217]
In case of clinical and imaging evidence of visceral malperfusion, revascularization may be considered prior to aortic repair.	IIb	C	-
Antegrade systemic perfusion via axillary or direct aortic cannulation should be considered.	IIa	B	[218, 219]
An open distal anastomosis during lower body hypothermic circulatory arrest is recommended.	I	B	[220, 221]

<sup>a</sup>Class of recommendation.

<sup>b</sup>Level of evidence.

<sup>c</sup>References.

Acute aortic dissection occurs when an intimal tear is propagating the blood flow into the media, resulting in the separation of the aortic wall layers by an intimal flap. The propagation of this process forms a true and a false lumen, with or without communicating re-entries.

Type A dissection refers to those starting in the ascending aorta. The natural course of the disease is very aggressive due to sequelae varying from organ malperfusion to acute heart failure (from aortic insufficiency), to aortic rupture.

Aortic dissection has a well-deserved reputation as the Great Masquerader: Because the aorta supplies every organ in the body, aortic dissection can present with symptoms referable to any organ. It is essential for emergency department personnel to have a high index of suspicion for aortic dissection. The D-dimer blood test is extremely helpful in the emergency setting. If the D-dimer is negative, the patient does not have an aortic dissection. (The D-dimer, while very sensitive, is not, however, at all specific; it can rule out, but not definitively rule in, a dissection.) A meta-analysis revealed that a D-dimer >500 ng/ml increases the potential to identify patients suspected to have acute aortic dissection [222]. If treated conservatively (without surgery), ATAAD is associated with an early mortality of 0.5% per hour [223]. Surgery has proven clear benefits over medical therapy [211]. Due to improvements in diagnostics as well as surgical strategies,

postoperative mortality, previously extremely high, has decreased to 15–18% with advancement in care over the last 2 decades [212, 224]. Still, evaluation of each patient's condition must weigh the risk of surgery—with all potential adjuncts necessary—against optimal medical therapy. Risk scores have been created in recent years, enhancing treatment decisions [39]. In patients with significant contraindications or comorbidities, conservative treatment may, on occasion, be best. In unsuitable surgical candidates, endovascular repair has been performed, mainly in a compassionate care setting, in a limited number of inoperable patients [225]. However, the 'high rent district' of the aortic root is highly inimitable to current endovascular interventions, with the delicate aortic valve leaflets and the crucial coronary ostia at risk.

*Preoperative evaluation.* Any and all branch vessels of the aorta are potentially vulnerable to malperfusion consequent to type A aortic dissection. False lumen expansion due to haematoma or thrombosis can lead to static obstruction of the true lumen of the aortic branches. In addition, dynamic obstruction of aortic vessels can lead to low flow phenomena and subsequent malperfusion. Both mechanisms, either static or dynamic, can cause impaired perfusion of end organs. Preoperative malperfusion syndrome is associated with high perioperative mortality, up to 43.4%, gradually increasing with the number of organs being malperfused [226]. Besides CT findings, clinical evaluation (e.g. pulse deficit, neurologic dysfunction, abdominal pain, lactate elevation, oliguria) is essential to define further treatment. The presence of femoral pulses assures that blood is flowing down the entire length of the aorta. Clinical assessment must not be forgotten or neglected in the current high-tech imaging climate. Specifically, on CT imaging, the true lumen may be reduced to a small size; but, if femoral pulses are preserved, blood is flowing (via fenestrations) despite the small true lumen. In these times of modern hybrid operating room suites, on-site imaging can enable exact diagnosis of malperfused organs and enhance selection of an optimal treatment algorithm [227].

Mesenteric malperfusion is a devastating complication associated with an almost 5-fold increased risk of perioperative death [228]. Given the dismal outcome after traditional repair, alternative approaches incorporating visceral revascularization prior to open aortic repair have emerged. A revascularization-first approach using endovascular fenestration or stenting is associated with lower in-hospital mortality and may be considered in patients with radiographic and clinical evidence of mesenteric malperfusion [229, 230]. Such a course risks the most serious complication of type A dissection during the time of addressing the visceral malperfusion: intrapericardial rupture of the dissection. Many individual surgeons are strongly in favour of immediate replacement of the ascending aorta (which usually, but not always, corrects the intestinal malperfusion). A growing minority favour the intestinal reperfusion-first approach. There is no right or wrong answer to this quandary. Therefore, addressing visceral malperfusion by an endovascular-first approach can be justified in haemodynamically stable patients.

Coronary malperfusion represents another dreaded complication of acute type A dissection, associated with mortality up to 40% [231]. In 2001 a classification of different types of coronary compromise by aortic dissection (Neri A–C) was presented, which has recently been modified by the addition of 'coronary orifice intimal tear' [232, 233]. In patients with circumferential detachment or complete avulsion of the coronary artery, coronary

artery bypass grafting appears to be the most suitable treatment to restore adequate blood flow and improve coronary ischaemia [233, 234].

Propagation of the dissection into the supra-aortic vessels, peripheral embolization or haemodynamic compromise can lead to impaired cerebral perfusion and preoperative neurologic dysfunction. Optimal timing of surgical repair in patients with cerebral malperfusion from acute type A dissection is still under debate [235, 236]. In patients with preoperative neurologic injury (except haemorrhagic stroke), emergency aortic repair is generally favoured over conservative treatment [58, 215, 216, 237]. In case of completed or haemorrhagic stroke (longer duration from onset of dissection) immediate aortic surgery may be unwise and unrewarding. In case of paraplegia due to spinal cord ischaemia, cerebrospinal fluid (CSF) drainage should be considered as the patient is prepared for ascending aortic replacement.

Despite organ malperfusion ATAAD might be associated with acute aortic regurgitation or cardiac tamponade. Especially malperfusion and cardiac tamponade including shock increase surgical mortality [100, 238]. Therefore, operative risk has to be weighted against the expected outcomes. Immediate surgical treatment inevitably is able to solve both cardiac tamponade and severe aortic regurgitation. In case of cardiac tamponade opening the pericardium before peripheral cannulation or drainage in centres without an on site cardiac surgery department is justified if it does not delay transport and the patient haemodynamic condition is critically compromised. Nevertheless, in cases of resuscitation based on assumed severe tamponade without improvement after opening the pericardium, outcomes are substantially impaired.

**Surgical management.** As has been well documented over the last 5 decades, patients with type A aortic dissection will benefit from urgent surgical repair with resection of the proximal pathology and primary entry tear [239, 240]; due to the unpredictable behaviour of the dissected aorta (in particular in the vicinity of the aortic valve, coronary arteries and supra-aortic branches), swift repair is warranted, considering a mortality risk of 0.5% per hour while waiting for surgery [223]. The extent of surgical repair ranges from supracoronary interposition grafting and valve-sparing root replacement to full resection of the ascending aorta and the arch, including partial arch replacement with arch

debranching techniques and TAR using the FET. All techniques are governed by various factors including the extent of the dissection, the location of major entries, the local surgical expertise and the age and comorbidity of any given patient. To date no solid data exist comparing various strategies, but an individualized strategy preferentially in high-volume ACs seems promising.

In patients undergoing surgical aortic repair, the axillary artery should be used for arterial inflow; lower body hypothermic circulatory arrest in combination with antegrade cerebral perfusion and an open distal anastomosis obtains favourable outcomes [217, 220, 221]. In addition, a tear-oriented approach, consisting of resection or exclusion of the primary entry tear, is recommended [213, 214, 221]. Inspection of the proximal descending aorta during hypothermic circulatory arrest should be considered. In case of entry tears in the distal arch or proximal descending aorta, implantation of an FET may be considered [241]. As an alternative, post-surgical TEVAR may be considered for entry tear coverage and optimization of true lumen perfusion [136].

The combination of these 3 concepts (axillary perfusion, circulatory arrest with cerebral perfusion and evaluation/treatment of the descending aorta) enhances true lumen perfusion, encourages thrombosis of the false lumen and reduces the risk of late aortic complications or reoperations. The suggested extent of treatment for type A aortic dissection is illustrated in Fig. 11.

#### Recommendation Table 6: Acute aortic diseases: non-A non-B aortic dissection

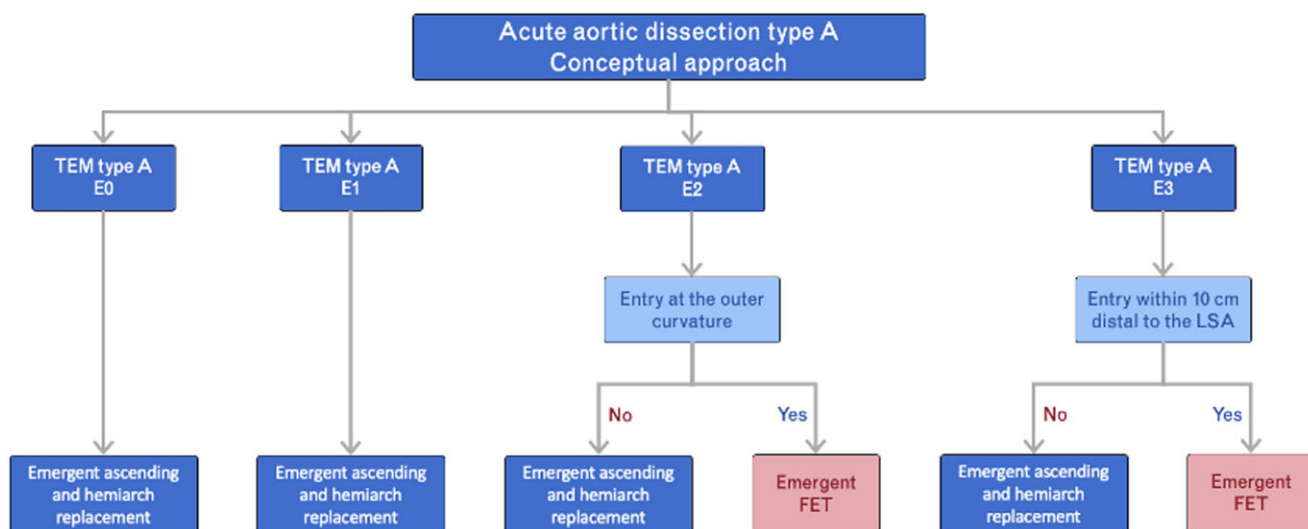
Recommendations	Class <sup>a</sup>	Level <sup>b</sup>	Ref <sup>c</sup>
In patients with complicated non-A non-B aortic dissection with arch entry tear, repair via the FET technique should be considered.	IIa	C	-
In patients with anatomical feasibility to cover the primary entry tear, a stent graft implantation may be considered.	IIb	C	-

<sup>a</sup>Class of recommendation.

<sup>b</sup>Level of evidence.

<sup>c</sup>References.

FET: frozen elephant trunk.



**Figure 11:** Extent of treatment for acute type A aortic dissection. E0, no entry visible; E1, ascending entry; E2, arch entry; E3 descending entry; FET: frozen elephant trunk; LSA: left subclavian artery; TEM: type, entry, malperfusion.

**Non-A non-B aortic dissection.**

The combination of an intimal disruption in the aortic arch and descending aorta in the absence of dissected ascending aorta has not been considered in the Stanford or DeBakey classification in the past. The new SVS/STS classification describes TBAD as any aortic dissection with an entry tear in zone 1 or more distally [42]. Accordingly, the Stanford classification of this specific but rare dissection pattern has been described as non-A non-B dissection by various authors. Conservative treatment was associated with high mortality due to malperfusion and aortic rupture in early series, paving the way towards surgical and endovascular therapy within 14 days after onset of symptoms [48, 50].

Currently available outcomes data on the subset of non-A non-B dissection are scarce. Early reports seem to favour open surgical resection of the entry tear in the arch analogous to the management of type A dissection with the idea to depressurize and exclude the false lumen from proximal inflow and subsequent expansion under the systolic pressure head. Conversely, medically managed patients tend to reveal progressive enlargement, rupture or the need for late extensive replacement surgery [48, 242]. In fact, the largest worldwide registry reported sobering outcomes of non-A non-B dissection with 19% of those patients undergoing either open arch replacement with a mortality of 31%, or an endovascular approach in 25% of cases with a mortality of 14.3%, which is similar to the 13.9% mortality with medical management in the majority (>50%) of patients;

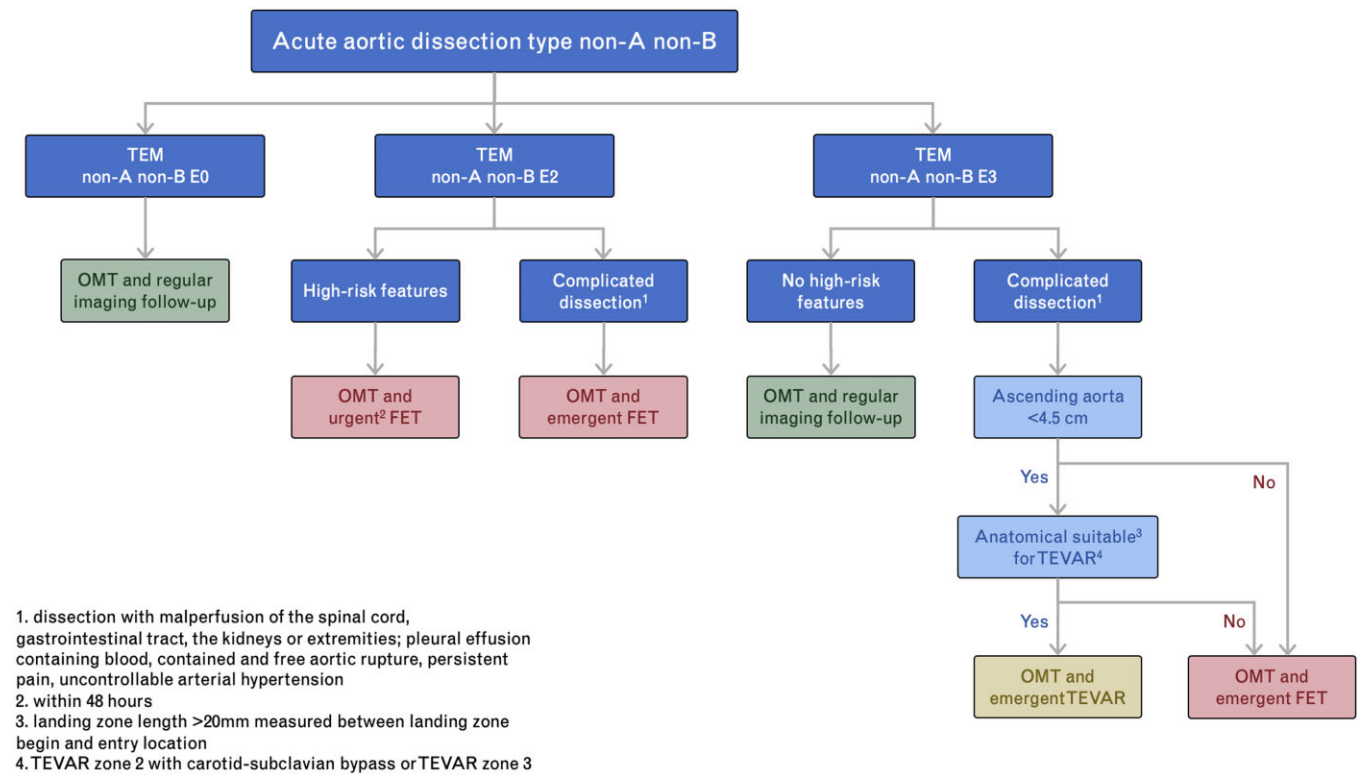
the most frequent complication regardless of management was stroke [242].

More recent experience in 39 patients over 20 years advocated either a hybrid endovascular approach (with associated vascular debranching or bypass surgery), which was still associated with 27% overall mortality, or full arch replacement with an FET in selected younger patients [72].

Similarly, a report from China with 79 patients over 10 years of open surgical arch replacement and FET revealed an operative mortality of 5.1% and severe neurologic events (stroke/paraplegia) in 6.3%, but a 1-year survival of 82.3% [243].

In view of the complexity of arch replacement surgery with the associated FET or even staged debranching and endovascular interventions, new strategies are emerging. A modified surgical technique that includes sealing the entry tear with sutures and/or using a scalloped (fenestrations to preserve flow to the supra-aortic vessels) stent graft inserted antegrade via a median sternotomy supposedly avoids debranching or an ET in 28 patients, with no intraoperative deaths and low mid-term morbidity and mortality [244].

On the aggregate, there is currently no consensus regarding the best management of acute or subacute non-A non-B aortic dissection; simplified and less traumatic hybrid surgical/endovascular approaches are emerging and may have an edge over complex and complete arch replacement strategies. Treatment recommendations for non-A non-B aortic dissection are illustrated in Fig. 12.



**Figure 12:** Treatment strategy for non-A non-B aortic dissection. E0: no entry visible; E2: arch entry; E3: descending entry; FET: frozen elephant trunk; LSA: left subclavian artery; OMT: optimal medical therapy; TEM: type, entry, malperfusion; TEVAR: thoracic endovascular aortic repair.

Depending on the anatomical features and location of the primary entry tear, an FET or stent graft implant, including complex branched grafts, is justified [72, 245, 246]. During the mid-term follow-up, the FET appears superior to endovascular treatment in terms of survival and reintervention rates [247, 248].

### Recommendation Table 7: Acute aortic diseases: type B aortic dissection

Recommendations	Class <sup>a</sup>	Level <sup>b</sup>	Ref <sup>c</sup>
In patients with complicated acute type B aortic dissection and suitable anatomy, TEVAR is recommended.	I	B	[249–253]
In patients with acute complicated type B aortic dissection with unsuitable anatomy for TEVAR, FET repair should be considered.	IIa	B	[254, 255]
In acute type B aortic dissection with high-risk features, TEVAR should be considered in the subacute phase.	IIa	C	-
In patients with acute type B aortic dissection without high-risk features, optimal medical therapy, close monitoring and follow-up is recommended for emerging high-risk features.	I	B	[256, 257]

<sup>a</sup>Class of recommendation.

<sup>b</sup>Level of evidence.

<sup>c</sup>References.

FET: frozen elephant trunk; TEVAR: thoracic endovascular aortic repair.

### Type B aortic dissections.

Acute type B aortic dissection accounts for 30–38% of all aortic dissections [29, 211, 258]. Overall, in-hospital mortality of acute TBAD has not changed over the last 2 decades. The International Registry of Acute Aortic Dissection database reported a mortality rate of 14.1% in patients with acute type B dissection presenting between 2010 and 2013 [211]. In contrast to type A aortic dissection, clinical presentation and radiological features directly affect the treatment algorithm. The identification of high-risk features is mandatory for the optimal choice between medical, interventional or surgical repair.

Several risk factors are known to have the potential to destabilize the course of dissection with subacute and late complications, such as the anatomical location of the primary entry tear at the inner curvature or proximity to the LSA, both facilitating the development of malperfusion or retrograde dissection [259–262]. Furthermore, a proximal entry tear with a defect dimension of 10 or more mm and a high systolic antegrade flow volume in the false lumen with significant diastolic retrograde flow assessed by MRI is a predictor for rapid aortic growth or even rupture [261, 263]. Finally, an initial descending aorta diameter of >40 mm and a false lumen diameter >22 mm are risk factors for aortic diameter increase and aneurysm formation [264, 265]. Therefore, patients with high-risk features may benefit from best medical therapy (BMT) together with endovascular stent graft treatment in the subacute phase. Table 3 summarizes high-risk features in acute TBAD.

Cases of acute TBAD and clinical or CT signs of rupture, immediate malperfusion or high-risk features are candidates for immediate endovascular treatment. In the absence of the previously

**Table 3:** High-risk features in acute type B aortic dissection

Morphologic criteria
Primary entry >10 mm [261, 264]
Primary entry at the inner curvature [264]
Primary entry located <20 mm in relation to the left subclavian artery [261]
False lumen diameter >22 mm [264, 265]
Descending thoracic aortic diameter >40 mm [261, 264]
High systolic antegrade flow volume in the false lumen with significant diastolic retrograde flow assessed by MRI [263]
Clinical criteria
Persistent pain [266, 267]
Uncontrollable HTA [266, 267]

HTA: hypertension arterialis; MRI: magnetic resonance imaging.

mentioned signs, careful monitoring and initial medical management are justified [256, 257]. However, these symptoms represent a complex, dynamic disease requiring optimal medical therapy and close monitoring in order to detect early progression of the disease [268]. In a small RCT of 61 patients (ADSORB trial), early mortality did not differ between BMT and patients undergoing TEVAR in addition to BMT, but cross-over to TEVAR was necessary due to the progression of the disease. Patients undergoing TEVAR had better outcomes in terms of aortic remodelling [251]. Recent data on a larger cohort of patients with TBAD in the subacute phase revealed lower 30-day mortality in patients undergoing early TEVAR in contrast to optimal therapy alone but no difference in 5-year outcomes [269]. In the INSTEAD-XL trial, TEVAR in addition to BMT showed improved 5-year aorta-specific survival and delayed disease progression [249]. In order to better assess the risk of the malignant natural course with late aortic events or the need for intervention in type B dissection, high-risk features or predictors have been identified [262, 264, 270, 271]. The Registry of Aortic Diseases of Model Adverse Events and Progression (ROADMAP) will further help to validate risk prediction of TBAD [272]. Based on the promising data on TEVAR in type B dissection without high-risk features and the better risk assessment by respecting high-risk features, TEVAR might be considered in those patients with suitable anatomy.

In acute complicated TBAD with aortic rupture or malperfusion, TEVAR has proven beneficial over medical therapy and open descending aortic replacement [252, 253]. Endovascular repair can cover the primary entry tear and control of rupture in a timely fashion, but it can also restore true lumen flow and eventually improve remodelling [273, 274]. In patients with malperfusion with mainly static obstruction of a branch vessel, additional branch stenting might become necessary [275, 276]. Due to its favourable outcome, TEVAR has emerged as a first-line treatment in patients with acute complicated type B dissection and suitable anatomy but it still carries a small risk of periprocedural neurologic events and distal stent graft-induced new entries [277, 278].

The Global Registry for Endovascular Aortic Treatment (GREAT) showed a low 30-day mortality and low risk of perioperative complications in early TEVAR in a real-world acute TBAD with or without risk features [279].

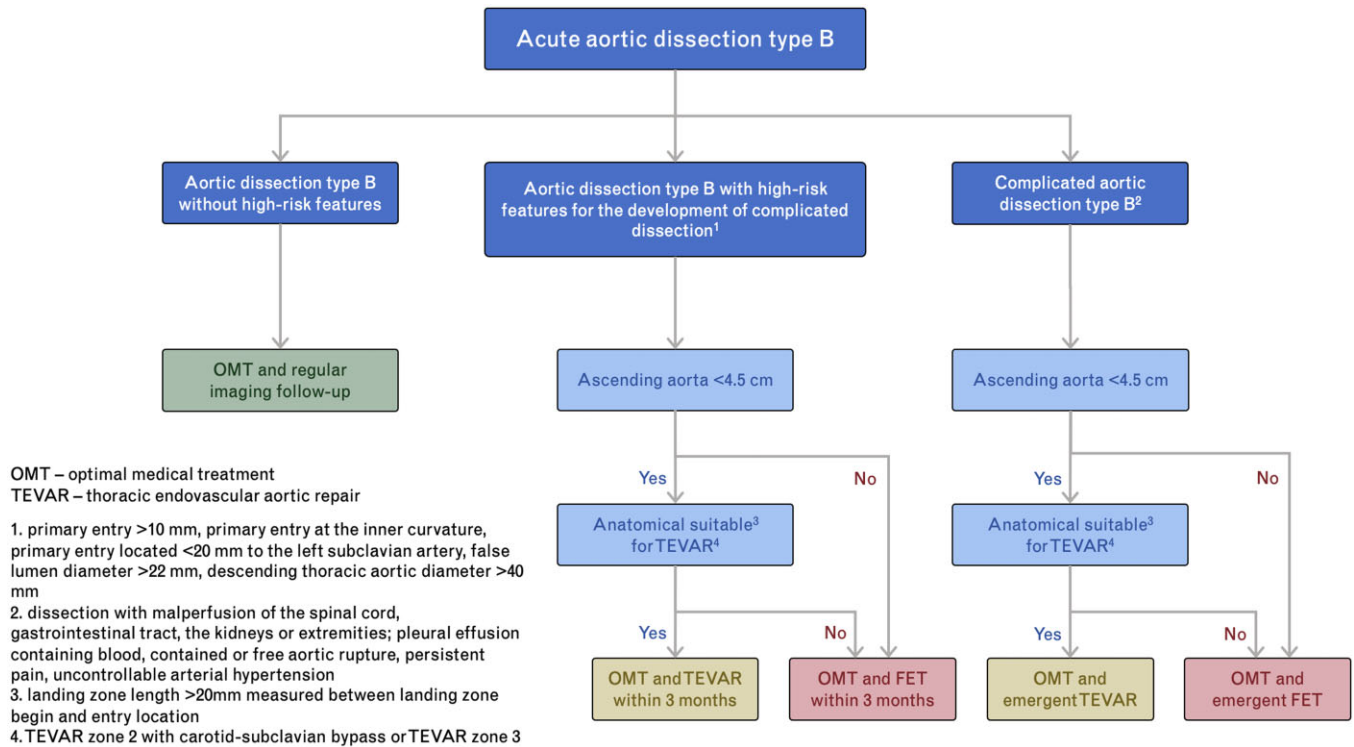


Figure 13: Treatment strategy for type B aortic dissection. FET: frozen elephant trunk; LSA: left subclavian artery; TEM: type, entry, malperfusion.

However, not all patients with complicated or high-risk features of TBAD are suitable for a TEVAR implant. The effective treatment option in these patients may be an open surgical arch replacement with the associated insertion of a frozen elephant trunk. This strategy may be considered for patients with a large ascending aorta or aortic arch, retrograde extension of a type B dissection and lack of an adequate landing zone for an endovascular intervention and for patients with connective tissue disorders [247, 254, 255, 280].

In patients with unsuitable anatomy for endovascular repair, open surgery using the FET technique or open descending replacement remains an option in highly experienced centres [247, 281]. Treatment recommendations for TBAD are illustrated in Fig. 13.

**Intramural haematoma.** Intramural haematoma is characterized by a localized haemorrhage within the aortic wall of >5 mm and may occur with or without intimal disruption [282]. Rupture of vasa vasorum, PAU, or trauma are considered as the leading pathomechanism for IMH. Based on improved imaging technologies with high-resolution CT scans and clinical experience, there is growing evidence that localized intimal disruption, classified as an ulcer-like projection, may cause IMH over time as the intimal disruption occurs progressively [283, 284]. However, there are other explanations that ulcer-like projection (ULP) may be caused by IMH over time as intimal disruption may occur in the acute or subacute phase, progressively and ULP appears after focal intimal disruption of IMH [285, 286]. The ulcer-like projection can be detected as a focal contrast enhancement within the IMH and have communication with the aortic lumen without any evidence of atherosclerosis or local calcification. The IMH is predominantly located in the descending aorta (60–70%)—type B IMH—rather than in the ascending aorta (30%)—type A IMH—or aortic arch (10%) [287].

Type A intramural haematoma.

Recommendation Table 8: Acute aortic diseases: type A intramural haematoma

Recommendations	Class <sup>a</sup>	Level <sup>b</sup>	Ref <sup>c</sup>
In patients with acute type A IMH with complications or high-risk features, emergency surgery is recommended.	I	B	[283, 287–290]
Optimal medical therapies and serial imaging may be considered in patients with type A IMH in the absence of high-risk features.	IIb	C	-
In selected patients with acute type A IMH without high-risk features but a tear in the descending aorta, TEVAR may be considered in addition to OMT in specialized centres.	IIb	C	-

<sup>a</sup>Class of recommendation.

<sup>b</sup>Level of evidence.

<sup>c</sup>References.

IMH: intramural haematoma; OMT: optimal medical therapies; TEVAR: thoracic endovascular aortic repair.

Acute type A IMH can present as a life-threatening condition. Due to the propagation of the haematoma within the aortic wall, aortic events within the first 7 days are frequent. Type A IMH evolves into type A aortic dissection in 33–40% or even to rupture in up to 18% at hospital admission [283, 288, 289]. In the presence of complications, such as malperfusion and rupture, urgent surgery is recommended, equal to that for type A aortic dissection.

**Table 4:** High-risk features in intramural haematomas

Age >70 years [293, 294]
Initial aortic diameter >45 mm [293, 295]
Mean aortic diameter growth rate $\geq$ 5 mm/year [296]
Wall thickness of involved segment $\geq$ 10 mm [297]
Pleural effusion based on Hounsfield units [298, 299]
Presence of aortic ulcer or ulcer-like projection [294, 300]

Further risk factors for a malignant course of type A IMH have been identified based on imaging data and clinical series, and a score for better risk assessment has recently been proposed [291, 292]. Given the high mortality of patients presenting with high-risk features, emergency surgical repair is superior to medical therapy alone [290]. Table 4 summarizes the high-risk features in IMH.

In patients without high-risk features, optimal medical therapy can help to stabilize the patients [301]. Close imaging follow-up is mandatory in these patients to detect early progression and re-evaluate the conservative treatment approach on an individual basis. The literature reveals a high rate of 30–40% for progression to surgical repair or interventions after initial conservative therapy [289, 302]. Progression to aortic dissection or to increasing aortic diameter as well as growing haematoma thickness needs to be addressed with swift surgical repair.

In patients with acute type A IMH from a defined tear in the descending aorta or even type B dissection, TEVAR has been reported in small clinical series as a therapeutic alternative to open surgery or medical therapy alone [303]. In selected patients with ascending diameters <50 mm and IMH thickness <10 mm, TEVAR was associated with a 5-year survival rate of 98% [304]. Because larger comparative studies are lacking, this treatment strategy remains controversial and has to be weighed carefully on an individual basis in selected patients.

#### Type B intramural haematoma.

**Recommendation Table 9: Acute aortic diseases: type B intramural haematoma**

Recommendations	Class <sup>a</sup>	Level <sup>b</sup>	Ref <sup>c</sup>
In patients with acute complicated type B IMH, urgent aortic repair is recommended.	I	B	[305]
In patients with acute type B IMH with high-risk features, TEVAR should be considered if the patient is anatomically suitable.	IIa	C	-
In patients with acute type B IMH without high-risk features, OMT and serial imaging are recommended.	I	B	[305, 306]
In patients with acute type B IMH without high-risk features, OMT, close monitoring and follow-up are recommended.	I	C	-

<sup>a</sup>Class of recommendation.

<sup>b</sup>Level of evidence.

<sup>c</sup>References.

IMH: intramural haematoma; OMT: optimal medical therapies; TEVAR: thoracic endovascular aortic repair.

In 2015, an interdisciplinary expert consensus on IMH type B was launched, pointing out the natural course of the disease and different treatment pathways [305]. In general, the natural course of type B IMH is more benign than an IMH located in the ascending aorta. In patients with acute complicated type B IMH, urgent aortic repair is indicated. Open surgical repair has been replaced by TEVAR in most cases due to its lower perioperative mortality and morbidity. However, the success of an endovascular approach relies on important anatomical factors like favourable landing zones in healthy aortic tissue, left subclavian perfusion, access vessels and optimal sizing of the graft. In patients with unsuitable anatomy, open surgery should be performed [305].

In the absence of complications, medical management is recommended in the initial phase. Similar to type A IMH, evaluation of high-risk features for a malignant progression of the disease is of utmost importance.

Type B IMH can show a very dynamic course leading to a high rate of adverse aortic events mainly within 1 month after initial medical therapy [296, 306]. The topics of indication for prophylactic intervention in patients with type B IMH and of the best timing for treatment after initial medical therapy are still under debate [307]. In a meta-analysis comparing medical management to TEVAR, endovascular repair was applied more frequently in patients with complicating features and was associated with a lower rate of aortic dissection or rupture during the follow-up period. Despite these differences in presentation, TEVAR was not associated with a lower rate of aortic death or a higher rate of haematoma regression during 37 months of follow-up [308]. In a smaller series on the timing of TEVAR, delayed TEVAR (median 5.5 days) was associated with fewer aortic-related events and fewer deaths [309]. Open descending aortic replacement should also be regarded as an alternative for the treatment of type B IMH, especially in cases of vasa vasorum rupture because pain relief in this setting is debatable after TEVAR.

#### Penetrating atherosclerotic ulcer.

**Recommendation Table 10: Acute aortic diseases: penetrating atherosclerotic ulcer**

Recommendations	Class <sup>a</sup>	Level <sup>b</sup>	Ref <sup>c</sup>
In patients with PAUs in the ascending aorta and the presence of IMH or rupture, urgent aortic repair is recommended.	I	B	[289]
In patients with high-risk PAUs located in the distal arch or descending aorta, TEVAR should be considered if anatomically suitable.	IIa	B	[310]
In patients with high-risk PAUs located in the distal arch or descending aorta unsuitable for TEVAR, open surgical repair should be considered after careful evaluation of operative risk.	IIa	B	[311]

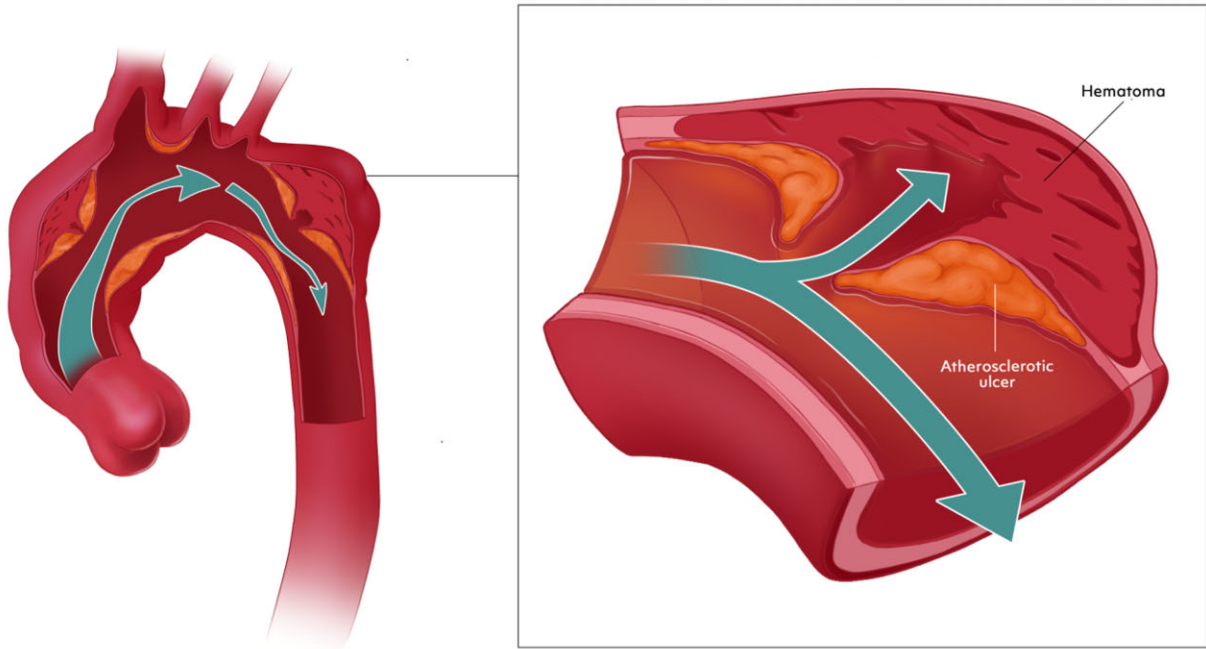
<sup>a</sup>Class of recommendation.

<sup>b</sup>Level of evidence.

<sup>c</sup>References.

IMH: intramural haematoma; PAU: penetrating aortic ulceration; TEVAR: thoracic endovascular aortic repair.

## Penetrating Atherosclerotic Ulcer (PAU)



**Figure 14:** Penetrating atherosclerotic ulcer.

Penetrating atherosclerotic ulcerations are defined as atherosclerotic lesions within the aortic wall originating from the intima and progressing into the media (Fig. 14).

Based on the underlying disease, patients with PAUs carry a high atherosclerotic burden, are often of advanced age and present with other comorbidities. Behind this clinical background, procedural risk of endovascular or open surgery should be weighed against frailty, comorbidities and life expectancy in this patient cohort.

The clinical presentation and the anatomical features guide the way towards different treatment strategies. Most PAUs are asymptomatic and are detected as incidental findings during imaging for other indications; they are located predominantly in the descending aorta [310, 312].

Due to the ulcerative and degenerative nature of the disease, PAUs can be associated with localized IMH and carry a high risk of progression into aortic dissection or rupture, especially if located in the ascending aorta [289]. Therefore, symptomatic PAUs or PAUs with high-risk features located in the ascending aorta should undergo urgent surgical repair.

In patients with PAUs distal to zone 0, the treatment algorithm depends on the presence of complications—rupture, IMH or aortic dissection, persistent pain or pleural effusion. In addition, high-risk features for malignant courses of any PAU should be evaluated (Table 5) [305].

In high-risk PAUs distal to zone 0, aortic repair should be performed. TEVAR emerged as the first-line therapy in patients with high-risk PAUs in the descending aorta but is limited to specific

**Table 5:** High-risk features in a penetrating atherosclerotic ulcer

<b>Morphologic criteria</b>
Pleural effusion based on Hounsfield units [313, 314]
Presence of IMH [313, 314]
Large initial PAU depth (>10 mm) and diameter (>20 mm) or high growth rate size [313]
<b>Clinical criteria</b>
Persistent pain despite medical treatment [313, 315–317]

IMH: intramural haematoma; PAU: penetrating aortic ulceration.

anatomical features [310]. In patients with anatomy unsuitable for conventional TEVAR of PAUs located in the aortic arch, the FET procedure is a treatment alternative [311]. Recent technical advances of endovascular repair might also emerge as an alternative. In a small clinical series of patients presenting with PAUs with high-risk features, scalloped TEVARs proved a safe alternative as a new tool to address more proximal arch pathologies [318]. Limited data on total endovascular arch repair for PAUs located in zone 1 or 2 or a limited proximal landing zone show high technical success [319, 320]. Larger studies and long-term results are needed to better characterize perioperative complications and the need for re-interventions.

**Blunt traumatic aortic injury.****Recommendation Table 11: Acute aortic diseases: blunt traumatic aortic injury**

Recommendations	Class <sup>a</sup>	Level <sup>b</sup>	Ref <sup>c</sup>
In patients with BTAI grade I, nonoperative management, including close follow-up imaging, is recommended.	I	C	-
In patients with BTAI grade II and high-risk imaging features, TEVAR should be considered.	IIa	C	-
In patients with BTAI grade II without high-risk imaging features, nonoperative management and close follow-up imaging may be considered.	IIb	C	-
In patients with BTAI grades III–IV and suitable anatomy, TEVAR is recommended.	I	C	-

<sup>a</sup>Class of recommendation.

<sup>b</sup>Level of evidence.

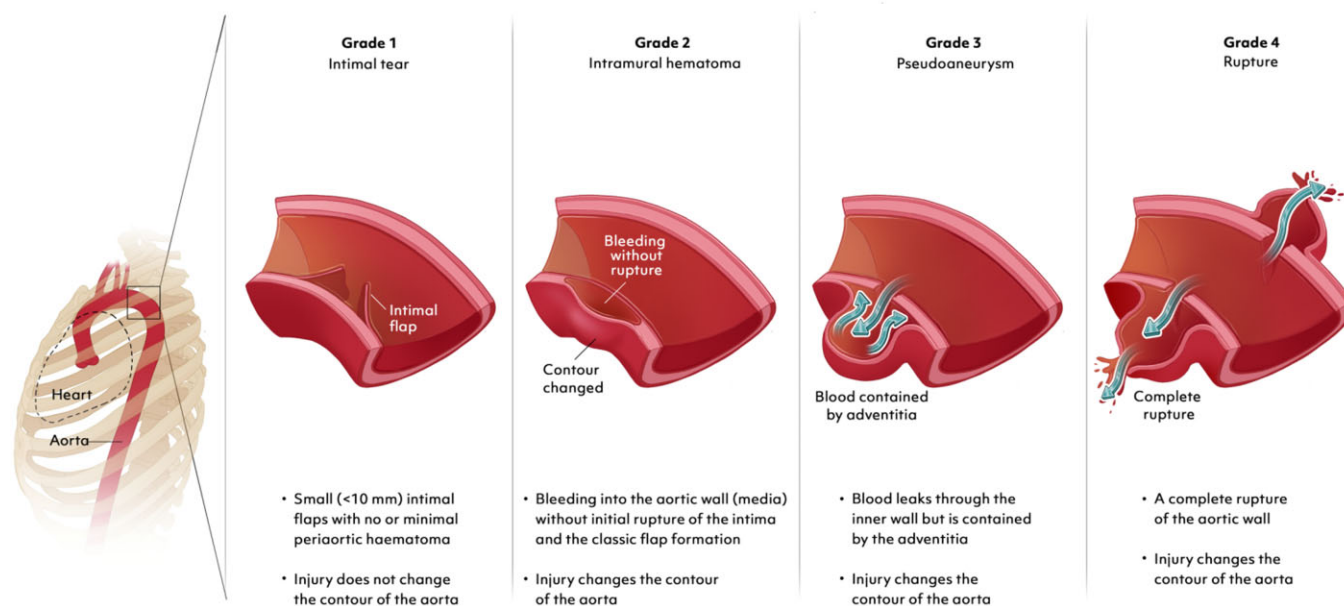
<sup>c</sup>References.

BTAI: blunt thoracic aortic injury; TEVAR: thoracic endovascular aortic repair.

Aortic injuries may be caused acutely following blunt or penetrating traumas. Blunt trauma rapid decelerative events cause rapid motion of aortic segments relative to fixed anatomical points. Blunt thoracic aortic injury (BTAI) usually occurs at the level of the aortic isthmus, less frequently at other levels. BTAI typically affects young males and is associated with high mortality rates before the patient reaches the hospital [141, 282, 321–325]. The following refers to BTAI at the level of the aortic isthmus. BTAI involving the ascending aorta or the aortic arch is

rare and should be treated based on individual decision-making of the aortic team. BTAI classified into 4 grades: grade I: intimal tear; grade II: intramural haematoma; grade III: pseudoaneurysm; grade IV: free rupture (Fig. 15) [322, 323]. Symptoms vary from completely asymptomatic or non-specific pain to haemorrhagic shock, depending on the severity of the lesion. Therefore, physicians should have a high index of suspicion based on the preclinical situation and the type of traumatic event. The clinical evaluation, which is based on the stepwise Advanced Trauma Life Support guidelines, is of primary importance. Evident clinical signs may consist of active bleeding, pulsating or expanding haematoma, puff or thrill over a wound, absence of distal pulses or ischaemia of the extremities (pain, pallor, paralysis, hypothermia). A diagnosis, however, needs to be confirmed on contrast-enhanced CTA imaging.

BTAI management is dependent on lesion severity and thus on the BTAI grading system. Transport to a high-volume specialized trauma centre may be preferred in stable patients to achieve optimal outcomes [326]. Thoracic endovascular aortic repair is the first choice if treatment is indicated and in the presence of suitable anatomy [141]. Grade I BTAI lesions can be managed in a nonoperative manner (e.g. maintaining systolic blood pressure <100 mmHg and heart rate <100 bpm) with close follow-up imaging [141, 323]. Grade II BTAI lesions include both those with and without high-risk imaging features, which consist of posterior mediastinal haematoma >10 mm, lesion-to-normal aortic diameter ratio >1.4, mediastinal haematoma causing mass effect, pseudoocclusion of the aorta; left haemothorax; ascending aorta, aortic arch, or great vessel involvement; or aortic arch haematoma [141, 327–330]. For grade II BTAI lesions that present with high-risk imaging features, TEVAR should be considered the treatment strategy of choice. Conversely, nonoperative management and close follow-up may be preferred for lesions without such high-risk imaging characteristics [331, 332]. Grade III–IV lesions should be managed operatively with TEVAR.

**Classification of blunt traumatic aortic injury**

**Figure 15:** Classification of blunt traumatic aortic injury.

## CHRONIC DILATATIVE AORTIC DISEASE

### Root and ascending aorta

**Recommendation Table 12: Chronic aortic diseases: root and ascending aorta**

Recommendations	Class <sup>a</sup>	Level <sup>b</sup>	Ref <sup>c</sup>
Surgery for an ascending aortic aneurysm located at the root or tubular tract, either with TAV or BAV, is recommended when the maximum aortic diameter is $\geq 55$ mm.	I	B	[333, 334]
Surgery for BAV-related aortopathy with 'root phenotype' is recommended when the maximum aortic diameter is $\geq 50$ mm.	I	B	[82, 84–87, 335]
Surgery for TAV-associated aneurysms with 'root phenotype' should be considered when the maximum aortic diameter is $\geq 50$ mm in a low-surgical-risk setting. <sup>d</sup>	IIa	B	[87, 336–338]
In patients with low surgical risk <sup>e</sup> and 'ascending phenotype' dilatation, both with TAV and BAV, surgical treatment should be considered when the maximum aortic diameter is $> 52$ mm.	IIa	C	-
In patients with low surgical risk and 'ascending phenotype' BAV-related aortopathy, surgery should be considered at a maximum diameter $\geq 50$ mm if any of the following is present: <ul style="list-style-type: none"> <li>• age <math>&lt; 50</math> years</li> <li>• short stature (<math>&lt; 1.69</math> m)<sup>f</sup></li> <li>• ascending aortic length <math>&gt; 11</math> cm<sup>g</sup></li> <li>• aortic diameter growth rate <math>&gt; 3</math> mm/year</li> <li>• family history of the acute aortic syndrome</li> <li>• aortic coarctation</li> <li>• refractory hypertension</li> <li>• shared decision with the patient<sup>h</sup></li> <li>• concomitant non-aortic valve cardiac surgery</li> </ul>	IIa	C	-
In patients with non-syndromic TAV with 'ascending phenotype', in a low-surgical-risk setting, <sup>d</sup> surgery may be considered at a maximum diameter $\geq 50$ mm if any of the following is present: <ul style="list-style-type: none"> <li>• age <math>&lt; 50</math> years</li> <li>• short stature (<math>&lt; 1.69</math> m)<sup>f</sup></li> <li>• ascending aortic length <math>&gt; 11</math> cm<sup>g</sup></li> <li>• aortic diameter growth rate <math>&gt; 3</math> mm/year</li> <li>• refractory hypertension</li> <li>• shared decision with the patient<sup>h</sup></li> </ul>	IIb	C	-
Surgery for aortic dilatation in TAV patients undergoing non-aortic valve cardiac surgery should be considered at a root or ascending diameter $\geq 50$ mm.	IIa	C	-
Surgery for aortic dilatation in patients undergoing aortic valve surgery should be considered at a root or ascending diameter $\geq 45$ mm.	IIa	C	-
Surgery for aortic root dilatation in patients undergoing surgery for ascending aortic aneurysm should be considered at an aortic root diameter $\geq 45$ mm.	IIa	C	-
In patients with young age, a family history of the acute type A aortic dissection or known HTAD who are undergoing ascending replacement, a lower threshold than 45 mm may be considered for concomitant root replacement on an individual basis.	IIb	C	-

<sup>a</sup>Class of recommendation.

<sup>b</sup>Level of evidence.

<sup>c</sup>References.

<sup>d</sup>Based on both individual patient's comorbidities (see footnote e) and the centre's experience with the required surgery [141, 339].

<sup>e</sup>Because the 52.5-/53-mm threshold corresponded to an increase in risk of acute aortic events from  $< 1\%$  to 4–5% [340, 341], a predicted perioperative mortality  $< 3\%$  justifies the surgical indication.

<sup>f</sup>For 1.50-m height, a 50-mm diameter corresponds to 13 cm<sup>2</sup>/m of ascending cross-sectional area-to-height ratio, which is associated with an increase in risk of acute aortic events [341]; for 1.69 m height, 13 cm<sup>2</sup>/m corresponds to 53 mm.

<sup>g</sup>Measured with the centreline method from the aortic annular plane to the brachiocephalic trunk using CTA-scan [196, 336].

<sup>h</sup>Considering the patient's lifestyle, occupation, compliance with medical therapy and surveillance, psychological aspects.

BAV: bicuspid aortic valve; CT: computed tomography; HTAD: heritable thoracic aortic disease; TAV: tricuspid aortic valve.

Among aneurysms of the thoracic aorta, those involving the root, the tubular ascending aorta or both account for  $\sim 60\%$  [342]. Their natural history can vary based on the underlying defect (inherited, sporadic, BAV-related); however, a variably long phase of silent growth is common [mean diameter expansion rates:

0.1–0.3 mm/year in tricuspid aortic valve (TAV)-related non-syndromic forms] [333, 334, 343]; 0.2–0.6 mm/year in BAV-related aortopathy [82, 333, 334, 343], with the rare occurrence of severe AAEs, such as ATAAD or rupture (1–3 per 10 000 patient/year) [333, 344].

To define the optimal timing for an operation in terms of diameter, the risk of complications in the natural history must be weighed against the operative risk: In this respect, important advancements in knowledge, through large observational studies, have taken place in the last decade. The relation between maximum diameter and risk of AAEs has been revised (Fig. 16): (i) The curve indicating this relation actually shows 2 'hinge points', with the first at 52.5 mm [340]; (ii) thresholds have been traditionally extrapolated from the analysis of diameters in dissected aortas; however, predissection aortic tubular tract diameters are 18–32% smaller [196, 337, 345]; (iii) the greater importance of the phenotype of the dilatation over the absolute

diameter has been ascertained [82, 336, 338]. The greater severity of the 'root phenotype' dilatation (root diameter > ascending diameter), with faster progression and higher risk of ATAAD, was initially recognized uniquely for BAV-related aortopathy [82, 87, 339]. Then, in 2 independent large series, 1 BAV and 1 mixed, the 'hinge point' of the ATAAD-risk curve (increasing from 1% to 4–5%) was consistently found at 50 mm for the root diameter and at 52–53 mm for the tubular diameter [336, 341]. The root phenotype, together with short stature, was an independent risk factor for a composite end-point of ATAAD, rupture and aorta-related death [336]. More recently, in patients with purely TAV-associated non-syndromic aortopathy who

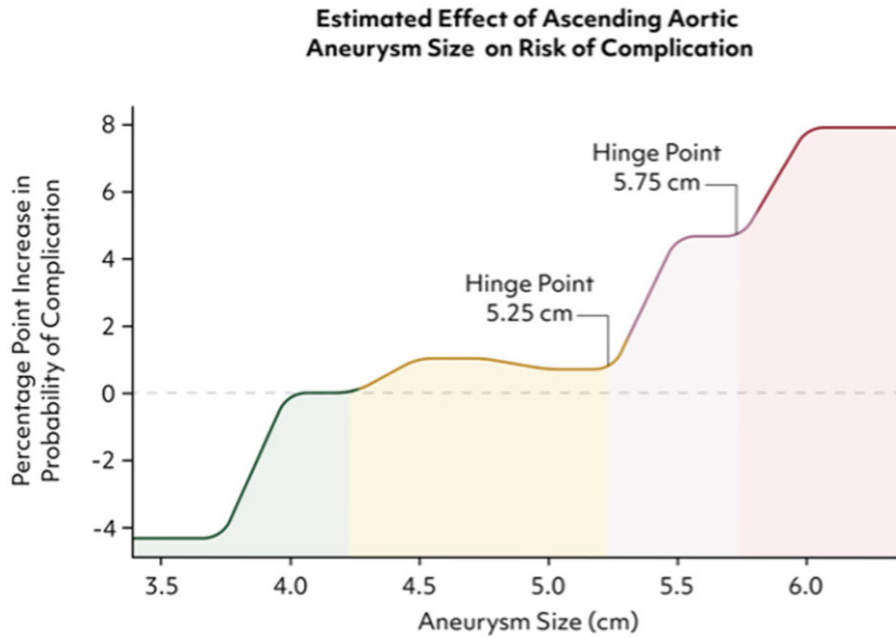


Figure 16: Hinge points for increased risk of size-associated complications.

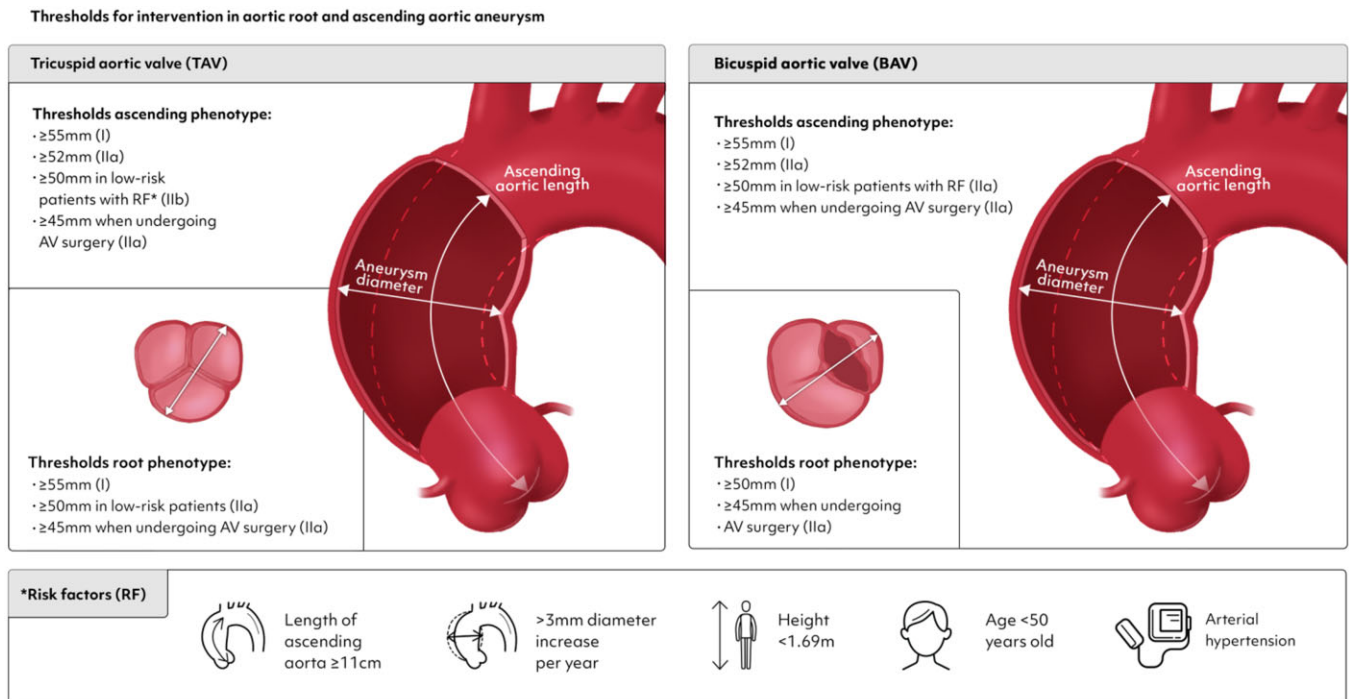


Figure 17: Thresholds for intervention in aortic root and ascending aortic aneurysm. AV: aortic valve.

experienced ATAAD, those with a root phenotype (younger, more frequently male) dissected at significantly smaller diameters than patients with an ascending phenotype [338]. Altogether, the preceding evidence supports lowering the threshold for indication in patients with low surgical risk (both relative to patient's profile and to the centre's experience), at >52 mm for ascending and ≥50 mm for root phenotype. An earlier operation on the root can also increase the chances for a successful valve-sparing approach in centres with consolidated experience in BAV repair [346]. Thresholds for intervention in aortic root and ascending aortic aneurysm are illustrated in Fig. 17.

Of note, reported mortality rates after isolated proximal aortic surgery have been decreasing from around 3% [347] to <1.5% over the last decades (reaching rates as low as 0.25% in large-volume ACs) [102, 336]. Therefore, in patients with a higher risk of AAEs (e.g. BAV plus other risk factors), surgery can be considered at ≥50 mm even for the ascending phenotype: Factors to consider include growth rate, family history, hypertension, younger age, short stature and patient's willingness to be operated on earlier [141, 339] ('recommendations for root and ascending aorta'). It has been emphasized that real rapid growth, as commonly defined, is rarely observed: Measurement errors must be ruled out before indicating earlier surgery based solely on this criterion [14, 348].

New dimensional criteria for risk stratification are emerging [349]: An increased aortic length at centreline, from annulus to brachio-cephalic trunk origin (>11.5 cm), has been found to be associated with an increased risk of AAEs [196]. Some data suggested that the most important component of aortic elongation in determining the risk of ATAAD might be the elongation of the root segment [87], consistent with the greater malignancy of the root phenotype: Further studies are needed.

## Maximum diameter and maximum length

**Recommendation Table 13: Chronic aortic diseases: maximum diameter and maximum length**

Recommendations	Class <sup>a</sup>	Level <sup>b</sup>	Ref <sup>c</sup>
Surgery should be considered for a symptomatic aneurysm of the ascending aorta, almost independently of size (once non-aortic causes have been eliminated).	Ila	C	-
For individuals of small body size, height nomograms should be considered in the decision about indications for surgery at various aortic dimensions.	Ila	B	[340]
An ascending aortic length exceeding 110 mm should be considered as a risk factor for aortic events when indicating elective surgery for aortic aneurysms.	Ila	B	[196]
Despite metrics and precision criteria, the benefits and risks of surgical intervention versus nonoperative management should be considered on a case-by-case basis.	Ila	C	-
Other non-diameter criteria that also bear on the risk of aortic events may be considered in the decision-making.	IIb	C	-

<sup>a</sup>Class of recommendation.

<sup>b</sup>Level of evidence.

<sup>c</sup>References.

Since the inception of aortic surgery by the great pioneers (DeBakey, Cooley, Cabrol, Crawford and others), the aortic dimension that has been associated with the risk of adverse events has been the diameter. The theoretical foundation resides in Laplace's law, which states that wall tension (the force tending to pull the wall apart) is proportional to the intraluminal pressure times the diameter, divided by wall thickness.

Despite established diameter criteria, studies [350] demonstrated that the majority of acute aortic dissections occur at a diameter <55 mm, suggesting that Laplace's law probably applies to the risk of rupture but not to the risk of dissection: Different forces must evidently lead to the 2 different modes of aortic wall acute mechanical failure, transmural rupture versus intimal delamination [351, 352].

In the attempt to obtain better predictions, diameter was once considered in the context of body size by correcting for body surface area [340]. However, to obviate oscillations in weight, correcting the aortic dimension for body height alone was suggested thereafter [340]. This approach is most helpful for individuals of very short or very tall body height, for whom a 'standard' surgical criterion of absolute diameter may not be applicable.

Most recently, aortic length has been confirmed to be a good predictor of aortic risk [196, 349, 353, 354]. Elongation is observed in aortic ageing, but it is abnormally enhanced in aortopathies [353]. The aortic length is measured along the centreline, starting at the aortic annulus and ending at the leading edge of the innominate artery (Fig. 18). As a predictive criterion for dissection, diameter has good specificity but low sensitivity (about 4%), whereas length has shown a 28% sensitivity [354]. Like diameter, length also shows 2 hinge points (Fig. 19); a cut-off of 11 cm has been suggested to prevent AAEs [196]. Typically, intimal tears are perpendicular to the vessel's axis, suggesting that excess longitudinal stress can generate them. As an ascending aorta dilates and/or elongates, it must change its radius of curvature, assuming a C-shape, because the upper and lower ends are fixed. In a proportion of elongated aortas, characterized by root segment elongation, this geometrical change implies over-angulation of the distal portion of the ascending aorta, i.e. narrowing of the angle of the ascending arch. Consistent with other evidence of the greater 'malignancy' of root phenotype dilatations, this pattern has been found uniquely associated with ATAAD [87].

Therefore, in therapeutic planning, the diameter should be considered in the broad context of patient-specific factors including aortic length and angulation, age, sex, family history, genetic variants, and so forth, but also, importantly, aortic pain, i.e. chest pain in a patient with aortopathy without other apparent cause [355].

## Aortic arch

**Recommendation Table 14: Chronic aortic diseases: aortic arch**

Recommendations	Class <sup>a</sup>	Level <sup>b</sup>	Ref <sup>c</sup>
In patients with symptomatic aortic arch pathologies, aortic arch repair is recommended irrespective of diameter.	I	C	-
In patients with asymptomatic isolated aortic arch aneurysms ≥55 mm,	Ila	B	[97]

Continued

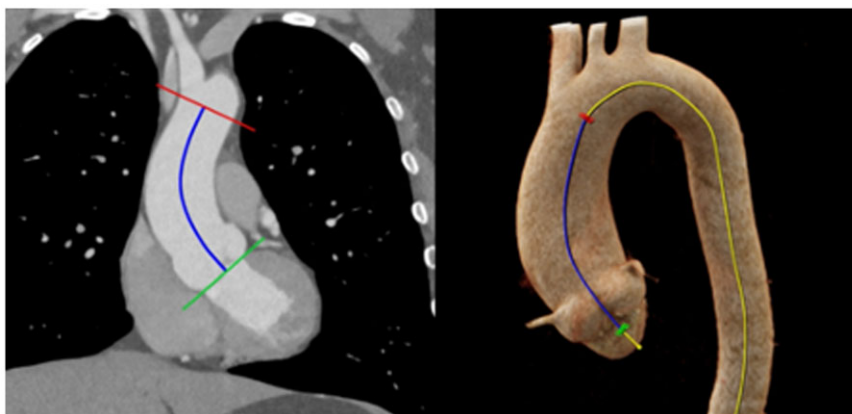


Figure 18: Method for measuring 'aortic length': distance is measured along a centreline from the aortic annulus to the proximal rim of the innominate artery.

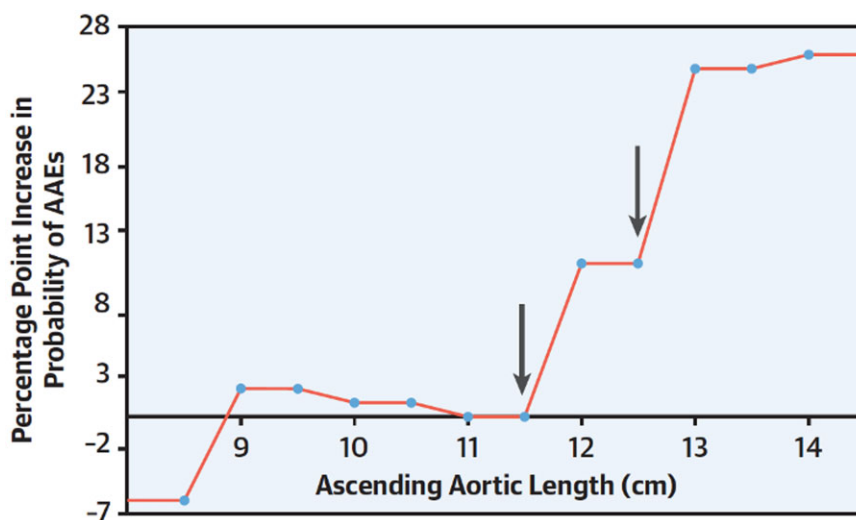


Figure 19: Two hinge points are seen for length as well, just as those that were found earlier for diameter. Reproduced from Wu et al. [196] with permission from Elsevier. AAE: acute aortic event.

aortic repair should be considered.			
In patients with arch pathologies and diseased aortic segments distal to zone 2, FET repair should be considered.	IIa	B	[311, 356-358]
In patients with an indication for aortic repair unsuitable for open surgery, hybrid or endovascular aortic repair may be considered.	IIb	C	-
Hybrid or endovascular aortic repair is recommended to be performed in experienced centres with an adequate volume of both open and endovascular aortic repairs.	I	C	-

<sup>a</sup>Class of recommendation.

<sup>b</sup>Level of evidence.

<sup>c</sup>References.

FET: frozen elephant trunk.

The aortic arch comprises an anatomically limited and, in total, a very short portion of the thoracic aorta, which is defined by the offspring of the supra-aortic vessels. Aortic arch pathologies can be associated with a variety of symptoms other than pain or pressure. Due to the proximity of the aortic arch to important anatomical structures, patients can become symptomatic with dyspnoea in cases of obstruction or displacement of the trachea. If a large aortic mass is compressing the oesophagus or is in association with an aberrant LSA (i.e. a Kommerell diverticulum), patients can suffer from dysphagia. In 5% of patients with aortic arch aneurysms, secondary paralysis of the recurrent nerve (Ortner's syndrome) can be detected [359]. Only 10% of TAAs are located exclusively in the aortic arch [360]. Aortic arch pathologies result more frequently from residual chronic dissection after type A aortic dissection repair. If diseased segments involve the descending aorta in addition to the aortic arch, the FET technique has emerged as a treatment strategy for a combined repair with excellent results [311, 356-358]. If preoperative risk assessment weighs against open aortic repair, hybrid or endovascular aortic repair can be offered by experienced centres as treatment options [136, 319, 320, 361].

## Chronic aortic dissection

**Recommendation Table 15: Chronic aortic diseases: chronic aortic dissection**

Recommendations	Class <sup>a</sup>	Level <sup>b</sup>	Ref <sup>c</sup>
Intervention is recommended in patients with chronic aortic dissection at a maximum aortic diameter of >55 mm without involvement of the ascending aorta.	I	B	[362, 363]
In patients with HTAD with chronic aortic dissection, intervention at diameters <55 mm should be considered if the multidisciplinary aortic team makes the decision depending on the genotype, growth rate, family history and other individual patient risk factors.	IIa	C	-
In patients with dSINE, treatment is recommended to prevent diameter progression.	I	C	-
Intervention at >50 mm should be considered in patients with chronic aortic dissection if the treatment includes a multistep procedure, such as arch replacement with FET followed by TEVAR.	IIa	C	-

<sup>a</sup>Class of recommendation.

<sup>b</sup>Level of evidence.

<sup>c</sup>References.

dSINE: distal stent graft-induced new entry; FET: frozen elephant trunk; HTAD: heritable thoracic aortic disease; TEVAR: thoracic endovascular aortic repair.

Acceptable outcomes of open surgical aortic replacement of the arch or a descending thoracic aneurysm from a chronic aortic dissection are well established [362, 363], with the extent of proximal repair at the time of ATAAD associated with a lower incidence of reoperation [364]. Although TEVAR is a first-line treatment for acute and subacute TBAD, results for TEVAR for chronic TBAD with an aneurysm have been mixed [365]. This outcome is in part due to anatomical changes in the aortic dissection flap that prevent expansion of the true lumen and in part to persistent false lumen flow, whether retrograde from the dissected abdominal aorta or antegrade from arch branch vessels (in the case of residually dissected aorta after type A dissection repair). Aortic remodelling is better in patients with de novo or residual dissections limited to the descending aorta dissection compared to dissections extending to Ishimaru zones more distally, though mortality and morbidity are similar [366].

Several technical advancements have increased the probability of successful endovascular treatment of chronic dissection of the distal arch and the descending thoracic aorta. First, use of the FET technique at the time of acute type A (and in some instances type B) dissection repair would eliminate antegrade flow from arch branch vessels into the false lumen, setting the stage for positive remodelling of at least the proximal descending thoracic aorta. If there is continued aneurysmal degeneration of the descending thoracic aorta in the subacute or chronic stage, completion TEVAR to the level of the coeliac artery can be performed. In the case of chronic TBAD, a favourable proximal landing zone with complete

coverage of the proximal intimal defect would also likely lead to positive aortic remodelling proximally. Second, techniques have been developed to address retrograde false lumen flow that persistently pressurizes the false lumen. Aortic septotomy [367], the Knickerbocker technique [368], the Candy-Plug technique [369] and coil or plug embolization of the false lumen [370] have all been employed with increasing success to promote positive aortic remodelling in chronic dissection.

Larger aortic diameters at the distal landing zone are unfavourable for successful endovascular treatment, and, given current device sizes, the distal descending thoracic aorta should be 40 mm or less to be able to treat the patient with 10–20% oversizing. Although the maximum aortic diameter in the thoracic aorta is usually closely monitored until it has reached the threshold for intervention, attention should also be paid to the total aortic diameter at the coeliac artery, which may already have reached 40 mm or greater before the maximum aortic diameter has reached 55 mm. Current techniques to stage endovascular treatment of the dissected descending thoracic aorta (e.g. FET, then TEVAR with or without adjunctive treatment of the distal landing zone, then false lumen coil/plug) may merit endovascular intervention at a lower maximum diameter threshold to optimize success because the periprocedural risk is low [371].

## Heritable thoracic aortic disease

**Recommendation Table 16: Heritable thoracic aortic disease**

Recommendations	Class <sup>a</sup>	Level <sup>b</sup>	Ref <sup>c</sup>
Genetic testing is recommended in patients with thoracic aortic disease <60 years of age, family history of TAD, arterial aneurysms in other segments and those with syndromic features.	I	B	[169, 372, 373]
Testing of family members is recommended by simpler, more cost-efficient Sanger sequencing of only the suspect genetic area.	I	C	-
<b>Marfan syndrome</b>			
In patients with Marfan syndrome, surgery on the aortic root or ascending aorta is recommended at a diameter of ≥50 mm.	I	B	[374, 375]
In patients with Marfan syndrome and high-risk features,* surgery on the aortic root or ascending aorta should be considered at a diameter of ≥45 mm.	IIa	B	[374, 375]
In patients with Marfan syndrome without high-risk features with a high likelihood of undergoing valve-sparing aortic root replacement and very low surgical risk, surgery on the aortic root or ascending aorta may be considered at a diameter of ≥45 mm when performed by an experienced aortic team.	IIb	C	-
In patients with Marfan syndrome, surgery of the aortic arch, descending thoracic aorta or abdominal aorta should be considered at a diameter of ≥50 mm of the respective aortic segment.	IIa	C	-

Continued

Loeys-Dietz syndrome			
In patients with Loeys-Dietz syndrome, indication for surgery is recommended based on the specific genetic variant, aortic diameter, aortic growth rate, family history, history of aortic events, patient age and other individual patient-related factors and discussed by a multidisciplinary aortic team.	I	C	-
In patients with Loeys-Dietz syndrome attributable to a pathogenic variant in TGFBR1 or TGFBR2, surgery on the aortic root or ascending aorta is recommended at a diameter of $\geq 45$ mm.	I	C	-
In patients with Loeys-Dietz syndrome attributable to a pathogenic variant in TGFBR1 and high-risk features, <sup>a</sup> surgery on the aortic root or ascending aorta may be considered at a diameter of $\geq 40$ mm.	IIb	C	-
In patients with Loeys-Dietz syndrome attributable to a pathogenic variant in TGFBR2 and high-risk features, <sup>a</sup> surgery on the aortic root or ascending aorta should be considered at a diameter of $\geq 40$ mm.	IIa	C	-
In patients with Loeys-Dietz syndrome attributable to a pathogenic variant in TGFBR3, surgery on the aortic root or ascending aorta may be considered at a diameter of $\geq 50$ mm.	IIb	C	-
In patients with Loeys-Dietz syndrome attributable to a pathogenic variant in SMAD3, surgery on the aortic root or ascending aorta should be considered at a diameter of $\geq 45$ mm.	IIa	C	-
In patients with Loeys-Dietz syndrome attributable to a pathogenic variant in TGFBR1, TGFBR2 or SMAD3, surgery to replace the intact aortic arch, descending aorta or abdominal aorta at a diameter of $\geq 45$ mm may be considered.	IIb	C	-
In patients with Loeys-Dietz syndrome attributable to a pathogenic variant in SMAD2 or TGFBR2, surgery on the aortic root or ascending aorta may be considered at a diameter of $\geq 45$ mm.	IIb	C	-

<sup>a</sup>Class of recommendation.

<sup>b</sup>Level of evidence.

<sup>c</sup>References.

\*For Marfan syndrome: family history of aortic dissection; aortic growth  $>0.3$  cm/y; diffuse aortic root and ascending aortic dilation, marked vertebral arterial tortuosity.

#For Loeys-Dietz syndrome: certain specific pathogenic variants (R528H/C in TGFBR2); women with TGFBR2 and small body size; severe extra-aortic features (ie, craniosynostosis, cleft palate, hypertelorism, bifid uvula, marked arterial tortuosity, widened scars, and translucent skin); family history of aortic dissection, especially at young age or aortic diameter  $<4.5$ cm; aortic growth rate  $>0.3$  cm/y.

TAD: thoracic aortic disease.

As genetic investigations have burgeoned in the last decade, more genetically triggered diseases of connective tissue have been identified that promote TAA and dissection. Currently, whereas only 11 genes are officially classified as 'disease causing' by the American

Association of Medical Genetics, a total of 67 genes have been associated with thoracic AD, with varying degrees of evidence [169, 372, 373]. Meanwhile, the term 'connective tissue disorder' has largely been replaced by the term 'heritable thoracic aortic disease' or 'HTAD'. HTAD has largely been adopted as the term of choice by most guidelines, although most of these diseases are associated with aneurysms or dissection of the entire aorta.

Although the number of genes associated with HTADs is steadily increasing, the number of patients carrying these pathogenic variants and the amount of data that is available regarding the natural history of disease vary widely. As of this writing, the clinically most relevant HTADs are Marfan syndrome [374–387], Loeys-Dietz syndrome, vascular Ehlers-Danlos syndrome and Turner syndrome. Although Marfan and vascular Ehlers-Danlos syndromes are associated with pathogenic variants in one gene, FBN-1 and COL3A1, respectively, Loeys-Dietz syndrome has been associated with variants in 6 different genes: TGFBR1 [388], TGFBR2 [389, 390], SMAD2, SMAD3 [390–392], TGFBR2 [393, 394] and TGFBR3 [395, 396]. Phenotypes between these different variants vary, are of clinical importance and impose different thresholds for intervention [397–400].

These syndromes are characterized by structural defects of the connective tissues of the aorta, amid other body tissues and organ systems. It is vitally important for the clinician to be aware that almost all genetically triggered TAAs are inherited in an autosomal dominant fashion, so that a variant contributed by a single parent suffices to induce disease.

It is also remarkable that TAA is largely triggered by a change in just a single genetic 'letter' within the 3.2 billion letters of the genetic code. Compare this disease to other multifactorial diseases, like coronary artery disease, in which at least dozens of genes contribute a small risk component. In TAA, a change in 1 molecular base suffices to produce aneurysm disease on its own merit.

Whereas before we considered all TAAs in one decision-making 'basket', in the present era of accessible, affordable precision genetics, specific aortic behavioural characteristics are being rapidly identified for each genetically triggered TAA type. So, instead of placing all our TAA patients in one basket, patients can now be placed in individual 'baskets' based on the behaviour of those patients with variants in that specific gene. For this reason, we recommend widespread screening by whole exome sequencing. Family members of patients with a positive whole exome sequencing screen can be tested by the simpler, less expensive Sanger sequencing (which reads only a short sequence of the exome containing the variant of interest).

### Non-syndromic heritable thoracic aortic disease.

#### Recommendation Table 17: Chronic aortic diseases: non-syndromic heritable thoracic aortic disease

Recommendations	Class <sup>a</sup>	Level <sup>b</sup>	Ref <sup>c</sup>
In patients with HTAD attributable to a pathogenic variant in ACTA2, surgery on the aortic root or ascending aorta should be performed at a diameter of $\geq 45$ mm.	IIa	C	-
In patients with HTAD attributable to a pathogenic variant in ACTA2 and high-risk features, <sup>a</sup> surgery on the aortic root or ascending aorta may be considered at a diameter of $\geq 42$ mm.	IIb	C	-

Continued

In patients with HTAD attributable to a pathogenic variant in PRKG1, surgery on the aortic root or ascending aorta may be considered at a diameter of $\geq 42$ mm.	IIb	C	-
In patients with HTAD attributable to a pathogenic variant in PRKG1 and high-risk features,* surgery on the aortic root or ascending aorta may be considered at a diameter of $\geq 40$ mm.	IIb	C	-
In patients with HTAD attributable to a pathogenic variant in MYLK or MYH11, surgery on the aortic root or ascending aorta may be considered at a diameter of $\geq 45$ mm.	IIb	C	-

<sup>a</sup>Class of recommendation.

<sup>b</sup>Level of evidence.

<sup>c</sup>References.

\*Family history of type A aortic dissection in the setting of no or minimal aortic dilation, aortic growth rate  $>0.3$  cm/y.

HTAD: heritable thoracic aortic disease.

The number of non-syndromic HTADs is increasing with the number of patients who are screened and the research that is done using next-generation sequencing. The term 'sporadic aneurysm' might be misleading because the patient might still have a heritable form of disease that will affect the next generation but the affected gene has not yet been identified. This thinking is supported because 1 out of 3 of the first-degree relatives from patients without a pathogenic variant also have thoracic AD. Therefore we can never really say whether TAD in a given patient is sporadic or an HTAD, although factors such as age are important indicators. At this point, the most appropriate course of action is to differentiate between those patients in whom a pathogenic variant could be found and those in whom this was not possible. There are a number of genes in which pathogenic variants are associated with a higher risk of dissection than in those without, and different thresholds apply. These recommendations apply to patients with bicuspid as well tricuspid valves.

### Aortic aneurysm in adults with congenital heart disease

Conotruncal defects such as tetralogy of Fallot, truncus arteriosus and transposition of the great arteries are associated with the development of an aortic aneurysm. Several studies from large cohorts and registries have shown that the risk of AAAs is different and considerably lower than in patients with syndromic and non-syndromic HTADs [401, 402]. In a recent study of 2261 patients with conotruncal defects, 52% of the patients presented with an aortic aneurysm. Only 2.5% of patients underwent surgery, and the mean ascending aortic diameter at the time of surgery was  $58 \pm 5$  mm and  $58 \pm 3$  mm at the level of the aortic root. Nevertheless, there was no aortic dissection during 7984 patient-years of follow-up including 184 patients with a known aortic aneurysm prior to pregnancy. Interestingly, the aneurysm growth rate decreased with age, and there was no significant growth after 40 years of age [401]. Because the majority of patients will have undergone multiple operations, and further interventions might be expected, timing of surgery for an aortic aneurysm in these patients to a large extent depends on the progress of the underlying disease. Indication for surgery should be based on careful review of the individual patient by the multidisciplinary aortic team.

### Difference between genotype and phenotype

Correlations of a specific genetic variant with the age at which dissection occurs permit more accurate prediction of risks and timing of surgical intervention. One major difficulty that has come to light is that the majority of suspicious genes are labelled by the geneticist as variants of unknown significance (VUS). Geneticists have strict criteria for labelling a noted variant as 'disease causing'. They use various criteria to determine the pathogenicity of the discovered variant; these criteria include (i) rarity of the variant in the general population [if the variant is not very, very rare (i.e.  $<1/10000$ ), it is not of interest—just too common to be the cause of a somewhat uncommon disease; (ii) preservation in phylogeny: a highly preserved gene is likely to be of great importance [3]; *in silico* prediction: computerized characterization can predict whether a change in a given base [adenine, guanine, cytosine or thymine (A, G, C, T)] is likely to have a marked deleterious impact on reading the entire gene. However, these criteria can be inconclusive. Final determination of pathogenicity can take generations—too long for proper care of a patient under evaluation. Tools are needed to accelerate, in a scientific fashion, the determination of pathogenicity of a VUS. A zebrafish model has recently been reported that may accelerate the determination of pathogenicity [403]. The variant is introduced into the zebrafish model by gene editing techniques. Then, within days, assessment can be made as to whether the zebrafish phenotype of TAA has been induced. Actual dissections in the mutated zebrafish aorta were presented by the group in Liege (unpublished data). This modality is promising but investigational at this stage:

- The most common reading of a variant found using whole exome sequencing is a VUS. The VUS reflects the geneticists' emphasis on scientific accuracy. However, a final determination of 'pathogenicity' can take generations (to verify that phenotype follows the genotype in affected families). This situation poses a dilemma for the clinician charged with the current care of the aneurysmal patient.
- Molecular techniques for rapid assessment of VUS are of scientific interest and may possibly enhance clinical management in the future.

### Descending aorta

#### Recommendation Table 18: Chronic aortic disease: descending aorta

Recommendations	Class <sup>a</sup>	Level <sup>b</sup>	Ref <sup>c</sup>
In patients with asymptomatic descending aortic aneurysms $\geq 55$ mm, aortic repair is recommended.	I	C	-
In patients with asymptomatic descending aortic aneurysms with high-risk features, repair should be considered in diameters $<55$ mm.	IIa	C	-

<sup>a</sup>Class of recommendation.

<sup>b</sup>Level of evidence.

<sup>c</sup>References.

The following important points deserve mention regarding the descending aorta and its distinction from the ascending aorta:

1. The descending aorta originates from a different embryologic layer than the ascending aorta. Whereas the smooth muscle cells

of the ascending aorta derive from the neural crest, those of the descending aorta derive from the mesoderm. This fundamental difference in origin likely underlies other differences in natural history and behaviour of the descending aorta [404].

2. The morphology of aneurysms of the descending aorta differs markedly from that of aneurysms of the ascending aorta. Although the ascending aortic aneurysms are generally smooth in contour, non-calcified, not related to atherosclerosis [97] and free of clot, aneurysms of the descending aorta differ in every one of these parameters: They are irregular in contour, calcified, strongly related to atherosclerosis and full of clot.

Not surprisingly, given these fundamental embryologic and pathological distinctions, the clinical behaviour of aneurysms of the descending aorta is very different from that of the ascending aorta. The ascending aorta generally does not rupture without prior dissection. The descending aorta, on the other hand, ruptures frequently (through areas of atherosclerosis) without antecedent aortic dissection [405].

It is even more challenging to predict the onset of dissection for the descending aorta [406] because dissections of the descending aorta occur essentially as a 'scatter plot' with regard to diameter—even at very small diameters, even below 40 mm. Fortunately, although unpredictable, dissections of the descending aorta rupture only infrequently (<10%) under proper anti-impulse therapy, whereas those of the ascending aorta rupture almost uniformly (acutely or within several days). However, 'rupture' (without dissection) of the descending aorta can be predicted quite well, usually occurring above 60 mm [405]. So, 55–60 mm is an appropriate general criterion for descending aortic intervention.

1. Given its dramatically different embryology, pathophysiology, pathological anatomy and clinical behaviour, the descending aorta requires specific rules of management.
2. In contradistinction to the ascending aorta, the descending aorta often ruptures without dissecting.
3. Because descending aortic dissection occurs frequently at very small diameters (below 50 or even 40 mm), a diameter criterion for prevention of descending dissection is not feasible. Fortunately, a descending dissection is not often lethal.
4. If endovascular treatment is likely to achieve a favourable result in the presence of high-risk features, lower thresholds are reasonable.

### Thoraco-abdominal

#### Recommendation Table 19: Chronic aortic disease: thoraco-abdominal

Recommendations	Class <sup>a</sup>	Level <sup>b</sup>	Ref <sup>c</sup>
In patients with asymptomatic thoraco-abdominal aneurysms ≥55 mm, aortic repair is recommended.	I	C	-
In patients with asymptomatic thoraco-abdominal aneurysms with high-risk features, aortic repair should be considered with diameters <55 mm.	Ila	C	-

<sup>a</sup>Class of recommendation.

<sup>b</sup>Level of evidence.

<sup>c</sup>References.

Despite the term 'thoraco-abdominal aortic aneurysm' (TAA) being highly familiar and resounding throughout the entire community, knowledge regarding the natural history of the

disease is based on a few small series [407, 408]. Recently, a leap in understanding and interpreting the natural disease course has been made [405]. Elucidating growth rates and critical diameters eventually is the most important component besides other morphologic components such as in the root and the ascending AD.

Growth is rather slow and on average 0.19 ± 0.07 cm/year (Fig. 20). The traditional tipping point in the perception of the community has been around 7 cm with regard to the probability of occurrence of AAEs [407, 408].

However, recent data have challenged this perception with regard to diameter as well as with regard to the disease mechanism. Smaller diameters dissect, and larger diameters rupture, with the tipping point for an exponential rise in risk for rupture at 60 mm, indicating that treatment below this tipping point is highly likely to save lives (Fig. 21).

Patients with acute aortic dissection involving the descending aorta show an acute increase in diameter at the time of the index event with a 23% increase in diameter in the proximal thoracic aorta. There is also an increase in aortic length in contrast to the ascending aorta, where no increase in length is observed after the index event [345, 409]. This observation further substantiates

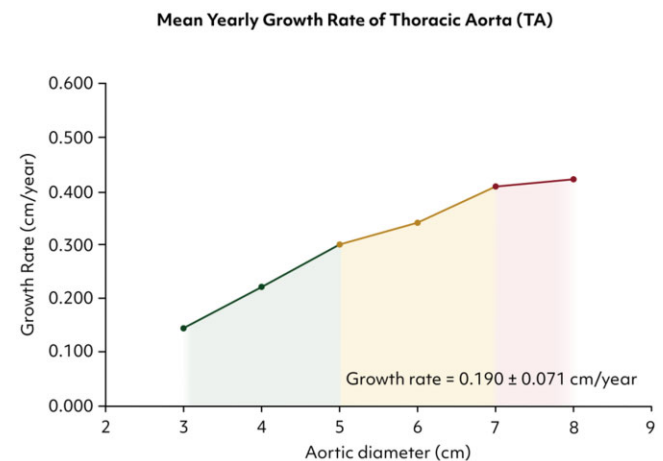
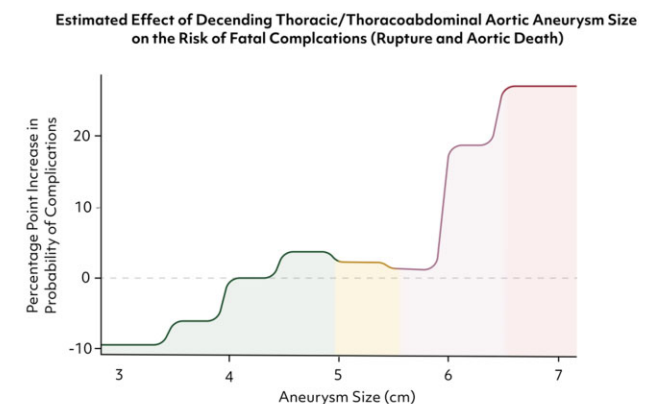


Figure 20: Mean yearly growth rate of the descending thoracic and thoraco-abdominal aorta based on initial aneurysm size.



Probability of rupture or aortic death of the decending thoracic/thoacoabdominal aorta by aneurysm size. Analysis of the predicted probability of fatal complications (ie, rupture or aortic death) revealed that the risk increased sharply at 2 hinge points: 6.00 cm and 6.50 cm.

Figure 21: Hinge points for the risk of fatal complications of thoracic and thoraco-abdominal aortic aneurysm (rupture/death).

the need for the development of knowledge about parameters other than diameter alone for prediction of adverse event rates. Fig. 22 shows that the majority of acute TBADs occurred at aortic diameters below 50 mm.

In analogy to the aortic root and ascending aorta, nomograms have been developed to estimate the yearly risk for death and rupture excluding the risk of aortic dissection.

Finally, the mechanism of aneurysm development does not have any impact on the risk of adverse AAEs; in other words, classical aneurysmal formation or post-dissection aneurysmal formation can be seen as one entity with regard to the risk of aortic rupture at a given diameter.

### Abdominal aorta

#### Recommendation Table 20: Chronic aortic diseases: abdominal aorta

Recommendations	Class <sup>a</sup>	Level <sup>b</sup>	Ref <sup>c</sup>
In patients with ruptured AAA, emergency surgical or endovascular treatment is recommended.	I	C	-
In patients with symptomatic, unruptured AAA, emergency repair is recommended, irrespective of diameter.	I	B	[410, 411]
In patients with asymptomatic AAA, repair is recommended when the AAA exceeds 55 mm.	I	A	[192, 412-420]
In women with asymptomatic AAA, repair should be considered when the AAA exceeds 50 mm.	IIa	C	-
AAA repair should be considered if aneurysm growth exceeds 10 mm/year.	IIa	C	-
In AAA patients with high-risk features, earlier intervention at lower diameters may be considered.	IIb	C	-
In asymptomatic patients with AAA below the threshold for intervention, lifestyle modification, OMT and continuous surveillance are recommended.	I	C	-
In elective patients undergoing AAA repair, preoperative cardiac evaluation is recommended.	I	C	-
In elective patients undergoing AAA repair, preoperative cardiac echocardiography and/or screening for CAD (coronary artery angiography or coronary CTA) may be considered.	IIb	C	-

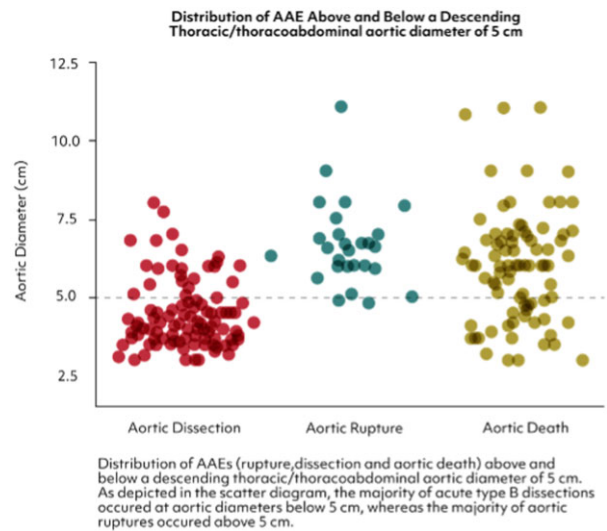
<sup>a</sup>Class of recommendation.

<sup>b</sup>Level of evidence.

<sup>c</sup>References.

AAA: abdominal aortic aneurysm; CAD: coronary artery disease; CTA: computed tomography angiography; OMT: optimal medical therapy.

The most common abdominal AD is an aneurysm, defined as at least a 50% increase in local aortic diameter or >30 mm absolute diameter [10, 421]. Abdominal aortic aneurysms are usually fusiform and up to 4 times more common in men [422]. This section



**Figure 22:** Distribution of adverse event rates (rupture, dissection and aortic death) above and below a descending thoracic/thoraco-abdominal aortic diameter of 50 mm illustrated as a scatter diagram. Reproduced from Zafar et al. [405] with permission from Elsevier.

focuses on atherosclerotic AAA and does not specifically address other abdominal ADs such as mycotic AAA, inflammatory AAA, focal aortic dissection, penetrating aortic ulceration, IMH, pseudoaneurysm or (infected) sacular aneurysm.

Most patients with an abdominal aortic aneurysm are asymptomatic but are exposed to a diameter-dependent risk of aortic rupture [192, 412-417, 423]. Hence, an open surgical or endovascular treatment should be undertaken when the risk of intervention is lower than the risk of rupture, which would cause death when untreated.

Before reaching the threshold for surgical intervention to prevent the risk of rupture, medical therapy should be adopted to reduce aneurysm growth (e.g. WSS and inflammation) to prevent future cardiovascular events (e.g. myocardial infarction) and optimally to prepare a patient for eventual future intervention. Lifestyle interventions such as smoking cessation and stimulation of moderate physical activity remain the cornerstone of treatment, whereas medical therapy may help to achieve normotension and a reduction in cardiac contractility in parallel [418].

Four trials (i.e. ADAM, UKSAT, CAESAR and PIVOTAL) comparing ultrasound surveillance with either open or endovascular intervention have provided an estimate for the rupture risk per year in men, which ranges from 0.3% to 0.8%, and surveillance of AAA <55 mm is supported [419]. In women, however, the risk of rupture may be up to 4 times higher while operative mortality seems to be increased as well, justifying intervention at 50 mm [416, 419, 420, 424]. Linear aneurysm growth is most frequently observed in small AAAs; immediate surgical intervention at a smaller diameter (<42.5 mm), in which rapid aneurysm growth is presumed, seems not always justified [425].

However, in patients with high-risk AAA, earlier intervention may be reasonable [426]. In patients with symptomatic, unruptured AAA, urgent repair is indicated to reduce the risk of rupture [192, 412-417, 423, 426]. In patients with ruptured AAA, emergency surgical or endovascular treatment is indicated [192, 410-417, 423, 426].

Because of the elective and preventive nature of any AAA intervention, stringent prior diagnosis of any comorbidities is recommended to determine the risk of intervention. Aortic

aneurysms of atherosclerotic origin are considered a coronary artery disease equivalent, incorporating a significant risk of cardiac events (>20% in 10 years) [427]. Preoperative cardiac echocardiography and/or screening for coronary artery disease (coronary artery angiography or cardiac CT) might be reasonable.

**Chronic infrarenal obliterative arteriopathy.** Extensive chronic obliterative arteriopathy of the iliac axis and the infrarenal aorta (Leriche's syndrome) is one of the most extensive expressions of atherosclerosis affecting the great vessels [428]. The incidence remains unclear because a few patients will remain asymptomatic due to arterial collaterals developing throughout the disease process. Symptoms usually include claudication on exertion with cramps (hips, thighs and buttocks) as well as absence of femoral pulses. Critical limb ischaemia—due to the usual extensive development of collaterals—is a rare condition in Leriche's syndrome. A detailed clinical history, physical examination and finally imaging are the steps necessary to make a diagnosis. Coronary artery disease is a frequent companion that underlines the necessity of a complete cardiovascular examination in these patients [429].

Therapy, besides an exercise programme and risk factor modifications, usually warrants revascularization; surgical as well as interventional options are available. Surgical results, usually with an aorto-bifemoral Y prosthesis implant, are excellent and should be considered as therapy of first choice in patients with extensive disease patterns such as TASC (Trans-Atlantic Inter-Society Consensus Document on Management of Peripheral Arterial Disease) C and D lesions [430].

The disease can also affect the ostia of the renal and visceral arteries, up to a calcification pattern of a coral reef aorta [431]. These patients can present with renal failure and intractable arterial hypertension in addition to claudication on exertion. Because the clinical picture is rare, the surgical or interventional approaches are heterogeneous, and a standardized recommendation has not yet been postulated. Under these clinical conditions, descending bifemoral bypass grafting with and without synchronous or metachronous visceral and renal revascularization show excellent and durable results [428].

## HOW TO MONITOR END-ORGAN FUNCTION AND HOW TO AVOID END-ORGAN INJURY

**Recommendation Table 21: How to monitor end-organ function and how to avoid end-organ injury**

Recommendations	Class <sup>a</sup>	Level <sup>b</sup>	Ref <sup>c</sup>
<b>Perfusion</b>			
In patients undergoing aortic surgery with involvement of the aortic arch, the preference for antegrade arterial inflow cannulation as compared to retrograde inflow cannulation should be considered.	IIa	B	[218, 219, 432-435]
Axillary artery cannulation should be considered for an antegrade inflow cannulation site for patients undergoing aortic surgery with involvement of the aortic arch.	IIa	B	[218, 219, 432-435]

Continued

Multiple arterial pressure monitoring lines (upper and lower body) are recommended for aortic arch and/or thoraco-abdominal aortic repair. A femoral arterial line is recommended for lower body perfusion-pressure monitoring.	I	C	-
<b>Temperature management</b>			
Nasopharyngeal and core temperature (rectal/bladder) measurements are recommended in patients undergoing aortic arch surgery in lower body HCA.	I	C	-
Considering the core temperature (rectal/bladder) as the reference value for the determination of the level of lower body HCA is recommended.	I	C	-
A target hypothermic circulatory arrest temperature should be determined based on the anticipated extent of repair, expected duration of lower body HCA and presence of pre-operative malperfusion.	IIa	C	-
The use of the term 'mild hypothermia' is recommended for core temperatures >28°C.	I	C	-
The use of the term 'high moderate hypothermia' is recommended for core temperatures between 24.1°C and 28°C.	I	C	-
The use of the term 'low moderate hypothermia' is recommended for core temperatures between 20.1°C and 24°C.	I	C	-
The use of the term 'deep hypothermia' is recommended for core temperatures ≤20°C.	I	C	-
High-moderate lower body HCA in combination with cerebral perfusion for hemiarch replacement is recommended.	I	C	-
High-moderate lower body HCA in combination with selective antegrade cerebral perfusion for complex aortic arch procedures should be considered.	IIa	B	[178]
Target lower body HCA temperature, as well as the cerebral protection method, should be determined based on the anticipated extent of repair, expected duration of lower body HCA and the presence of preoperative malperfusion.	IIa	C	-
<b>Organ protection—heart</b>			
Retrograde cardioplegia should be considered to facilitate repetitive cardioplegia applications without interrupting the procedure.	IIa	C	-
Non-cardioplegic myocardial perfusion may be considered during extended aortic arch repair to reduce myocardial ischaemia time.	IIb	C	-

Continued

Organ protection—brain			
During surgery for aortic arch repair, the use of bilateral NIRS-based cerebral oximetry combined with an algorithmic approach to intervention for cortical Hb-desaturation is recommended.	I	C	-
In a patient with an incomplete circle of Willis diagnosed in preoperative cerebral CTA, trilateral antegrade perfusion should be considered via additional cannulation or intubation of the left subclavian artery.	Ila	C	-
Organ protection—spinal cord			
CSF drainage for spinal cord protection is recommended in open TAAA replacement.	I	B	[436, 437]
CSF drainage should be considered in total aortic arch replacement in patients at risk of SCI.	Ila	C	-
CSF drainage may be considered in type A aortic dissection patients with preoperative symptomatic SCI.	Ilb	C	-
CSF drainage is not recommended as a routine measure in FET procedures if coverage of ICAs is limited due to the operative strategy.	III	C	-
For patients at an increased risk of spinal cord injury undergoing endovascular treatment of thoracic or thoraco-abdominal aortic disease, prophylactic CSF drainage should be considered.	Ila	C	-
The 4-territory concept should be considered during planning to reduce procedure-induced deprivation of antegrade arterial spinal cord supply to a minimum.	Ila	C	-
A critical appraisal of the contribution of thoracic and lumbar segmental arteries to spinal cord perfusion should be considered before surgery to determine the need for reimplantation.	Ila	C	-
Prevention of steal in particular from segmental arteries to avoid SCI is recommended.	I	C	-
Organ protection—visceral and renal			
In patients undergoing aortic arch surgery repair, early reinstatement of distal aortic perfusion should be considered to reduce postoperative visceral, renal and spinal ischaemia.	Ila	B	[438-441]
Selective visceral and renal perfusion is recommended in open TAAA repair	I	B	[442-445]
In TAAA surgery, maintenance of lower limb perfusion to avoid rhabdomyolysis and AKI is recommended.	I	C	-
Deep HCA should be considered in patients undergoing open thoraco-abdominal aorta repair based on surgical and institutional experience.	Ila	C	-

Continued

A period of hypothermic perfusion at the desired target core temperature before hypothermic lower body circulatory arrest should be considered to ensure appropriate thermal distribution throughout the body.	Ila	C	-
A period of hypothermic perfusion before initiation of the rewarming phase should be considered to decrease end-organ injury.	Ila	C	-
Arterial CPB outlet temperature of <37°C during rewarming to avoid hyperthermic perfusion is recommended.	I	C	-

<sup>a</sup>Class of recommendation.

<sup>b</sup>Level of evidence.

<sup>c</sup>References.

AKI: acute kidney injury; CPB: cardiopulmonary bypass; CSF: cerebrospinal fluid; CTA: computed tomography angiography; FET: frozen elephant trunk; Hb: haemoglobin; HCA: hypothermic circulatory arrest; ICA: internal carotid artery; NIRS: near-infrared spectroscopy; SCI: spinal cord injury; TAAA: thoracoabdominal aortic aneurysm.

## Perfusion and cannulation

Surgery on the thoracic aorta may require CPB, systemic hypothermia and/or selective organ perfusion for adequate end-organ perfusion and protection. Isolated surgery on the ascending aorta including the aortic root can be performed during normothermic CPB in cardioplegic arrest. Limited data are also available on normothermic aortic arch replacement without circulatory arrest [438, 440]. This approach requires clamping of the very distal ascending aorta that is left *in situ*. Replacement of the entire tubular ascending aorta is possible with an open distal anastomosis with or without hemiarch replacement. Thereby, the smaller curvature of the aortic arch is also resected with excellent results in elective and emergency scenarios [446-448]. This technique allows a very distal anastomosis but requires a short period of circulatory hypothermic arrest and selective cerebral perfusion. In case of aortic arch surgery, circulatory hypothermic arrest and selective perfusion of supra-aortic vessels are also required.

Several cannulation sites for arterial inflow of CPB have been described and may be classified into antegrade, physiological blood flow and retrograde flow cannulation. Methods for antegrade cannulation include direct cannulation of the ascending aorta, the aortic arch, the innominate artery and the subclavian/axillary or carotid artery. Retrograde flow cannulation is usually conducted by cannulation of the femoral artery.

Retrograde, femoral artery cannulation is quick and easy to establish, particularly for patients in haemodynamic shock. However, it possesses the risk of retrograde malperfusion in patients with aortic dissection or for retrograde embolization possibly causing stroke and a negative effect on early mortality [218, 219, 432].

Hence, antegrade perfusion is the preferred method for CPB inflow, particularly in patients undergoing aortic hemiarch or complete arch replacement. The right axillary/subclavian artery has been the preferred cannulation site and allows relatively simple antegrade selective unilateral cerebral perfusion when clamping the innominate artery. Cannulation of the right axillary/subclavian artery through a side graft has been shown to be superior to direct cannulation via the Seldinger technique [433]. Some centres also use the carotid artery for arterial inflow,

particularly in patients with cerebral malperfusion and type A dissection [434]. However, comparable data are missing, and cannulation usually requires at least partial clamping of the carotid artery with possible negative effects on cerebral perfusion. Innominate artery cannulation is another safe option for antegrade cerebral perfusion [449]. Lastly, good results with routine cannulation of the ascending aorta or the aortic arch during aortic arch surgery have been reported. In patients with type A aortic dissection, this is achieved through TOE-guided Seldinger cannulation of the true lumen [435]. Although the method is quick and has been shown to be safe, this approach requires additional, more complex measurements for cerebral perfusion during the arch procedure. Nevertheless, it is an appropriate option if there is a subclavian or innominate artery dissection and if cannulation of these arteries does not provide adequate CPB flow.

Surgery on the descending aorta, without affection of the aortic arch, can be performed with or without extracorporeal circulation (ECC) in variable degrees of hypothermia. Reports on the risks and benefits of ECC (i.e. left heart bypass) are variable, but there is a trend in favour of ECC and/or selective organ perfusion, because it is associated with improved survival and significantly lower complication rates [450, 451].

## Temperature management in aortic arch surgery

Reconstruction of the aortic arch in circulatory arrest became feasible by the implementation of hypothermia, which reduces the metabolic rate and oxygen demand of the human body and allows surgeons to temporarily stop circulation. The first successful series of aortic arch operations using deep hypothermic circulatory arrest (DHCA) was reported in 1975 by Griep et al. [452]. Since then, the technique has been refined, and additional modifications have been made to improve patient outcomes. Kazui et al. [453] and Bachet et al. [454] introduced antegrade cerebral perfusion during the period of circulatory arrest and the use of more moderate levels of hypothermia. However, the optimal

method of cerebral protection for aortic arch surgery remains controversial, and a consistent global approach is still missing.

**Problem definition.** Reviewing the literature, one is confronted with 3 major problems. First, the method of temperature measurement varies between the individual studies. Some authors measure nasopharyngeal temperature, others use rectal or bladder temperatures, which are defined as core temperatures (Fig. 23). Rectal temperature measurement is more invasive but provides a more accurate measure of core temperature. Bladder temperature measurement can be affected by factors such as bladder volume and catheter placement. Nasopharyngeal temperature reflects most accurately brain temperature but is significantly different from core temperature. A standardized approach to temperature measurement and reporting in future studies is warranted to allow for more accurate comparisons between studies.

Second, the definition of deep, moderate and mild hypothermia varies from study to study.

Third, the period of circulatory arrest varies significantly among the studies. Complex aortic arch reconstruction is associated with arrest times around 60 min, whereas hemiarch replacement can be performed within arrest times of 20–30 min. This fact has an enormous impact on the evaluation of different cerebral protection methods.

**Definitions of profound, deep, moderate and mild hypothermia.** In a consensus paper published in 2013, a classification of different ranges of hypothermia was proposed based on the belief that brain metabolism is the key determinant of a successful arrest temperature [455]. Consequently, nasopharyngeal temperature was selected as the reference temperature for the definition of the different ranges of hypothermia. It has been shown that the nasopharyngeal and oesophageal temperatures most closely resemble brain temperature during cooling and rewarming. However, it must be critically questioned whether

Temperature profile depending on the point of measurement

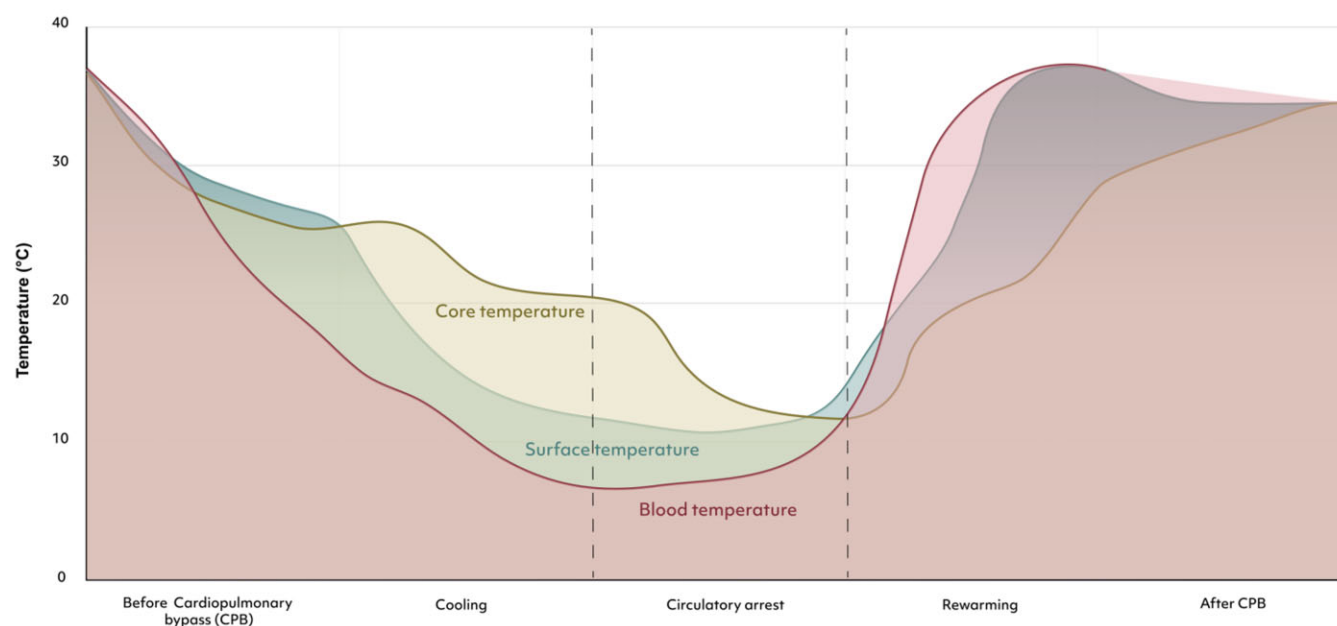


Figure 23: Temperature measurements over time depending on the location of the measurement.

the spinal cord and the other organs are protected in the same way, especially during longer periods of circulatory arrest. This consensus paper defined 4 ranges of hypothermia: profound hypothermia ( $\leq 14^{\circ}\text{C}$ ), deep hypothermia ( $14.1\text{--}20^{\circ}\text{C}$ ), moderate hypothermia ( $20.1\text{--}28^{\circ}\text{C}$ ) and mild hypothermia ( $28.1\text{--}34^{\circ}\text{C}$ ). Other authors classified the temperature levels as follows: deep hypothermia ( $<20^{\circ}\text{C}$ ), moderate hypothermia ( $20.1\text{--}25^{\circ}\text{C}$ ) and mild hypothermia ( $\geq 25.1^{\circ}\text{C}$ ) [456]. Preventza *et al.* [457] studied the impact of temperature in aortic arch surgery on outcome and defined ranges of deep hypothermia ( $14.1\text{--}20^{\circ}\text{C}$ ), low-moderate hypothermia ( $20.1\text{--}23.9^{\circ}\text{C}$ ) and high-moderate ( $24\text{--}28^{\circ}\text{C}$ ). It has to be stated that different classifications of hypothermia are used in the studies, which make reporting and scientific evaluation more than difficult. This situation was the impetus to create a 2023 consensus on hypothermia classification in aortic arch surgery (Table 6).

**Deep hypothermia versus moderate hypothermia.** It has been shown that DHCA provides adequate brain and end-organ protection up to arrest periods of 30 min [458]. Thereafter, the risk of neurologic injury and death increases. In addition, DHCA is associated with coagulopathy, systemic inflammatory response, end-organ dysfunction and neuronal apoptosis [459, 460]. To reduce these effects, there has been a shift towards more moderate hypothermic levels in conjunction with antegrade cerebral perfusion. Several observational studies and meta-analyses elaborate on the safety of moderate hypothermia and the optimal level of hypothermia [461–465]. A meta-analysis by Manoly *et al.* [459] that included 5869 patients demonstrated significantly reduced mortality and stroke rates with moderate hypothermia plus an antegrade cerebral perfusion group compared to the deep hypothermia cohort. Similar results were obtained by another study group that investigated the influence of 3 different hypothermia levels on patient outcome [456]. Deep hypothermic circulatory arrest ( $\leq 20^{\circ}\text{C}$ ) was compared to moderate HCA ( $20.1\text{--}25^{\circ}\text{C}$ ) and mild HCA ( $\geq 25^{\circ}\text{C}$ ). A total of 12 370 patients were included in this meta-analysis. The authors concluded that the moderate-to-mild hypothermia strategies in combination with antegrade cerebral perfusion were associated with decreased operative mortality and the risk of postoperative stroke. Preventza *et al.* [457] showed in a patient cohort of aortic arch operations with antegrade cerebral perfusion times of more than 30 min fewer strokes and reoperations for bleeding at moderate hypothermia levels. Long-term survival was better in the moderate hypothermia group. In the manuscript of Seese *et al.* [466], moderate hypothermia with antegrade cerebral perfusion at a nadir temperature of  $27^{\circ}\text{C}$  confers the greatest early survival benefit and the smallest risk of postoperative morbidity.

**Table 6:** Writing committee 2023 consensus on hypothermia classification in aortic surgery

Category	Core temperature (rectal/bladder)
Deep hypothermia	$\leq 20^{\circ}\text{C}$
Low-moderate hypothermia	$20.1\text{--}24^{\circ}\text{C}$
High-moderate hypothermia	$24.1\text{--}28^{\circ}\text{C}$
Mild hypothermia	$>28^{\circ}\text{C}$

## Organ protection—heart

In complex aortic procedures, cardiac mortality and morbidity remain important issues [467]. Most centres use histidine-tryptophan-ketoglutarate (Custodiol) or cold blood cardioplegia (Buckberg) to protect the heart [468–470]. Some centres use whole blood cardioplegia (i.e. microplegia) also under hypothermia and during complex procedures [471, 472]. Repetitive doses of blood cardioplegia may be administered in a retrograde fashion to avoid interruption of the surgical procedure [471–473]. More recently, del Nido cardioplegia, originally developed for paediatric procedures, has been suggested for adult cardiac surgery cases, including aortic arch surgery [472, 474–481]. It allows for a myocardial ischaemia time of up to 90 min with a single dose. Protocols for repetitive administrations have been developed [472, 475, 479]. There are no data that indicate a specific type of cardioplegia is superior in aortic surgery.

Non-cardioplegic myocardial perfusion was a routine protection method in the past [454]. Over the decades, it was replaced by cardioplegia. Recently, non-cardioplegic myocardial perfusion was revived as an option to reduce myocardial ischaemia times [467, 470, 482, 483] and to improve cardiac outcome during complex aortic arch operations [467, 470], especially if combined with concomitant procedures. Normothermic non-cardioplegic myocardial perfusion results in a more stable sinus rhythm during perfusion [470]. Sufficient venting of the left ventricle is critical to avoid unintended LV distension [467, 470].

Open surgical repair of the aorta from the left chest sometimes involves HCA. Myocardial protection is challenging during these procedures. If cardioplegia cannot be administered, it might be helpful to administer a bolus of potassium chloride immediately before HCA. The topic of myocardial protection during aortic procedures remains controversial.

## Organ protection—lungs

Postoperative pulmonary complications such as pleural effusion, respiratory infection, respiratory failure and atelectasis are common after cardiothoracic surgery. The incidence reportedly exceeds 50% in this critical patient cohort [484]. Because patients undergoing aortic surgery suffer from extensive fluid exchanges and receive pharmacological haemodynamic support, CPB and sternotomy, strategies to protect the lungs like ventilation and perfusion are crucial to lower the risk of postoperative pulmonary complications.

**General considerations.** Despite the lack of aortic-specific surgical data, data on open cardiothoracic surgery and general anaesthesia do exist. In general anaesthesia, the following 3-pillared lung-protective ventilation strategy should be applied: (i) moderate hyperoxia ( $\text{FiO}_2$  not exceeding 80%); (ii) recruitment manoeuvres; (iii) tidal volume of 6–8 ml/kg of ideal body weight and positive end-expiratory pressure of 2–5 cm  $\text{H}_2\text{O}$  [485–489].

One RCT compared 3 different strategies regarding aortic surgery involving CPB but failed to show superiority of any one [484]:

1. No ventilation during CPB
2. Ventilation with low oxygen ( $\text{FiO}_2$  of 30%) and tidal volume (2–4 ml/kg of ideal body weight) with a 10–12 bpm respiratory rate

and positive end-expiratory pressure of 5–8 cm H<sub>2</sub>O and 2 L/min flow

- Ventilation settings as listed in (ii) but with high oxygen (FiO<sub>2</sub> 80%).

A meta-analysis published in 2012 also revealed no outcome benefit of different ventilation strategies during CPB [490].

## Organ protection—brain

Antegrade cerebral perfusion is associated with better long-term survival and better neurologic function [178, 491]. Antegrade flow may be performed through unilateral carotid artery perfusion (unilateral cerebral perfusion) or through both carotid arteries (bilateral cerebral perfusion). The carotid arteries may be intubated by an additional flow cannula or, in case of axillary/subclavian or innominate artery CPB cannulation, the innominate artery may be clamped to allow antegrade flow into the right common carotid artery. In patients with an incomplete circle of Willis diagnosed in preoperative coronary CTA, trilateral antegrade perfusion may be considered by additional cannulation or intubation of the LSA.

In proximal aortic arch operations (hemiarach replacement), retrograde perfusion of the superior vena cava has shown results similar to those found in an antegrade cerebral perfusion cohort [492–494]. However, in these studies the lower body HCA time was around 30 min, and the majority of patients were cooled down to deep hypothermia levels. A contemporary meta-analysis by Takagi *et al.* [495] revealed no difference in the postoperative incidence of stroke and death between antegrade cerebral perfusion and retrograde cerebral perfusion, but noted a trend towards reduction of transient neurologic deficit in the antegrade cerebral perfusion group. The majority of manuscripts included in this analysis elaborated on partial arch replacement.

Retrograde flushing may be considered to clear any debris from the carotid arteries. In patients undergoing hemiarach replacement or other arch intervention with circulatory arrest times <40 min, both unilateral and bilateral antegrade perfusion may be reasonable. In patients undergoing longer circulatory arrest periods (>40 min), bilateral cerebral perfusion from the beginning is reasonable [496–499]. Near-infrared spectroscopy may be helpful to monitor cerebral perfusion and to modify the cerebral perfusion strategy from unilateral to bilateral.

## Organ protection—spinal cord

Ischaemic SCI remains the Achilles heel of open and endovascular TAAA repair [500]. Various neuroprotective strategies [e.g. motor evoked potentials (MEPs) [501]/somatosensory evoked potentials (SSEPs) monitoring [502] and CSF drainage [436, 503]] are established traditional adjuncts to monitor and avoid SCI [504].

Most importantly, the modern CN [180, 181] concept has begun to replace the classic understanding of spinal cord blood supply, implying several important clinical consequences: It challenged the historical paradigm of segmental artery reimplantation [502] (which has not been proven to reliably avoid SCI, thereby concurrently promoting dangerous steal phenomena [505] and prolonging deleterious cross-clamp times, while it remains no option in endovascular repair) [501]; it paved the way for the concept of ‘staging’ (which significantly lowered SCI rates after endovascular repair [506]); it reliably resulted in ‘zero paraplegia’ in large-animal

experiments [507, 508]—and equally in retrospect analysed large clinical open repair series [507]. This sequence of events ultimately led to the minimally invasive staged segmental artery coil embolization (MIS<sup>2</sup>ACE) concept and the PAPAartis RCT [182, 502, 509, 510], it emphasized the importance of regional inflow zones and perioperative blood pressure management [511] to sustain sufficient cord perfusion during and after aortic cross-clamping (encouraging the liberal use of distal aortic perfusion and serial clamping in open repair and deterring the use of a large-bore sheath in endovascular repair).

Reliable non-invasive tools to monitor cord perfusion to detect imminent spinal cord malperfusion, ischaemia and forthcoming neurologic injury (particularly early postoperatively) are not yet available; neither is a reliable strategy to prevent SCI during distal circulatory arrest and after segmental artery occlusion. However, 2 promising new concepts—potentially advancing spinal cord protection further—address these issues: (i) the clinical application of non-invasive real-time monitoring of the thoracic and lumbar paraspinous CN oxygenation via NIRS to detect hypoperfusion in a timely manner [512], and (ii) priming of the CN by minimally invasive staged segmental artery coil embolization (MIS<sup>2</sup>ACE), to achieve sufficient resilience of spinal cord perfusion prior to definite aortic repair. Neuromonitoring including MEPs and SSEPs is helpful in order to monitor posterior column sensory proprioceptive and anterior motor pathways in both open thoraco-abdominal replacement and TEVAR. Therefore, their use in these procedures is encouraged. Cerebrospinal fluid drainage is not routinely recommended in TAR because the risk of symptomatic SCI is low. Nevertheless, it should be considered in high-risk patients with an already reduced spinal cord blood supply (previous TEVAR/TAR), occluded LSA or internal iliac arteries.

## Organ protection—viscerals and renals

**Visceral arteries.** Postoperative visceral organ dysfunction can negatively affect short- and long-term outcomes in patients undergoing proximal aortic, aortic arch and thoraco-abdominal aortic surgery. Clinically, the kidneys are the organs most sensitive to ischaemia, followed by the liver and the bowel. Significant injury can occur when ischaemia lasts longer than 90 min, although, at higher body temperatures (e.g. 30°C), the safe ischaemic period can be as short as 60 min [513, 514]. Serial measurements of liver enzymes (e.g. aspartate amino transferase, alanine amino transferase, bilirubin) and circulating lactate levels have been used to monitor for visceral ischaemia [439, 461].

**Visceral protection during aortic arch surgery.** Despite the lack of supporting evidence from RCTs, various methods to reduce postoperative visceral organ ischaemia have been used by aortic experts [461, 515–517]. These methods include expeditious repair, establishing distal aortic perfusion as soon as possible, additional distal aortic perfusion and various degrees of systemic hypothermia and HCA [441]. Prolonged circulatory arrest and warm distal circulatory arrest can alter intestinal mucosal perfusion and blood flow regulation and cause mucosal oedema, leading to prolonged visceral ischaemia that can result in multiorgan failure and possibly bowel infarction [518–522]. Controlled rewarming that keeps the gradient between the core temperature and the perfusate temperature at 10°C is important to avoid reperfusion injury [519, 523].

**Visceral protection during thoraco-abdominal aortic surgery.** Bowel ischaemia is uncommon after TAAA surgery. It occurred in <1% of 1267 consecutive TAAA repairs [524]. Experienced ACs use various techniques for visceral protection during thoraco-abdominal surgery, although few randomized trials have specifically addressed bowel and liver protection during TAAA surgery. Elevated hepatobiliary values after extensive TAAA repair seem to be correlated with prolonged ischaemic times [525]. In addition to permissive or active hypothermia with circulatory arrest, expeditious repair and shortening distal aortic ischaemic times, other specific techniques include left heart bypass and, for extensive TAAA repairs, perfusing the coeliac axis and superior mesenteric artery with isothermic self-oxygenated blood at a rate of 400–500 ml/min, which can decrease bacterial translocation from the bowel and postoperative coagulopathy. Other patient-specific adjuncts include endarterectomy of the ostia of the coeliac artery or superior mesenteric artery and balloon angioplasty and stenting of these vessels under direct vision [525–531]. Among 3309 repairs, the renal and visceral arteries were managed by endarterectomy, bypass or stenting in 9.6% of extent I repairs, 47.8% of extent II repairs, 54.1% of extent III repairs and 60.5% of extent IV repairs [528].

**Renal arteries.** Satisfactory oxygen delivery and perfusion pressure should be maintained intraoperatively (before, during and after CPB) and postoperatively to avoid end-organ injury in aortic surgery. Acute kidney injury (AKI) after cardiovascular surgery is a frequent complication. Its risk during long, complex procedures such as surgery of the aorta was identified more than 60 years ago [46, 532]. Cardiopulmonary bypass is a recognized factor contributing to AKI. For general cardiovascular operations, the incidence of AKI is around 30%, and up to 5% can require renal replacement therapy. In more complex aortic operations such as open thoraco-abdominal aortic repair or ATAAD repair, the need for renal replacement therapy ranges between 7% and 15% [528, 533, 534]. Acute kidney injury is a highly morbid postoperative event that may also adversely impact long-term survival after aortic surgery. Prevention of such complications is of vital importance [535].

Many factors are known to be associated with increased risk of AKI in aortic surgery. Pre-existing renal failure, advanced age, sex, diabetes, hypertension, anaemia, need for prolonged CPB, visceral circulatory arrest, atherosclerotic burden, prior operations and decreased LV function play a role in AKI development but cannot be modified.

For open surgery with CPB, several factors may impact the development of AKI. The kidney is at constant risk for the development of imbalances in renal oxygen delivery/renal oxygen consumption. During CPB it is imperative to maintain a satisfactory goal-directed perfusion pressure, always ensuring appropriate pump flow and satisfactory oxygen content (CaO<sub>2</sub>), and these goals should be pursued postoperatively.

For certain aortic arch operations, a period of lower body ischaemia is necessary to complete the aortic repair. There is no absolutely safe period of circulatory arrest under normothermic conditions, because it is well known that circulatory arrest leads to irreversible organic sequelae [536]. Aortic repair at different degrees of systemic hypothermia is possible when interruption of circulation is necessary. As observed in other organs, renal oxygen consumption decreases as temperature declines;

however, renal ischaemia and risk for AKI remain [537]. In situations where HCA is mandatory to achieve repair, usually in TAAD, less renal failure requiring dialysis has been observed with lower systemic temperatures (18°C) [538–541]. Unfortunately, this situation is associated with a longer CPB run, blood cell trauma, endothelial dysfunction, coagulopathy and the need for transfusions, events that have been shown to be predictors of AKI in previous aortic arch studies [542–545]. It has been argued that any potential renal protection benefit from additional hypothermia may be offset by the added time on CPB [546]. In more homogeneous populations, profound hypothermia in patients undergoing DHCA appeared to have protective effects on kidney function [547]. The incidence of postoperative renal failure in patients undergoing aortic arch surgery with hypothermia at 16.8°C versus 22.9°C did not differ in other studies, where the mean duration of circulatory arrest was equivalent at around 40 min [548]. Other retrospective studies, with limited circulatory arrest periods, point at moderate instead of deep hypothermia as a reasonable strategy for kidney protection [549]. Unfortunately, lack of randomized data precludes detailed recommendations for the best HCA temperature. It is likely that longer CPB times counterweigh hypothermic organ protection. Thus, surgical judgement with a tailored intervention and an understanding of the clinical tolerance to renal ischaemia are still necessary.

Rewarming strategies after hypothermia play a significant role in the development of AKI. After HCA, a period of hypothermic perfusion (same temperature as before arrest) before initiation of rewarming is usually utilized to attenuate reperfusion injury by decreasing tissular oxygen consumption. Avoidance of rapid rewarming and hyperthermic perfusion are recommended. To attenuate the rewarming insult, it is recommended to avoid temperature differences between the arterial and venous lines above 3°C, with a rewarming rate no faster than 1°C every 5 min. The incidence of AKI increases with every 10 min of rewarming with an arterial inflow temperature >37°C [546, 550, 551].

Lower body uninterrupted perfusion is a technique used to provide blood perfusion to distal organs and the spinal cord during open arch and proximal descending surgery. Yet, the net effect of lower body uninterrupted perfusion on postoperative renal function remains unclear. Reduction of CPB time can be achieved by avoiding deep hypothermia and shortening cooling and rewarming phases. Some reports point at the potential benefit of this approach to prevent spinal cord ischaemia, renal failure and visceral ischaemia [438, 552].

Minimizing or avoiding circulatory arrest can shorten operative times and avoid the systemic effects associated with organ ischaemia and hypothermia. When it is technically feasible, adopting such an approach seems logical to minimize prolonged loss of pulsatile perfusion, inflammation secondary to the interaction of blood with the CPB equipment, fragmentation of blood cells leading to haemolysis and pigment nephropathy, with known effects on renal function.

In open TAAA surgery, cold crystalloid renal perfusion has shown superiority over isothermic or cold blood renal perfusion [442, 443]. In a recent randomized trial, use of the histidine-tryptophan-ketoglutarate solution (Custodiol) during open TAAA repair resulted in significantly lower rates of postoperative AKI compared with Ringer's solution [444, 445]. Leg ischaemia leading to rhabdomyolysis in TAAA surgery is associated with AKI and should be avoided, when possible, through lower limb perfusion

in which arterial return cannulation through a side prosthetic graft in the femoral artery may play a significant role [553, 554].

## Extremities

Lower limb ischaemia can be an intraoperative complication in aortic surgery, because long distal aortic clamping times are frequently required in open surgery or large-bore introducer sheaths are placed in the femoral arteries for endovascular procedures, ECC or LV assist devices [555, 556]. In addition to ischaemia due to decreased perfusion, atheroembolic events might also lead to lower limb ischaemia.

**Monitoring lower limb function.** Preoperative imaging with duplex ultrasound and CTA is necessary to obtain baseline lower extremity arterial function. Physical examination for the presence of peripheral pulses is a quick way to monitor lower extremity perfusion, in addition to visual inspection for pallor, touching for temperature changes and evaluating capillary refill time. Posterior leg muscle rigidity is also indicative of ischaemic injury, especially in ischaemia/reperfusion situations.

General anaesthesia requires more invasive and regular monitoring for end-organ function. The MEPs and SSEPs are usually used for monitoring posterior column sensory proprioceptive and anterior motor pathways, but they can also be used for detecting lower limb ischaemia, especially if it is unilateral. Intraoperative signals can be compared to preoperative baseline evaluations. Intraoperative duplex ultrasound can be used for real-time blood flow monitoring.

Ischaemic markers such as lactate level and lactate/pyruvate ratio should be monitored intraoperatively. Even though it is not specific for lower limb ischaemia, an increase in these markers can prompt the physician to take measures for increasing limb perfusion. In the postoperative period, increased creatinine phosphokinase levels can indicate lower limb ischaemia.

**Avoiding end-organ injury.** Lower limb ischaemic complications occur more frequently in patients who have peripheral artery disease, longer procedure times that necessitate femoral occupancy and smaller ilio-femoral axes [555, 556]. In these cases, pre-emptive protective measures should be considered in order to reduce the risk for end-organ complications. Anaesthesiologic considerations include keeping mean blood pressure around 90–100 mmHg and euvoemia helps maintain adequate end-organ perfusion. Permissive mild hypothermia (33–34°C) might also be used in complicated open repair. In addition, the target activated clotting time should be achieved and monitored throughout the procedure. Early introducer sheath removal or downsizing with suture-mediated closure devices or purse-string sutures should be done, when possible, to increase peripheral blood flow [557]. When it is not possible to use low profile devices or to downsize, termino-lateral ilio-femoral conduits can be sutured on the native artery to accommodate sheath introduction. Temporary perfusion of the extremities can also be achieved by placing antegrade reperfusion sheaths in the superficial femoral artery [557, 558].

In open aortic surgery, left heart bypass has proved extremely helpful for distal organ perfusion. Usually, an outflow cannula is placed in the common femoral artery to provide retrograde flow and at the same time to allow distal flow to the homolateral limb during assisted circulation.

## THERAPEUTIC OPTIONS

### Aortic root

**Recommendation Table 22: Therapeutic options: aortic root**

Recommendations	Class <sup>a</sup>	Level <sup>b</sup>	Ref <sup>c</sup>
For aortic dilations and aneurysms involving the aortic root with a structurally diseased aortic valve, replacement of the aortic valve and sinuses with coronary ostia direct reimplantation (modified Bentall operation) is recommended.	I	B	[559–561]
Valve-sparing root replacement should be considered for patients with a non-diseased tricuspid aortic valve and dilated root, especially young patients, if performed by experienced surgeons.	IIa	B	[562, 563]
Valve-sparing root replacement may be considered for patients with a non-diseased bicuspid aortic valve and dilated root if performed by surgeons with specific expertise in aortic valve repair.	IIb	B	[564]

<sup>a</sup>Class of recommendation.

<sup>b</sup>Level of evidence.

<sup>c</sup>References.

Treatment of aortic root dilatation follows the surgical principle of resecting the diseased aortic tissue to prevent acute complications, namely, dissection and rupture. Because the aortic root and valve form a functional unit, the surgeon also tries to maintain or restore normal valve function. In ATAAD, the general principle of surgical treatment is to resect the segment containing the entry tear: The root must be replaced when it is either the site of the intimal tears or significantly involved by dilatation.

For aortic dilations and aneurysms involving the aortic root ('root phenotype dilatation'), options include composite replacement of the aortic valve and sinuses with direct reimplantation of the coronary ostia (modified Bentall–De Bono operation) and different variants of valve-sparing root replacement. Notably, this pattern of dilatation, already known to be typically associated with HTAD, is being increasingly recognized as clinically more malignant, also in the general population [336, 338].

In the elective setting, the Bentall–De Bono operation yields low in-hospital mortality (most recently 1–2%) [559, 560, 565] and good long-term survival (78–93% at 10 years) [559, 565], with hazards of late adverse events depending on valve prosthesis type (mechanical/biological) [560]. Early mortality is higher in the setting of ATAAD [561]; therefore, particularly when a lengthy operation is foreseen and there is no entry tear in the root, simple Teflon felt reinforcement or reconstruction, with valve resuspension or replacement, may be preferred: Diameter growth of the reconstructed root can be very slow [566]; however, freedom from late reoperation can be lower than after the Bentall–De Bono operation [567]. There is a lack of evidence as to which exact criteria (e.g. root dimensions) should prompt concomitant root replacement in ATAAD without a tear in the sinuses.

In the past, valve-sparing root replacement procedures were suggested for patients with a normally functioning tricuspid

aortic valve and a dilated root [282]. Today, the requisite is a valve without gross degeneration and calcification [141]. Indeed, evidence has been accumulated that, at least when performed by surgeons with specific expertise, root reimplantation (David operation) or root remodelling (Yacoub operation) with associated annuloplasty can have in-hospital mortality rates between 0.3 and 1.5% in the elective setting, allowing lower valve-related complications than the Bentall-De Bono operation, optimal durability in terms of valve function and the need for reoperation, both for BAV and TAV aortopathies [560, 562–564]. At least in patients with HTAD, the remodelling technique without annuloplasty should not be preferred because of concerns about late postoperative annular enlargement and recurrence/occurrence of aortic insufficiency [568, 569].

In patients undergoing surgery for an aneurysm of the mid-ascending aorta, a non-dilated or just mildly dilated (<45 mm) root ('ascending phenotype dilatation') should not be replaced, unless there are concerns about the patient's young age, family history of ATAAD or known HTAD. Unlike distal extension into the arch, proximal extension to the root/valve does not significantly increase mortality and adverse events [570]. However, unreplaced roots in elective ascending aorta surgery have been demonstrated to grow slowly (0.4–0.8 mm/year, generally slower with BAV than with TAV) [571, 572] and rarely require reoperation [573, 574]. In some ascending phenotype dilatations, one sinus is concomitantly dilated (e.g. the non-coronary in right-left fused BAVs) and can be selectively replaced, adequately tailoring the ascending graft [572].

## Ascending aorta with or without proximal arch

### Recommendation Table 23: Ascending aorta with or without proximal arch

Recommendations	Class <sup>a</sup>	Level <sup>b</sup>	Ref <sup>c</sup>
In ascending aortic surgery, supracommissural isolated ascending aorta replacement is recommended in patients without adjunct aortic root and aortic arch dilatation.	I	B	[571, 572, 574]
It is recommended that in any open proximal thoracic aortic operation, ascending/hemiarch replacement has to be extensive, and short ascending grafts should be avoided to prevent disease progression and to anticipate a future endovascular modular distal extension.	I	C	-
In ascending aortic surgery with a diameter larger than 45 mm of the proximal aortic arch, hemiarch or more extensive aortic arch replacement may be considered.	IIb	B	[575]

<sup>a</sup>Class of recommendation.

<sup>b</sup>Level of evidence.

<sup>c</sup>References.

The purpose of surgical treatment of a chronic aneurysm of the ascending aorta is to prevent aortic rupture or dissection by excising and replacing dilated areas and restoring normal aortic

diameters. If the aneurysm is confined to the tubular portion of the ascending aorta and the root and arch are not involved by the pathology, a supracoronary ascending aorta replacement with interpositional graft can be the simplest effective technique of choice.

Many patients present an ascending aortic aneurysm with partial involvement of the arch. These cases are effectively treated with hemiarch replacement, when aortic cross-clamping is not possible. In this case, adding a hemiarch to a proximal aortic aneurysm repair in the absence of an arch aneurysm may be associated with higher short-term mortality compared to a non-hemiarch [575]. Moreover, ascending grafts should be chosen, anticipating further distal endovascular treatment: first, straight implantation of the prosthesis and second, a prosthesis length of ≥7 cm.

After circulatory arrest is established, provided there is no evidence of a pre-existing arch aneurysm, the aorta is completely transected in a bevelled fashion: The transection begins at the greater curvature immediately proximal to the origin of the innominate artery and extends towards the lesser curvature to the level of the LSA, preserving most of the greater curvature of the arch. The native aorta is then sutured to the pre-shaped 'flute beak' polyester graft using a continuous monofilament suture.

In case of partial involvement of the aortic arch requiring partial arch replacement, an alternative to hemiarch replacement is represented by the replacement of parts of the arch with a single reimplantation of 1 or more epi-aortic trunks. The epi-aortic trunks can be reimplanted separately using a quadrifurcated graft: In this case the distal anastomosis can be performed in Ishimaru zone 1 or 2 depending on the extension of the aneurysm, thus reimplanting only 1 or 2 of the 3 epi-aortic vessels (the brachiocephalic trunk or also the left common carotid artery).

## Aortic arch

### Recommendation Table 24: Therapeutic options: aortic arch

Recommendations	Class <sup>a</sup>	Level <sup>b</sup>	Ref <sup>c</sup>
In patients with an intended one-stage aortic arch treatment, the FET technique should be considered.	IIa	B	[576–581]
Aortic arch replacement, including the creation of a sufficient landing zone, is recommended in the treatment of multisegmental aneurysms of the thoracic aorta in order to facilitate the further downstream repair.	I	C	-
When performing the frozen and conventional elephant trunk techniques, a distal anastomosis in arch zone 2 should be considered.	IIa	C	-
In the case of an elephant trunk implant, the polyester trunk component should be considered to be accessible in zone 4.	IIa	C	-
Hybrid procedures may be considered for aortic arch repair.	IIb	C	-

Continued

In any TEVAR involving zone 2, left subclavian artery revascularization is recommended to reduce the risk of neurologic complications such as stroke and spinal cord ischaemia.	I	B	[582–584]
---	---	---	-----------

<sup>a</sup>Class of recommendation.

<sup>b</sup>Level of evidence.

<sup>c</sup>References.

FET: frozen elephant trunk; TEVAR: thoracic endovascular aortic repair.

### **Aortic arch with and without affection of proximal and distal aortic segments.**

Isolated diseases of the aortic arch of any kind in the adult are infrequent [585–591], as is isolated surgical replacement, although some reports have focused on this [592]. The ascending and the proximal descending aorta are usually involved in aortic arch lesions. Therefore, surgical decisions involve the proximal and distal aorta, the neck vessels and brain protection strategies.

There is a need for additional data collection and RCTs to favour endovascular or open arch treatment. With these considerations in mind, arch replacement can be performed through an open or endovascular approach.

**Open surgical arch replacement.** The surgical conduct of the operation differs little between acute and chronic conditions and between aneurysms and dissections, and TAR has to be considered one of the most aggressive and invasive operations in surgery, not just cardiovascular surgery [593].

Even in surgical reports claiming isolated TAR [592], this operation needs an adjunct such as the elephant trunk [594] or the FET [576, 577]. Current trends confirm the progressive adoption of the FET as the technique of choice for complex arch aneurysms with distal extension [358, 469, 578, 579] with ongoing discussions with regards to its applicability or benefit in aortic dissections [53, 580, 593]. In certain age groups, there is also controversy regarding TAR as a reasonable procedure with or without FET due to increased morbidity and mortality and lower expected follow-up survival in older patients [581]. Knowledge regarding the FET operation has increased in the past decade, and societal positions have been defined [53, 595]. Despite the

increasing importance of the FET technique in ATAADs, there is no standard role for a conventional elephant trunk in these patients.

A hybrid approach performed simultaneously or on a sequential basis to treat the aortic arch is designed to decrease the surgical trauma by eliminating aortic cross-clamping, CPB and HCA with its intrinsic deleterious effects. This approach is of particular importance in those patients considered to be high surgical risk. The ultimate goal is creating an adequate landing zone to deploy an endovascular device in proximal Ishimaru zones (0–2). Due to the variable branching pattern and according to different pathological conditions, the options for vascular transposition (Fig. 24) of the supra-aortic vessels are multiple. Patient selection is of utmost importance. The risks of stroke and of death are to be considered due to the instrumentation of the aorta during anatomical debranching and endovascular grafting because hybrid procedures are associated with increased risks of death and stroke [582].

The LSA plays a fundamental role in planning for patients with distal aortic arch pathology. Prophylactic LSA revascularization is meant to avoid neurologic complications when LSA coverage during TEVAR is to be performed [583]. Furthermore, the LSA anatomy has implications for endovascular aortic arch repair [584].

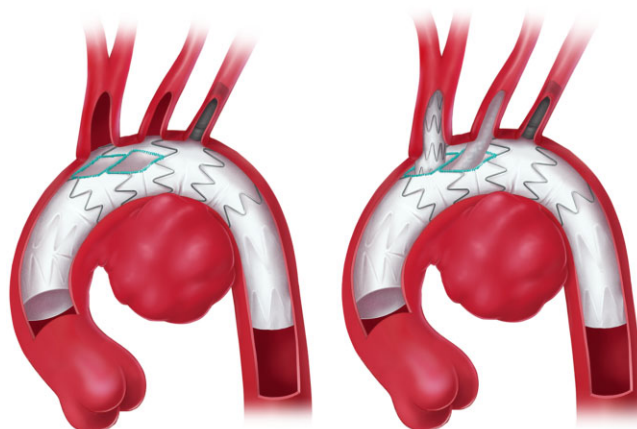


Figure 25: Branched endovascular total aortic arch repair.

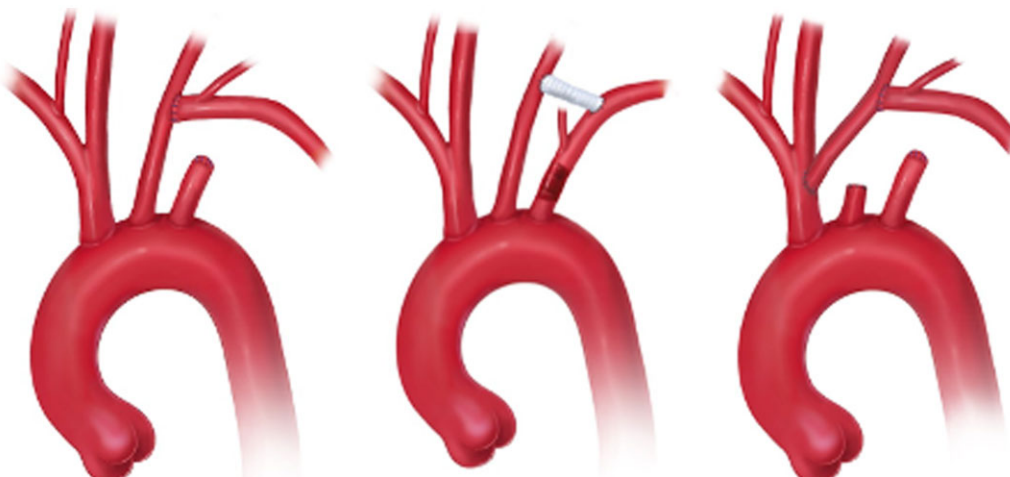


Figure 24: Subclavian artery transposition, carotid-to-subclavian bypass and double transposition.

Frozen elephant trunk, Hemiarch replacement, David operation

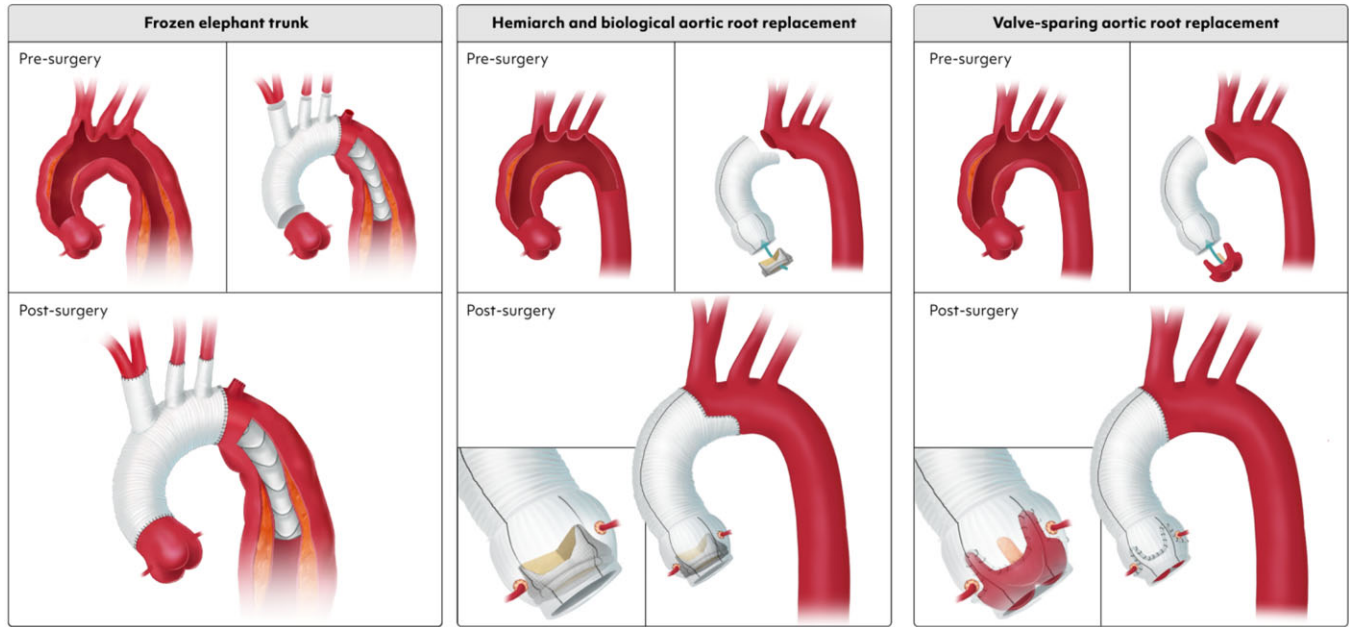


Figure 26: Frozen elephant trunk, hemiarch replacement and valve-sparing aortic root replacement.

**Endovascular arch repair.** The aortic arch is an extremely complex anatomical and functional region of the aorta. Steady development in technology has allowed the improvement of aortic arch endografts and delivery systems with different branching patterns targeting specific subsets of patients who are considered at too high risk for open surgical repair with TAR [319, 596]. Branched endovascular technology (Fig. 25) is finding its way, and there is proof of concept that, despite the lack of sufficient experience, cumulative data and follow-up, it may represent an alternative to TAR in high-risk or inoperable patients in the future [597]. Further research supplemented with anecdotal clinical cases focuses also on overcoming the limitations of an insufficient proximal landing zone with the introduction of the endovascular Bentall concept [598, 599].

Proximal aortic surgery techniques for root, hemiarch and TAR using the FET technique are illustrated in Fig. 26.

Descending aorta

Recommendation Table 25: Therapeutic options: descending aorta

Recommendations	Class <sup>a</sup>	Level <sup>b</sup>	Ref <sup>c</sup>
In patients undergoing endovascular aortic repair with suitable femoral artery anatomy, ultrasound-guided percutaneous access is recommended.	I	B	[600]
TEVAR is recommended as the first-choice therapy for acute complicated descending aortic syndromes.	I	B	[601, 602]

Continued

If LSA-to-LCCA bypass/transposition or double transposition cannot create a sufficient proximal landing zone, the FET technique should be considered.	IIa	C	-
If concomitant valvular or coronary disease requiring treatment is present together with acute and chronic thoracic aortic pathology involving the aortic arch, the FET technique should be considered.	IIa	B	[247, 254]
Stent-graft oversizing in degenerative/atherosclerotic aneurysms or PAUs should be considered <15–20% of the proximal and distal landing zone diameters.	I	C	-
Stent-graft oversizing in acute aortic dissection/IMH should be considered <10% of the proximal landing zone diameter.	I	C	-
It should be considered that the landing zone diameter should not exceed 38 mm in diameter.	IIa	B	[603]
It should be considered that the proximal landing zone length be at least 25 mm.	IIa	C	-
It should be considered that the distal landing zone length be at least 25 mm.	IIa	C	-
In TEVAR for type B aortic dissection, distal tapering for the prevention of dSINE should be considered according to the TL diameter.	IIa	C	-

Continued

The PETTICOAT technique should be considered in acute aortic dissections as a distal adjunct to TEVAR in case adequate true lumen decompression cannot be established by TEVAR alone.	IIa	B	[604–606]
The STABILISE technique may be considered in particular scenarios but preferably under controlled study conditions.	IIb	C	-

<sup>a</sup>Class of recommendation.

<sup>b</sup>Level of evidence.

<sup>c</sup>References.

dSINE: distal stent graft-induced new entry; FET: frozen elephant trunk; LCCA: left common carotid artery; LSA: left subclavian artery; IMH: intramural haematoma; PAU: penetrating atherosclerotic ulcer; PETTICOAT: Provisional Extension To Induce Complete Attachment; STABILISE: Stent-Assisted Balloon-Induced Intimal Disruption and Relamination in Aortic Dissection Repair; TL: true lumen; TEVAR: thoracic endovascular aortic repair.

Thoracic endovascular aneurysm repair is the first-line intervention for most pathologies at the level of the descending thoracic aorta due to its favourable outcomes and lower invasiveness [602, 607, 608]. The latter is based on inserting the transfemoral implant through a femoral artery cut-down or percutaneous access, which has been stimulated by the recent developments of low-profile TEVAR deployment systems and dedicated large-bore closure devices [600, 609, 610].

The goal of TEVAR is the exclusion of descending aortic pathology (descending TAA), PAU, the false lumen of the aortic dissections and traumatic rupture from the circulation by means of endovascular coverage with the induction of thrombus formation within the diseased aortic segment. For example, in type B dissections, TEVAR covers the proximal entry tear and eliminates the antegrade blood flow to the false lumen, which leads to false-lumen depressurization and thrombosis, accompanied by expansion of the true lumen [251, 611]. Those desirable morphologic effects observed in the treated aortic portion are referred to as (positive) aortic remodelling, which was shown to reduce aortic-related mortality associated with the type B dissections in the INSTEAD XL RCT [249, 250].

The exclusion of the pathology is ensured by sealing the endograft in the proximal and distal sealing zones (PSZ; DSZ), which presumes the completeness of the apposition of the oversized endograft to the aortic wall, whereas the proximal landing zone describes the targeted proximal endograft deployment level in relation to the supra-aortic trunks [612].

The choice of the sealing zones has important implications for the early and late outcomes after TEVAR. The healthy PSZ in the descending aorta or the distal aortic arch should exceed 25 mm, whereas the DSZ should be 25 mm and 50 mm if the distal deployment is in the native aorta or a previously implanted prosthesis, respectively [128]. The PSZ length is measured in the inner curvature and presumes the complete proximal apposition of the endograft to the inner aortic wall [136]. In the presence of type III aortic arches with small radii, the incomplete apposition of the endograft in the PSZ (bird-beak) needs to be anticipated and considered regarding the procedure choice and planning [612–614]. This may necessitate the proximalization of the proximal landing zone through the debranching of supra-aortic vessels or the creation of a sustainable PSZ with the FET procedure [136, 615] for further endovascular interventions.

Beyond the sealing zone length of  $\geq 25$  mm, the quality of the aortic wall plays a crucial role in the outcome after the endovascular repair. The aortic wall quality criteria of the TEVAR sealing zones can be summarized as follows:

- Absence of connective tissue disease
- Aortic diameter of the PLZ  $\leq 38$  mm
- Absence of thrombus and calcification
- Absence of intramural haematoma or dissection

The outcome of patients with connective tissue diseases treated with TEVAR in native landing zones is associated with a considerable rate of complications and of reinterventions, although favourable endovascular repair outcomes were reported in smaller series [616–619]. Furthermore, patients with sealing zone diameters  $>38$  mm may experience further neck degeneration based on the oversizing-mediated seal in an already dilated neck [603]. The occurrence of endoleak type I may be associated with further neck dilatation and the presence of thrombus or calcification in the sealing zones [603, 620]. The evaluation of the PSZs in type B dissections treated with TEVAR showed a high rate of IMH presence in Ishimaru zones 1–3, which may increase the risk of retrograde type A aortic dissection (RTAD) following TEVAR [621]. Beyond the sealing zone length and quality, the oversizing of TEVAR is relevant for the durable seal. The level of the proximal endograft oversizing is determined by the chronicity of the aortic pathology. The treatment of chronic conditions (PAU, descending TAA and chronic type B dissections) is recommended with an oversizing of 15–20% in the proximal and distal landing zones. In patients with acute and subacute type B dissections or type B IMHs, the interaction of the vulnerable aortic wall with the oversized endograft may lead to a higher risk of new entry tears with an increased risk for RTAD [621, 622]. Thus, for the acute and the subacute dissections, a moderate proximal oversizing of  $<10\%$  and the use of endografts with low radial force and without proximal bare struts are recommended in order to reduce the irritations of the aortic wall in the PSZ [622, 623].

In aortic dissections, considerable tapering of the diameter of the true lumen is frequently observed, which is due to the compression of the true lumen by the pressurized false lumen and the elastic properties of the intima layer [409]. Therefore, accurate distal endograft sizing still constitutes a challenge when planning the procedure and should consider the dissection chronicity, ultrasound-based membrane elasticity, the circumference-derived true lumen diameter and the growth of the aortic diameter immediately after the onset of the dissection [409, 624]. The use of tapered endografts in aortic dissections reduces the extensive distal endograft oversizing, which was identified as the main risk factor for [625, 626]. The distal stent graft-induced new entry (dSINE) describes the membrane rupture at the distal endograft orifice, which causes false lumen reperfusion and growth of the aortic diameter and requires reinterventions in the majority of cases to prevent aortic rupture [625, 627, 628].

The use of restricted bare stent extensions in the thoracic aorta or of a provisional extension to induce complete attachment [PETTICOAT (Provisional Extension To Induce Complete Attachment) technique] has been applied to prevent dSINE by reducing the true lumen taper ratio and maximizing the true lumen expansion, respectively [604, 605]. However, using different aortic bare stent types and techniques in smaller cohorts

hampered the long-term evaluation of these procedures in a meta-analysis, whereas a recent MC trial showed improved remodelling with the PETTICOAT technique [606]. A recent retrospective single-centre study showed no favourable long-term remodelling after the PETTICOAT technique with a high rate of re-interventions and open conversions [605]. STABILISE is a novel technique recently proposed for the treatment of acute and sub-acute type B dissection with a bare stent extension following TEVAR. Different from the mentioned techniques, the goal of the STABILISE technique is to carry out the balloon-assisted disruption of the dissection membrane at the site of the bare stent to eliminate the bi-luminal flow [629]. Only smaller studies are currently available and describe favourable aortic remodelling and outcomes, which need to be confirmed by further evidence [629].

Compared to the endovascular therapy of the descending aorta, the importance of open repair lies mainly in the creation of the PSZ. If the PSZ is unfavourable for TEVAR, the FET is the first-line option to create a durable PSZ for further endovascular or open interventions in the descending or thoraco-abdominal aorta even in the absence of an aortic arch pathology [136]. The isolated open repair of the descending aorta carries a higher periprocedural risk in terms of increased mortality and spinal cord ischaemia rates in comparison to TEVAR [608]. Nevertheless, isolated open repair of the descending aorta still plays an important role in patients with failed TEVAR, unsuitable anatomy, and unsuitable connective tissue disease and includes infectious aortitis (IA), aorto-bronchial or aorto-oesophageal fistula and graft/endograft infections [630].

## Thoraco-abdominal aorta

**Recommendation Table 26: Therapeutic options: thoraco-abdominal aorta**

Recommendations	Class <sup>a</sup>	Level <sup>b</sup>	Ref <sup>c</sup>
For patients with low-to-moderate perioperative risk, open repair as well as endovascular treatment of pararenal and TAAA should be considered.	IIa	C	-
For patients unfit for open repair, a B/FEVAR procedure should be considered the first-line treatment.	IIa	B	[631, 632]
A hybrid approach may be considered for patients unfit for open repair and anatomically unsuitable for a B/FEVAR procedure.	IIb	C	-
A 'distal-shifting' strategy may be considered in any TAAA to reduce left lung manipulation to a minimum.	IIb	C	-
For patients at high risk for SCI undergoing endovascular treatment of type I, II, III or V thoraco-abdominal aortic aneurysms, a staged TEVAR-B/FEVAR approach should be considered.	IIa	C	-
In open TAAA repair, proximal clamping before the full establishment of CPB to avoid retrograde embolization of parietal thrombi should be considered.	IIa	C	-

Continued

In patients undergoing open descending or thoraco-abdominal aorta repair, cryoablation of multiple intercostal spaces (temporary nerve blockage) may be considered for pain control as an adjuvant strategy.	IIb	C	-
Left heart bypass or partial femoral-femoral bypass for open thoraco-abdominal aorta repair should be considered based on surgical and institutional experience.	IIa	C	-

<sup>a</sup>Class of recommendation.

<sup>b</sup>Level of evidence.

<sup>c</sup>References.

B/FEVAR: branched and/or fenestrated endovascular aortic repair; CPB: cardiopulmonary bypass; SCI: spinal cord injury; TAAA: thoraco-abdominal aortic aneurysm; TEVAR: thoracic endovascular aortic repair.

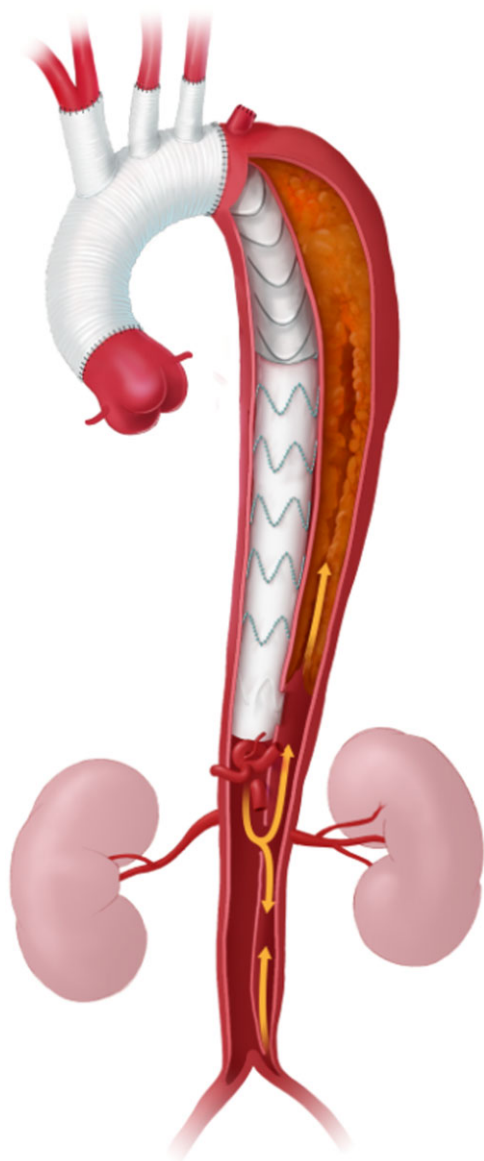
The success of classical open TAR depends on providing organ protection and monitoring organ function. This section is meant as a technical guide for open surgery, independent of the underlying pathology.

**Cannulation and extracorporeal circulation.** Two options are available: (i) partial CPB or (ii) left heart bypass [451, 633–636]. In cases with an aorta that could not be clamped or based on the availability of specific institutional expertise, DHCA can be considered an alternative.

**Specifics in patients with parietal thrombi.** Clamping of the most proximal site at the start of ECC is a helpful tool to prevent retrograde embolization and detached parietal thrombi, which helps in preventing strokes.

**Conceptual considerations.** In case of feasibility, a 'distal-shifting' strategy should have preceded any classical open TAR either by previous FET and/or TEVAR in order to achieve a proximal 'full-fix' [637] (Fig. 27) and in particular to reduce the need for manipulation of the left lung to a minimum. A 'non-touch' technique for the pulmonary parenchyma helps to reduce collateral injury and can make the difference not only after the initial phase during and after weaning from the ECC but also substantially impacts the postoperative course. Reversing the right anterior semi-supine position to a more anterior-posterior positioning may help to improve right ventricular and left lung function [638].

**Clamping strategies.** A sequential clamping strategy is recommended [634, 635]. Using HCA to accomplish the proximal anastomosis should be avoided because the combination of HCA, left lung manipulation and major surgery entails risk (Fig. 28). If the proximal anastomosis is an elephant trunk or an FET, one needs to 'fish' for the proximal landing zone. The elephant trunk or the FET component should be accessible in zone 4 [637, 639, 640]. The technical component is recommended as follows: clamping at the zone 4/5 transition, an anti-Trendelenburg position, rapid pacing to reduce cardiac output, opening the aorta (in case of opening the dissection membrane), fishing for and clamping the elephant trunk/FET and stopping the rapid pacing, then



**Figure 27:** Frozen elephant trunk implant followed by distal thoracic endovascular aortic repair extension for distal shifting.

continuing in a regular fashion. This strategy includes all the advantages of the elephant trunk/FET strategy, avoids distal aortic arch/proximal descending aortic dissection and reduces the risk of left laryngeal nerve injury. This strategy has to be used with extreme caution in patients with Moya-Moya disease, because even very short periods of hypotension can lead to coronary artery spasm, which causes irreversible myocardial injury.

Control of back bleeding of thoracic segmental arteries is the next decisive step because steal caused by uncontrolled back bleeding via the thoracic segmental arteries is highly likely to be one of the major determinants of symptomatic SCI [505]. Small Fogarty catheters may help to reduce back bleeding in a short period of time. If preoperative imaging was not decisive for identification of target vessels for reimplantation, MEPs and SSEPs can help at that level for selection.

The next clamping site usually is at the infrarenal level in case the iliac axis shows either regular diameter, has already been

addressed by previous surgery or by a decision to postpone iliac repair to a later time. This strategy is also helpful to maintain bilateral hypogastric perfusion, which is a major source of spinal cord arterial collateral supply. Afterwards, selective visceral and renal perfusion is established [641]. Also, thoracic segmental arteries can be perfused selectively (Fig. 29).

The infrarenal anastomosis is performed; then, the upper and lower body circulations are reconnected. At this point, the percentage of the remaining ECC is reduced to the amount needed for selective visceral and renal perfusion. The reimplantation sequence usually is the right renal artery, the superior mesenteric artery, CT and finally the left renal artery (Fig. 30).

**Specifics in thoraco-abdominal aortic aneurysm repair without extracorporeal circulation.** This approach, which usually affects TAAAs, is currently named type IV. The least common denominator is the possibility of performing an oblique anastomosis to the CT, superior mesenteric artery and the right renal artery, usually without selective organ perfusion. The left renal artery is then reinserted either directly into the main prosthesis or reconnected via a separate graft to avoid kinking. Selective kidney protection with cold saline or Bretschneider's solution can be considered [444].

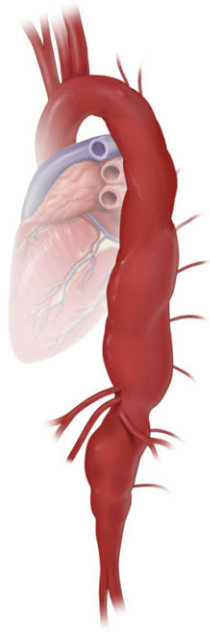
#### **Fenestrated endovascular aneurysm repair.**

*The principle of branched or fenestrated endovascular aneurysm repair.* Branched or fenestrated endovascular aneurysm repair (B/FEVAR) constitutes the contemporary first-line intervention for most thoraco-abdominal aortic pathologies and enables complete endovascular treatment of the descending thoracic and abdominal aorta (Fig. 31). The principle behind B/FEVAR is the exclusion of thoraco-abdominal or pararenal aortic pathology from the circulation by sealing in the proximal and distal aortic sealing zones at the level of the reno-visceral target vessels. Therefore, bridging stent grafts (BSGs) are implanted from the orifice of the main prosthesis to the target vessel. The BSGs ensure the sealing at the site of the aortic endograft and at the visceral or renal artery, and at the same time maintain the blood supply to the end organ. Thereby, sealing in the target vessel is effected by oversizing the BSG.

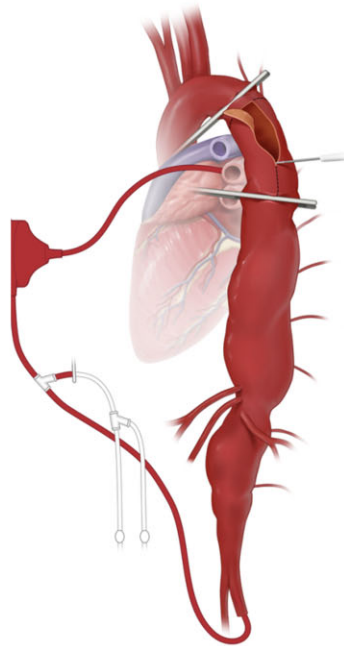
*Design and anatomical preferences for branched and fenestrated endovascular repair.* Both branched endovascular repair (BEVAR) and fenestrated endovascular repair (FEVAR) platforms comprise the orifice for the target vessel in the main graft. Whereas branches create a true overlap with the oversized BSG, the sealing in the reinforced fenestration is provided by the flaring of the balloon-expandable BSG within the main graft.

BEVAR is predominantly used for long bridging distances to the target vessels and offers increased stability of the BSG in the branched device, whereas the transfer distance  $\geq 5$  mm in fenestrated devices was associated with BSG instability including endoleaks, fracture and poor patency [642]. In terms of covered aortic length, FEVAR allows for a more distal landing in the thoraco-abdominal aorta in comparison to BEVAR, with the preservation of more intercostal arteries, which may be associated with a lower risk of paraplegia in comparison to branched endografts and which is particularly relevant for the treatment of pararenal pathologies with a suitable proximal landing zone right above or below the coeliac trunk [643].

1 Type II thoracoabdominal aortic aneurysm



2 Setting using left heart bypass



3 Setting using partial femoro-femoral bypass

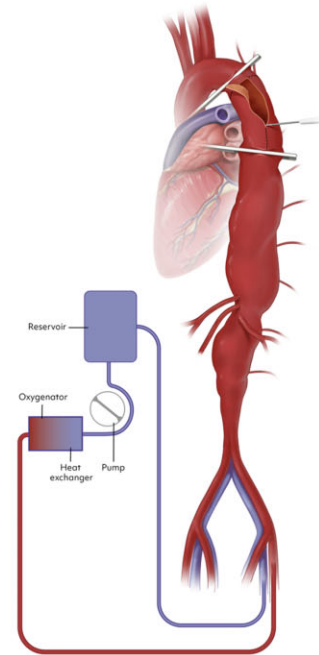
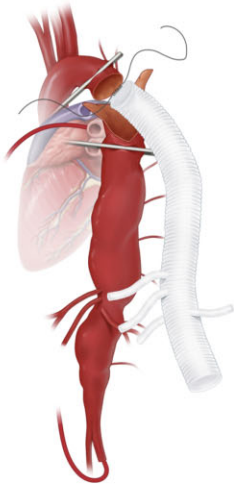
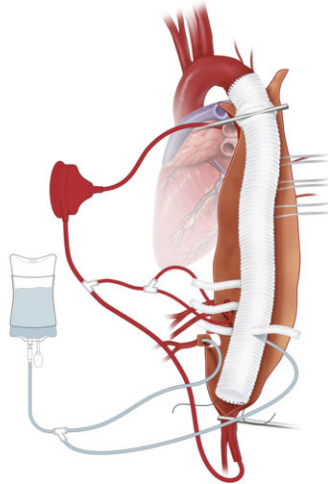


Figure 28: Technical details of proximal clamping strategies and extracorporeal circulation.

4 Sequential clamping strategy performing the proximal anastomosis with maximum preservation of distal perfusion



5 Distal perfusion using blood for viscerals and extremities as well as crystalloids for the renals, thoracic segmental arteries being blocked by Fogarty catheters to prevent steal allowing assessment of their contribution to spinal cord perfusion by MEPs/SSEPs



6 Same setting using blood perfusion for both, viscerals and renals

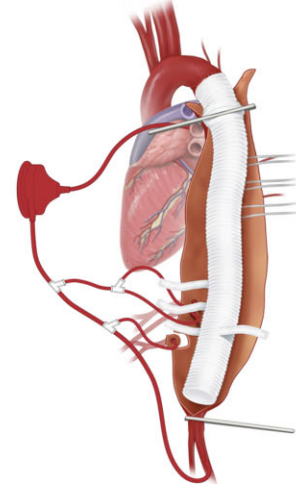
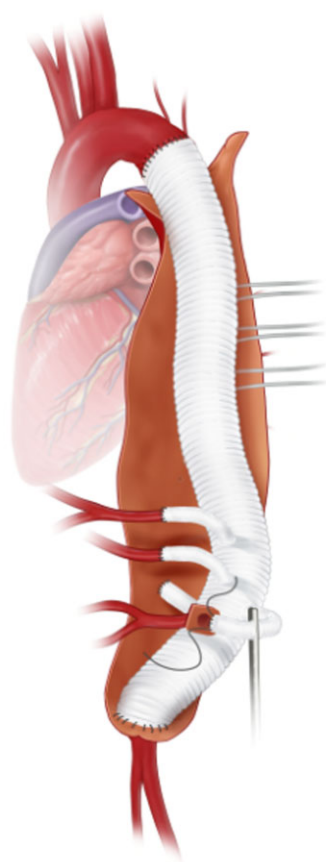


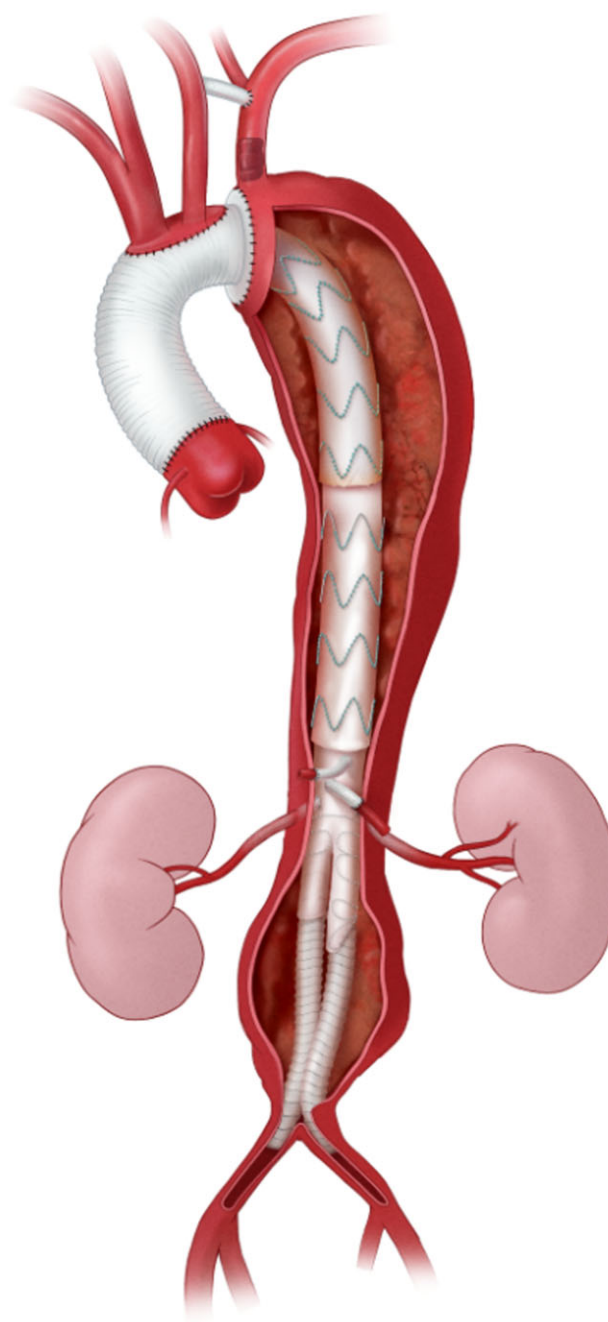
Figure 29: Technical details of sequential clamping strategy and distal perfusion using crystalloids and blood. MEPs: motor evoked potentials; SSEPs: somatosensory evoked potentials.

**7 Final surgical step showing selective reimplantation of both viscerals and renals to exclude as much native tissue as possible**



**Figure 30:** Anastomoses to the visceral and renal arteries.

*Results of branched/fenestrated endovascular aortic repair.* Branched/fenestrated endovascular aortic repair comprises the first-line treatment option for thoraco-abdominal and pararenal aortic pathologies with reduced postoperative mortality and morbidity including blood loss and pulmonary, myocardial and neurologic complications, which result in a shorter hospital stay and convalescence period in comparison to the complex supra-renal and thoraco-abdominal open repair [631, 632]. However, the reintervention rate after B/FEVAR is higher in the long term, which is due mainly to the BSG failure leading to end-leaks or end-organ failure. The risk of BSG thrombosis was proven for the renal BSGs, long BSG trajectory and low-diameter target vessels <4 mm [644–646]. The comparison of balloon-expandable and self-expandable BSGs showed no significant difference regarding long-term BSG stability [647, 648]. The BSG deployment sequence through the transfemoral access was associated with lower stroke and paraplegia rates in comparison to the upper extremity access in a considerable retrospective cohort [649]. Furthermore, the staged endovascular repair



**Figure 31:** Complete endovascular treatment of the descending thoracic and abdominal aorta.

of TAAAs was shown to reduce the risk of paraplegia. Consequently, intentional aneurysm sac perfusion strategies have been introduced in smaller series to improve neurologic outcomes [650].

## Infrarenal

**Recommendation Table 27: Therapeutic options: infrarenal**

Recommendations	Class <sup>a</sup>	Level <sup>b</sup>	Ref <sup>c</sup>
In patients with complicated PAU, dissection or intramural haematoma and in patients with mycotic aneurysm and pseudoaneurysm in the abdominal aorta, repair is recommended.	I	C	-
In patients with complicated PAU, dissection intramural haematoma, or pseudoaneurysm with suitable anatomy of the abdominal aorta, endovascular repair should be considered as the first option.	IIa	C	-
In patients with intact AAA with suitable anatomy for either open or EVAR, a shared decision-making process for each approach, including life expectancy, is recommended.	I	C	-
In patients with long life expectancy, open AAA repair should be considered the preferred treatment modality.	IIa	B	[651–654]
In patients with suitable anatomy and reasonable life expectancy, endovascular AAA repair should be considered the preferred treatment modality.	IIa	B	[651–654]
In patients with ruptured AAA undergoing endovascular treatment, a bifurcated device should be considered as preferable over an aorta-uni-iliac device if anatomically suitable.	IIa	C	-
Tubular EVAR without an iliac bifurcation stent graft implant is not recommended.	III	C	-

<sup>a</sup>Class of recommendation.

<sup>b</sup>Level of evidence.

<sup>c</sup>References.

AAA: abdominal aortic aneurysm; EVAR: endovascular aortic repair; PAU: penetrating aortic ulcer.

### Abdominal aortic aneurysm. Management of infrarenal abdominal aortic aneurysm (infrarenal neck length > 10 mm).

**Open surgery.** Nowadays, next to the immediate short-term goal of prevention of aneurysm rupture, the long-term outcomes of each treatment strategy should be carefully taken into consideration. A patient's and a surgeon's decision to proceed with elective treatment should be preceded by careful preoperative assessment of concomitant disease and general health status (e.g. cardiopulmonary, renal) because this condition carries a considerable postoperative mortality of around 5% [655–657].

A midline transperitoneal or retroperitoneal surgical AAA access route should be based on the surgeon's experience, preference and patient-specific aspects. Pooled data from 5 trials found no apparent differences in mortality or major complications except for higher rates of reintubation with a retroperitoneal access route [658]. Data from large registries concur with these findings regarding mortality; however, they differ regarding

complication rates associated with one or the other approach [659, 660].

The position of the cross-clamps and the choice of a tube or a bifurcated Dacron or expanded polytetrafluoroethylene graft (with or without antimicrobial coating) depend on the proximal and distal extent of the aneurysm. Left renal vein ligation does not seem to affect long-term renal function [661]. Involvement of the common, external or internal iliac artery (IIA) in the aneurysmal degeneration necessitates a distal anastomosis at the external iliac artery (EIA) with separate reimplantation of at least one IIA to avoid ischaemic complications of the pelvic region, colon and/or spinal cord [662]. Reimplantation of the inferior mesenteric artery remains a matter of debate because it was not associated with a lower incidence of ischaemic colitis in 1 study, whereas it was beneficial for selected patients in other studies (e.g. poor back bleeding, intraoperative colon ischaemia, large inferior mesenteric artery, IIA disease) [663, 664].

**Endovascular repair.** Endovascular aortic repair precludes aneurysm rupture by deploying a self-expandable stent graft in the aortic lumen. Endovascular aortic aneurysm repair is associated with a lower operative mortality (around 3%) compared to open surgery [665]. Before intervention, meticulous preoperative assessment of landing zones regarding length, diameter and morphology (e.g. angulation, tortuosity) is required for optimal sealing and fixation. Adherence to the instructions for use are necessary to achieve optimal results, although violations of the instructions for use have been reported in up to 40%. In such cases, patients and surgeons should be aware of the associated increased complication and overall mortality rates [666–668].

Traditional retrograde iliofemoral access can be safely achieved percutaneously or with a standard femoral cut-down. Both approaches have similar results, except for fewer seroma/lymphorrhoea for percutaneous access routes [669]. An oversizing of 10–25% is generally required, using bi- or trimodular aorto-bi-iliac devices. Coverage of accessory renal arteries does not seem to impact long-term renal function, but large (>4 mm) arteries may be managed with F/BEVAR [646, 670]. Coil embolization of the aneurysm sac or the inferior mesenteric artery may be beneficial to prevent type II endoleak [671, 672]. In concordance with open AAA repair, in case of iliac aneurysmal involvement, iliac branch devices could safely preserve IIA patency [673].

**Open surgery versus endovascular repair.** In equally eligible AAAs, the choice of treatment mainly relates back to the results of 4 important trials: EVAR-1, DREAM, OVER and ACE. Meta-analyses of these trials have shown that the early postoperative mortality advantage of EVAR was lost after 3 years follow-up, mainly due to aneurysm-related mortality [651]. EVAR-1 reported lower long-term survival after EVAR, whereas DREAM and OVER reported similar long-term survival rates for EVAR and open surgery [652–654]. In general, there was an increased reintervention rate in the EVAR group. These data support an open surgical repair strategy in patients with a long life expectancy (e.g. exceeding 10 years). Of note, long life expectancy is poorly defined; further data are needed.

Frail patients unfit for elective open repair could be protected against aneurysm-related mortality by EVAR, following the long-term results of the EVAR-2 trial [674, 675]. However, life expectancy did not differ between EVAR or optimal surveillance in these patients.

*Management of short-neck (infrarenal neck length 5–10 mm) and juxtarenal AAA (infrarenal neck length <5 mm).*

**Open surgery.** In complex AAA with involvement of renovisceral branches, a retroperitoneal access compared to a transperitoneal access has been associated with lower perioperative morbidity and mortality rates [675]. Perioperative mortality rates associated with open repair of specific complex AAA are generally not stratified for specific complex AAA subtype or treatment strategy and are reported to be around 4% [676].

In short-neck AAA (infrarenal neck length 5–10 mm), open surgery is comparable to open infrarenal AAA repair if an adequate cross-clamping site is present [677]. In juxtarenal AAA (infrarenal neck length <5 mm), perioperative mortality has been reported to be between 2.9% and 3.4% [43, 678, 679]. In these patients, cross-clamping is required above 1 or 2 of the renal arteries with or without selective renal perfusion. In all patients with AAA, a proximal anastomosis should be performed as close as possible to the lowest renal artery.

**Endovascular repair.** The optimal treatment strategy in these patients remains a matter of debate. Meta-analyses reported reduced morbidity rates with reduced or equal perioperative mortality rates after fenestrated EVAR compared to open surgery and a higher rate of EVAR reinterventions in the mid-term [677, 680, 681]. In complex AAAs, alternatives are represented by parallel graft techniques or branched/fenestrated EVAR [677, 682]. Endoanchors are reported as another adjunct to standard EVAR in short-neck AAAs because they may reduce type Ia endoleaks [683]. In any type of triple AAA, including infrarenal AAA, short-neck, and juxtarenal AAA, choice of treatment strategy may also depend on the surgeon's experience, access to certain imaging techniques and the case-volume of the respective AC.

**Management of ruptured abdominal aorta aneurysms.** Four trials were designed to elucidate the optimal treatment strategy in patients presenting with a ruptured AAA. These trials showed no differences in short-term outcomes between open surgery or EVAR if the patients were anatomically eligible for both types of treatments [684, 685]. More recent observational studies showed that results following EVAR were better in terms of ICU transfer, blood loss and reduced length of hospital stay and were potentially beneficial for women [684, 686]. Other relevant aspects were age >80 years, which may favour endovascular repair, and hostile anatomy, which may necessitate open surgery [687, 688]. Long-term survival seems to be comparable between EVAR and open surgery for patients discharged from the hospital [689].

**Management of mycotic abdominal aorta aneurysms.** Next to the administration of adequate intravenous antibiotic regimens to treat the aortic and aetiological systemic infections, surgical intervention should be performed irrespective of aneurysm size [690, 691]. Before 2010, open surgery was mostly performed most frequently, whereas over the last decades there has been an increasing trend towards EVAR, which was associated with reduced short-term mortality rates compared to open surgical graft replacement [691]. In this setting, concerns regarding postoperative surveillance, recurrent infections and reinterventions remain [692].

**Management of saccular abdominal aorta aneurysms.** Saccular lesions of the abdominal aorta may also have an increased risk of

rupture compared to fusiform AAA, which justifies lowering the threshold for intervention. Additional evidence is needed, but a recent study proved that EVAR was technically feasible with low mortality rates in the short and mid-term, no aorta-related mortality during follow-up and low reintervention rates [693].

**Management of abdominal aortic dissection.** Isolated abdominal aortic dissections are rare. Evidence remains limited to small series, and evidence from recent decades is lacking. Management can be conservative, open surgery or EVAR, and EVAR seems to be associated with reduced mortality and major complications [694].

## First branch vessels

**Recommendation Table 28: First branch vessels**

Recommendations	Class <sup>a</sup>	Level <sup>b</sup>	Ref <sup>c</sup>
In patients with involvement of the iliac axis in the disease process, the preservation of blood flow to at least 1 hypogastric artery is recommended.	I	B	[695]
In patients with isolated iliac artery aneurysms, elective treatment should be considered at a diameter threshold of a minimum of 35 mm.	IIa	B	[696, 697]
In patients with isolated iliac artery aneurysms, endovascular aneurysm repair may be considered.	IIb	B	[697–699]

<sup>a</sup>Class of recommendation.

<sup>b</sup>Level of evidence.

<sup>c</sup>References.

The preservation of iliac circulation to at least one IIA has been increasingly advocated in recent years [700]. The maintenance of antegrade blood flow to the IIA during iliac aneurysm repair was shown to reduce the risk of buttock claudication, colonic ischaemia, pelvic necrosis and erectile dysfunction [695, 700]. Furthermore, the IIA supplies the spinal CN, which is particularly important for the prevention of postoperative paraplegia, if extended aortic repair is planned [176, 701].

Iliac artery aneurysms are electively treated at a maximum vessel diameter of  $\geq 35$  mm [696, 697, 702]. The open repair of iliac aneurysms is performed through the retroperitoneal access or median laparotomy and the aneurysm is replaced by a conduit anastomosed proximally to the infrarenal aorta/common iliac artery (CIA) and distally to the EIA with the reimplantation of the IIA. Alternatively, a bifurcated graft can be used to revascularize both iliac arteries. The sacrifice of 1 IIA may be considered if the revascularization is technically challenging (e.g. calcified orifice) and the contralateral IIA is patent. Technically, the open repair of the iliac artery aneurysms may be hampered by the anatomical localization deep in the pelvis with the risk of intraoperative injury of the neighbouring anatomical structures including iliac veins, plexus or ureter [698].

The endovascular repair of the iliac artery aneurysm has shown reduced morbidity and mortality in comparison to open repair of elective and ruptured iliac aneurysms [697, 699, 703–705]. The iliac side branch (ISB) devices offer an approved treatment

option for iliac artery aneurysms with the preservation of the pelvic circulation and high technical success and patency rates [706]. In comparison to the traditional endovascular treatment technique [IIA embolization and distal endograft landing in the EIA], the ISB technique showed a lower rate of postoperative buttock claudication [707]. A recently published Cochrane systematic review reported the absence of RCTs comparing those treatment modalities [708]. In the case of the embolization and coverage of 1 IIA, the contralateral vessel should be preserved. Proximal coiling of the IIA trunk should be preferred rather than selective embolization of the branches. The communication between the IIA branches after embolization reduces the rate of postoperative buttock claudication [695, 700].

Concomitant AAA and CIA aneurysms or ectasia is found in approximately 40% of patients [709, 710]. If the CIA diameter precludes the distal sealing for EVAR, the use of ISB may create the distal EVAR landing zone in the EIA without sacrificing the IIA. Dilatation of the internal carotid artery and subsequent endoleak type Ib may occur after EVAR, particularly after the bell-bottom technique [711, 712]. At this stage, ISB may be used for the creation of the distal landing zone in the IIA and EIAs. Conversely, if the proximal landing zone in the CIA is not suitable for an isolated ISB treatment, EVAR may be used for the creation of the PLZ in the infrarenal aorta.

The sandwich technique comprises an alternative endovascular off-label method for the preservation of the IIA during the treatment of iliac artery aneurysms. The technique is based on 2 parallel grafts placed to the IIA and EIA and thus bears the risk of gutter endoleaks [713]. The evaluation of this treatment option has been evaluated in smaller cohorts with acceptable results [714]. Future studies are needed to compare this method to the established techniques.

## Endoleaks

### Recommendation Table 29: Therapeutic options: endoleaks

Recommendations	Class <sup>a</sup>	Level <sup>b</sup>	Ref <sup>c</sup>
Type I and type III endoleaks are regarded as treatment failures, and reintervention is recommended.	I	C	-
In the presence of a type II endoleak and aneurysm growth $\geq 10$ mm, treatment should be considered in both thoracic and abdominal pathologies.	IIa	C	-
In the presence of a type V endoleak (endotension without depictable endoleak on standard follow-up imaging), treatment should be considered in both thoracic and abdominal pathologies.	IIa	C	-

<sup>a</sup>Class of recommendation.

<sup>b</sup>Level of evidence.

<sup>c</sup>References.

The complete endograft sealing of the aortic pathologies in the healthy PSZ and DSZ ensures total thrombosis and depressurization, which are early markers of endovascular treatment success [715, 716]. The presence of the contrast agent between the endograft and the intimal layer of the excluded aortic pathology

is referred to as an endoleak and describes the incomplete exclusion of the pathology. The temporal endoleak classification comprises the terms 'primary' and 'secondary' endoleaks and refers to their existence already at the time of the procedure or their occurrence during the follow-up period, respectively. Depending on the origin of the detectable contrast agent, the traditional endoleak classification distinguishes 5 types (Fig. 32). Type I endoleak takes its origin in the proximal (Ia) or the distal (Ib) endograft sealing zone and comprises the blood inflow into the pathology between the endograft and the aortic wall. The cause of the primary type I endoleak may be associated with the discrepancy between the targeted and the ultimately achieved proximal or distal sealing length, the presence of thrombus or calcifications or insufficient oversizing of the endograft. Secondary type I endoleaks may be caused by the degeneration of the sealing zone, which can be observed after the sealing in the already dilated PSZ and DSZ [711, 717]. Type I endoleaks have a high risk of rupture and should be treated at the time of diagnosis [718].

Type II endoleaks arise from the aortic branches, which are situated in the covered aortic segment and lead to the retrograde perfusion of the pathology, although in the case of multiple branches, flow communication in the aneurysm sac with in- and outflow may exist. The sole existence of type II endoleaks does not imply the need for reintervention. Open conversions and ruptures associated with type II endoleaks are rare [719–721]; thus endovascular re-interventions (including particle and fluid embolization) may be weighed if substantial aortic growth occurs during the follow-up ( $\geq 10$  mm) [722]. Current data do not support the recommendation of pre-emptive branch coiling before EVAR [723]. Further studies are needed to prove the benefit of these prophylactic techniques [724].

Type IV endoleak is associated with the porosity of the device material and practically does not occur in the new generations of endografts [725]. Type III endoleaks may still lead to the severe perfusion of the aneurysm sac and rupture risk [718]. Type III endoleaks result from the fracture or separation of the endograft components and have an increasing incidence due to the spread of F/BEVAR, which include numerous BSG components [726]. Therefore, an expanded nomenclature for the F/BEVAR type III endoleak is necessary, as recently proposed [727]. According to the suggested classification, type IIIa endoleaks are due to the loss of the attachment of aortoiliac components and correspond to the definition of the traditional type III endoleak. Type IIIb indicates a component tear or fracture, and type IIIc endoleak describes the loss of attachment of the BSG within the aortic main graft [727]. Type Ic endoleaks can only be found after F/BEVAR and describe the distal seal loss in the target artery due either to the insufficient distal oversizing of the BSG or to the dilatation of the target artery during the follow-up period, which ultimately is the worst case that may result in the complete BSG pull-out. Type IIIa endoleaks affecting aortoiliac endografts have a sizeable complication rate and should therefore be repaired promptly. The same recommendation applies to the secondary BSG-related endoleaks, whereas an early type IIIc endoleak may be observed [727].

A type V endoleak or endotension describes a substantial aneurysm sac expansion ( $\geq 10$  mm) without the presence of the contrast agent in the aneurysm sac. The true cause of endotension is still unknown: It may be associated with the endoleaks that are not visible with the current imaging modalities. The

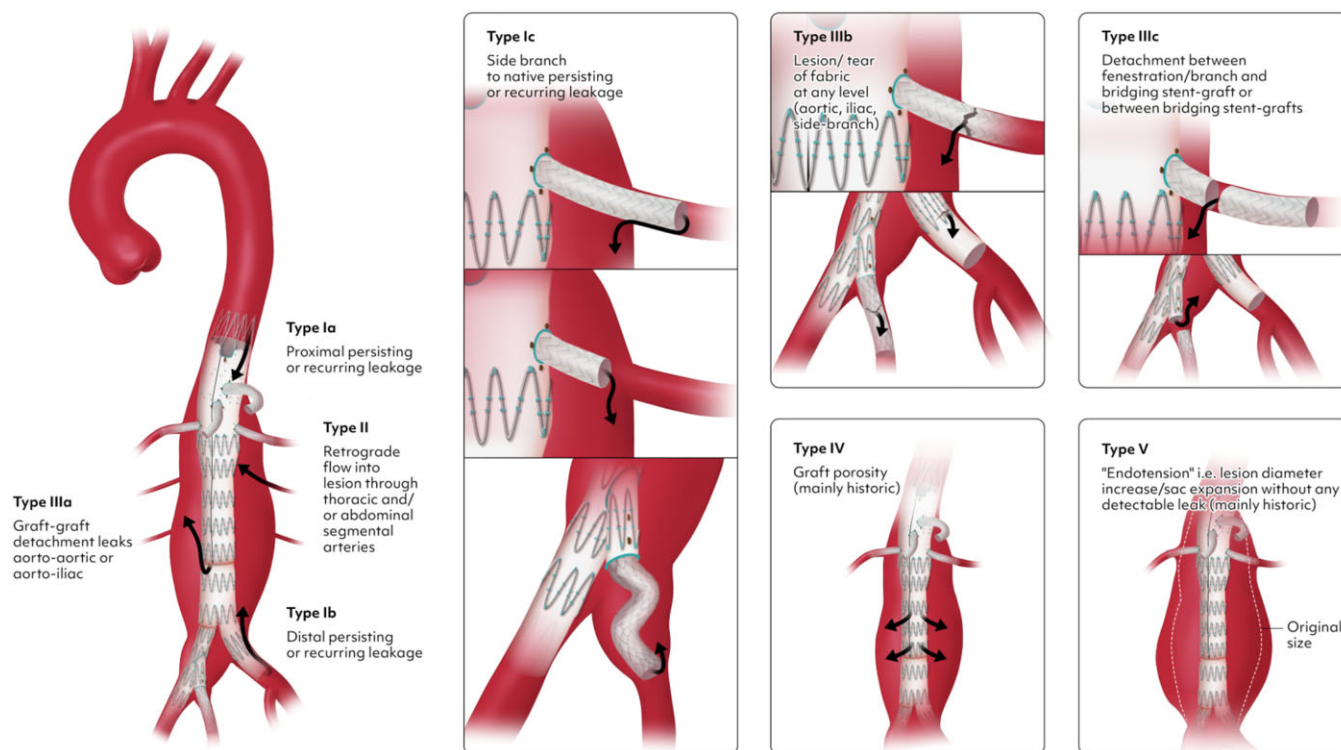


Figure 32: Classification of endoleaks.

conversion to open surgery is regarded as the treatment of choice due to the unclear pathogenesis of the endotension [728].

Further clarification is necessary regarding the endoleak classification in aortic dissections due to the morphologic peculiarity of the bi-luminal flow and the proposed definition of endoleak as the presence of blood flow between the endograft and the intimal layer of the aortic wall. Consequently, retrograde perfusion of the false lumen from the aortic branches or from the entry tears downstream from the distal endograft should not be referred to as endoleaks [128]. Furthermore, the reperfusion of the false lumen through the membrane rupture at the distal endograft end should be described as the dSINE and not as an endoleak [128].

**RARE CONDITIONS**

**Graft infections**

**Recommendation Table 30: Rare conditions: graft infections**

Recommendations	Class <sup>a</sup>	Level <sup>b</sup>	Ref <sup>c</sup>
It should be considered that patients with vascular graft infections be managed by a multidisciplinary team, including cardiovascular and vascular surgeons, imaging specialist, infectious diseases and microbiology specialist, in a facility with emergency access to these services.	IIa	C	-

Continued

In patients with a prosthetic vascular graft, with positive blood cultures without a clear source, multimodality imaging (CTA, <sup>18</sup> F-FDG PET/CT) to evaluate potential graft infection is recommended.	I	B	[729-731]
In patients with vascular graft infection who are fit for surgery, open surgical repair is recommended.	I	C	-
In patients with vascular graft infection and new-onset pseudoaneurysm or ongoing bleeding, emergency operative management is recommended.	I	C	-
In patients with vascular graft infection and active bleeding into the airway or gastrointestinal tract, endovascular treatment may be considered as a bridging strategy.	IIb	C	-
In patients with vascular graft infection who are haemodynamically stable without vascular discontinuity, scheduled open surgery should be considered.	IIa	C	-
<b>Surgical management</b>			
Surgical management of vascular graft infection, including excision of prosthetic material, local debridement and preferably orthotopic vascular reconstruction, is recommended.	I	C	-

Continued

In patients with suspected vascular graft infection undergoing open surgical repair, multiple samples for obtaining conventional culture, 16S RNA genomic analysis and pathological examination are recommended.	I	C	-
For surgical vascular graft infection management, liberal use of adjunct therapies such as delayed cavity closure, use of coverage flaps and continuous irrigation may be considered based on individual characteristics and local expertise.	IIb	C	-
<b>Postsurgical management</b>			
In patients who were operated on for vascular graft infection, a postoperative antimicrobial regimen for at least 6 weeks is recommended, if the tissue samples from retrieved specimens are culture positive.	I	C	-
In patients with intraoperative purulence, MRSA, or infection caused by a multidrug-resistant microorganism or <i>Candida spp.</i> , a 6-month regimen of antimicrobial therapy is recommended. In selected patients, life-long antibiotic therapy is recommended.	I	C	-
After surgical treatment of vascular graft infection caused by fastidious intracellular microbiological agents (e.g. <i>Coxiella brunetti</i> , <i>Mycobacterium spp.</i> , <i>Mycoplasma spp.</i> , <i>Bartonella spp.</i> ) extending the postoperative antimicrobial course beyond 6 weeks may be considered.	IIb	C	-
<sup>18</sup> F-PET/CT should be considered to decide on the duration of prolonged antimicrobial course for vascular graft infection, particularly in patients with a retained vascular graft.	IIa	C	-
In patients with vascular graft infection due to a low-virulence causative agent and favourable clinical/imaging features, medical management alone and close follow-up may be considered.	IIb	C	-

<sup>a</sup>Class of recommendation.

<sup>b</sup>Level of evidence.

<sup>c</sup>References.

<sup>18</sup>F-FDG: <sup>18</sup>F-fluorodeoxyglucose; PET: positron emission tomography; CTA: computed tomography angiography; MRSA: methicillin-resistant *Staphylococcus aureus*; RNA: ribonucleic acid.

The true incidence of prosthetic aortic graft infection remains unknown. Several reports estimate that its occurrence is between 1% and 6% of implants [732] and that it may develop at any time after the index operation.

Aortic graft infection is a severe condition, leading to a poor prognosis, prolonged hospital stay and resource consumption. For patients undergoing surgery, even in high-volume ACs, the reported mortality is frequently above 20% [733].

Contemporary management of such infections continues to exhibit significant variability among the limited and usually single-centre reports. Randomized clinical trials to support any valid recommendation remain absent in this field.

Vascular graft infection is a complex clinical problem, but timely diagnosis and appropriate treatment relying on a multidisciplinary team may maximize the chances of curation [734].

**Definitions and diagnostic criteria.** The clinical presentation varies significantly among patients, depending on the acuity of the infection, the microbiological agent and systemic involvement. Frequently, non-pathognomonic suspicious findings are present that trigger further diagnostic examinations.

Computed tomography angiography is a primary tool, even though sensitivity and specificity remain limited. Late-appearing perigraft fluid, gas and anastomotic leaks are suspicious findings that represent criteria for diagnosis of infection.

<sup>18</sup>F-fluorodeoxyglucose positron emission tomography (<sup>18</sup>F-FDG PET) alone or combined with CTA is another important tool for diagnosing vascular graft infections. Several uptake patterns, along with quantification of the maximum standardized uptake value and tissue-to-background ratio calculation, may help in making the diagnosis, in association with clinical features and laboratory tests. One of the major limitations of this technique is the variability of postoperative (physiologic) changes that occur throughout the months after the index operation and that could be falsely interpreted as positive findings. Unfortunately, there are still no clear-cut patterns and cut-off values that unequivocally set the diagnosis of infection in this challenging context [729].

The Management of Aortic Graft Infection Collaboration [730] defined major and minor criteria to assist in case definitions with an attempt to provide high sensitivity and specificity in cases with definitive diagnoses. However, despite the usefulness of these criteria, the risk of overdiagnosis remains [731].

Undisputable diagnostic confirmation of aortic graft infection relies on the presence of viable microorganisms obtained from surgically excised grafts, percutaneously aspirated perigraft fluid or appropriately processed samples from post-mortem examinations.

**General treatment.** Antibiotic treatment is the core therapeutic regimen for patients with infected aortic grafts. However, whether antibiotic treatment alone, for some prosthetic vascular infections, can achieve infection eradication, as seen in prosthetic valvular heart disease, is unknown and is usually reserved for patients unfit for surgery. Existing retrospective outcome comparisons between treatment modalities may suffer from significant biases that preclude extraction of meaningful data for clinical use. The presence of large purulent collections, vascular discontinuity, associated airway/digestive tract defects and infection with aggressive microorganisms (e.g. *S. aureus*) render this conservative option unlikely to be curative. Consequently, in addition to the medical therapy, concomitant aggressive surgical management is frequently necessary in order to remove all infected grafts [731].

In a proportion of patients with graft infection, the operation can be scheduled electively, allowing an appropriate preoperative workup. The timing of surgery for vascular graft infections in

the presence of new-onset vascular discontinuity or impending rupture is a surgical emergency [735, 736].

**Aortic surgical options.** A variety of approaches have been developed for the treatment of aortic graft infection, each one with its own advantages and disadvantages. There is no uniform treatment regimen to date.

Open surgery, when possible, consists of excision of the previously implanted graft, debridement and, if possible, anatomical vascular reconstruction. In unstable, bleeding patients the percutaneous insertion of covered stent grafts (in the descending thoracic or abdominal aorta) may allow bridge management to more definitive open surgery.

Multiple surgical specimens should be retrieved and labelled at the time of surgery for pathological examination and microbiological processing (including genomic sequencing to increase diagnostic yield). Identification of microorganisms is key to establishing a diagnosis and guiding optimal treatment. Currently, microorganisms can be identified in up to 98% of cases using a diversity of microbiological techniques [737, 738]. The therapeutic option should be individualized according to the severity and extension of infection and the general condition of the patient.

**Anatomical repair: in situ reconstruction.** Replacement of the infected vascular graft in the same position, after thorough debridement, preserves vascular continuity and minimizes physiologic alteration of blood flow. Concerns about reinfection due to implantation in a potentially contaminated field and perceived risk of recurrences have led to advocacy for extra-anatomical reconstructions. However, in the field of heart valve infective endocarditis, where prosthetic substitutes are usually implanted in culture-positive fields, accumulated experience has demonstrated that relapses are extremely infrequent. Anatomical reconstruction avoids extra incisions and manipulation of secondary vascular segments, which may translate into several functional benefits.

A variety of graft choices for replacement exist with no demonstrated superiority of one over the others. Cryopreserved allografts have been extensively used as a biological solution with a perceived low risk of reinfection, particularly in highly virulent microorganisms. Their pliability may also facilitate intraoperative haemostasis. Some of the major limitations are their availability, the risk of rupture related to quality of processing and calcific/aneurysmal degeneration [739–742]. Conventional synthetic polyester vascular grafts and rifampicin-bonded or silver-coated synthetic grafts have been used due to their availability and less technical demands. Reinfection rates remain above 10% in observational data [743]. Coated vascular grafts have no proven capacity to prevent infection [744].

Self-made xenopericardial (bovine) tube grafts represent a newer solution that has gained popularity over the past decades. Immediate availability of such tissue is a major advantage. Straight or bifurcated/branched grafts can be easily and rapidly constructed intraoperatively. Intermediate-term results have been reported as satisfactory for patency and reinfection [745–747]. Nevertheless, calcification of these grafts during follow-up

cannot be ruled out, and further data addressing this issue are needed.

**Extra-anatomic reconstruction.** This surgical strategy ensures that the new vascular reconstruction is separated from the contaminated field. The risks associated with this approach include aortic stump blowout and a significantly higher risk of lower limb ischaemia in distal aorta segment repair [748–750]. Retrospective multicentre data analysis of aortoenteric fistulization repair points at survival equivalent to that of anatomical reconstruction [751].

**Management of patients with aortoenteric or aortobronchial fistula.** Patients with thoracic graft infection may present with secondary communication between the thoracic aorta and surrounding structures (bronchus, oesophagus or other structures). This can occur after open surgical repair or endovascular grafting. Infection causing progressive erosion to such structures may lead to enteral bleeding or haemoptysis, which can range from mild to cataclysmic lethal forms. Graft infection involving such neighbour structures is uniformly fatal without open surgical treatment. It is important to remark that case reports and small case series (2–3 patients) constitute the available descriptive data that account for significant heterogeneity in the management of this highly morbid rarity [752].

Due to the location of the pathology, coverage with aortic stent graft or organ stenting to temporarily seal the defect before proceeding with definitive open repair has been adopted to prevent exsanguination [753]. For such fistulas, temporary TEVAR coverage should not be utilized as a sole therapeutic strategy [754]. Along with excision of the infected graft, different modalities of adjuvant surgery have been explored with variable outcomes. Concomitant radical oesophagectomy with proximal cervical oesophagostomy, pyloromyotomy and gastrostomy for nutrition have been widely accepted and remain the most successfully reported scheme [755, 756]. To re-establish peroral food intake oesophagocoloplasty is usually carried out months after the operation utilizing transversosplenic segment of the colon and intrathoracic route (usually retrosternal) [757].

However, anecdotal reports also exist on options for temporary transoesophageal drainage and conservative oesophageal management [758]. This as stated, should only be contemplated as a bailout in exceptional situations.

In the event of bronchial or lung parenchymal involvement radical pulmonary parenchymal resection in combination with graft removal and aortic reconstruction seems the most durable treatment strategy [630].

For all these fistulation scenarios, the adjuvant use of different coverage flap modalities has also been suggested. In the absence of further evidence surgeons within multidisciplinary teams should apply their best treatment choice, considering their experience, patient's age, and clinical condition.

**Adjunct strategies.** For large periaortic abscesses or collections, the option of preoperative percutaneous drainage to decrease the bacterial burden may be considered [759]. Retrieval of samples may aid in the diagnosis and facilitate antibiotic-directed

regimes before an elective operation. This option applies in the absence of recent haemorrhage or anastomotic pseudoaneurysm.

Multiple potential autologous tissues, such as pedicled omentum flaps and muscular tissue (e.g. intercostal, latissimus dorsi) and pleuropericardial fat, among others, have been used to protect the repair or to cover aortic stumps. These procedures have been proposed to improve vascularization, minimize reinfection and offer structural support [759].

Some surgical teams have advocated for the application of intense negative pressure (-100 mmHg) in the surgical field for several days to facilitate infection control and assist in tissue granulation. Mediastinal irrigation with continuous or intermittent antibiotic infusion has also been advocated for treating thoracic graft infection [760].

Delayed chest or abdominal closure allows examination of periaortic tissues and organs and facilitates further debridement and irrigation of any residual suspicious necrotic tissue. Irrigation with antibiotics or antiseptic solutions may help to reduce microbiological presence around the newly implanted graft. In such instances, omental filling can also be positioned [761].

The extent of some index operations may raise the question of whether all prosthetic material needs to be resected (e.g. root, ascending, arch replacement with FET). In certain situations, when operative risk is judged to be too high, a more conservative approach, resecting only the most involved part, has been utilized [762]. Although appealing, local resection is usually reserved for a specific group of patients with uncommon combinations of anatomy and extent of infection [763]. A case-by-case determination of the appropriate extent of surgical resection, depending on the patient's presentation, comorbid factors and imaging findings, has been suggested [764].

It is not uncommon for patients to present in a clinical condition that precludes any aggressive surgical intervention [765]. In such circumstances, a graft-preserving option and prolonged antibiotics may be a non-inferior option. These decisions need to be made by an experienced multidisciplinary team in an AC of reference. Percutaneous drainage can be helpful in such situations. Mediastinal perigraft debridement, if the clinical condition allows, can also be considered [766].

Duration of antimicrobial therapy is a matter of debate with different recommendations depending on the extent of surgical debridement. In most studies, after complete excision of the infected graft, at least a 6-week period is the most utilized regimen [737]. The decision to discontinue antibiotic treatment in patients undergoing conservative treatment for vascular graft infection is made based on clinical signs, inflammation parameters and imaging. Repeated follow-up <sup>18</sup>F-FDG PET/CT scans provide useful information for therapy monitoring of patients with vascular graft infections [767, 768]. However, <sup>18</sup>F-FDG PET/CT may still show increased <sup>18</sup>F-FDG uptake around the graft even due to sterile inflammation leading to false-positive interpretation and therefore unnecessary extension of antibiotic treatment [767].

Toxicity arising from a prolonged suppressive antibiotic is frequent. In fact, some studies suggest that in case of conservative treatment without graft removal, targeted antibiotic therapy is not necessary for life [769]. Discontinuation of antibiotic treatment should be closely monitored.

## Kommerell diverticulum

**Recommendation Table 31: Rare conditions: Kommerell diverticulum**

Recommendations	Class <sup>a</sup>	Level <sup>b</sup>	Ref <sup>c</sup>
In symptomatic patients with a high suspicion (dysphagia) of an aberrant subclavian artery and/or KD, CTA or MRI is recommended.	I	C	-
It is recommended to offer multiple measurements of the KD and the adjacent aorta to improve surveillance and facilitate operative decision-making.	I	C	-
In symptomatic patients with aberrant subclavian artery and/or KD, treatment is recommended.	I	C	-
In patients with aberrant subclavian artery and/or KD, treatment may be considered when the diverticulum orifice is $\geq 30$ mm and/or when the combined diameter of the diverticulum and the adjacent aorta (DAW) is $\geq 50$ mm and/or when the diameter of the aberrant artery is $\geq 30$ mm.	IIb	C	-
In patients with a symptomatic aberrant subclavian artery, transection of the vascular ring and transposition or bypass is recommended to release compression and to re-establish arterial circulation.	I	C	-
In young patients without significant comorbidities, open surgical treatment (via a thoracotomy and carotid-to-subclavian artery bypass) of KD is recommended.	I	C	-
In patients with an emergency presentation or who might not tolerate open surgery, hybrid (closed-chest) repair of the KD is recommended.	I	C	-
In patients with KD and indication for treatment, open surgical resection and endovascular repair with subclavian debranching may be considered depending on the patient's anatomical characteristics, age and general status.	IIb	C	-

<sup>a</sup>Class of recommendation.

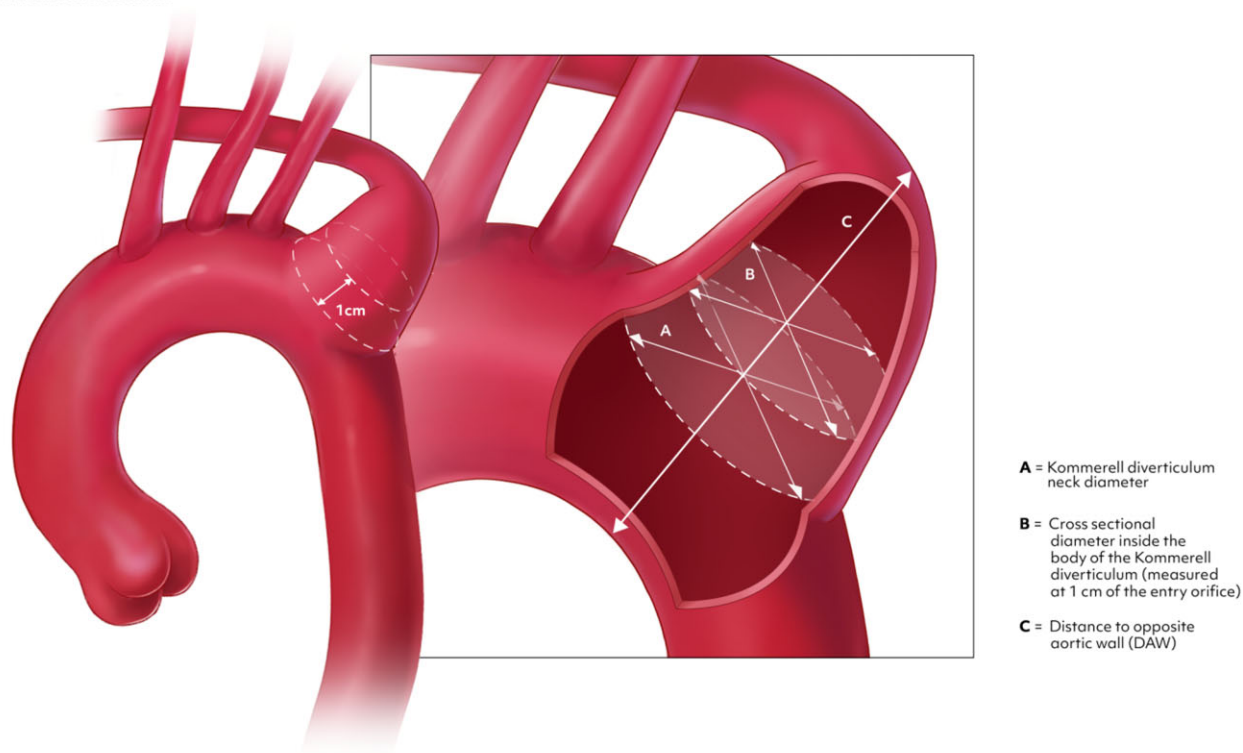
<sup>b</sup>Level of evidence.

<sup>c</sup>References.

CTA: computed tomography angiography; DAW: distance to the opposite aortic wall; KD: Kommerell's diverticulum; MRI: magnetic resonance imaging.

**Diagnosis and follow-up.** An aberrant subclavian artery with or without associated Kommerell's diverticulum (KD) is the most frequently encountered anomaly of the aortic arch. Kommerell's diverticulum is a remnant of the fourth primitive dorsal aortic arch. The reported prevalence in the general population is 0.5–1% [770, 771]. Nearly 20–60% of individuals with an aberrant right or LSA are associated with KD [772]. The diverticulum can occur in both the left and right aortic arch, from which an aberrant subclavian artery rises to the contralateral side. Most commonly, the aberrant subclavian artery passes posterior to the

## Kommerell diverticulum measurement



**Figure 33:** Recommended measurements of Kommerell's diverticulum.

oesophagus (80%), between the oesophagus and the trachea (15%), and rarely anterior to the trachea (5%) [771]. Dilatation of the origin of either a right or left aberrant subclavian artery is known as a KD. A KD occurs predominantly in females [773].

The most common presentation is dysphagia [771, 774]. Other symptoms include cough, chest pain, aspiration or recurrent pulmonary infection [771, 774, 775]. The overall incidence of symptoms is approximately 5%. Symptoms are the most common indication for intervention, followed by aneurysmic dilatation and vascular dissection [774, 776]. Rupture of a KD is rare [773]. Limited data on the natural history of the aberrant right subclavian artery are available. The specific KD diameter at which the benefits of repair outweigh the risks of complications (e.g. rupture) in an asymptomatic patient remains unresolved [777].

Some controversy exists regarding the actual size measurement with no clear consensus. The lack of consensus on the techniques used for measurement of the diverticular size has rendered the reported data relatively inconsistent and heterogeneous [777]. For consistency, multiple measurements are recommended (Fig. 33A–C), including the subclavian artery diameter at its orifice (size of the orifice) (Fig. 33A); the size of the combined diameters of the diverticulum and the adjacent aorta (Fig. 33B) [772]; and the measurement of the cross-sectional aberrant right subclavian artery diameter 1 cm distal to the ostium of the vessel (Fig. 33C) (DAW: distance to the opposite aortic wall), which might aid in the surveillance of vessel diameter changes [777].

**Indication for surgery.** Surgery for the treatment of symptomatic KD is a well-established indication, regardless of size or growth. Potential interventions, although complex, are associated with low periprocedural mortality [775, 776]. However, indications for prophylactic intervention in asymptomatic patients

remain based on limited single-centre reports and multicentric observational registries; hence the LoE remains low and variable among the guidelines [772, 774, 775]. In general, observation of asymptomatic KD and ASCA is appropriate [773].

In patients with a KD, preventive surgery is recommended when the risk of surgery is lower than the risk of rupture and/or dissection. However, there is an overall lack of data to specify a specific limit for intervention. Previous EACTS/European Society for Vascular Surgery consensus statements have recommended surgery in patients with subclavian arteries larger than 30 mm and a KD larger than 55 mm [136]. Current American College of Cardiology/American Heart Association guidelines recommend treatment when the orifice is larger than 3.0 and/or the diverticulum is larger than 50 mm and thereby follow the 2020 SVS clinical practice guidelines [141, 778]. Bath *et al.* [774] recently published a large, multicentre registry study including 285 patients and reported worse overall outcomes in these patients when symptomatic, an inherent risk of rupture in untreated patients and a comparably low risk of intervention. The low operative risk has also been shown in smaller single-centre studies or multicentre registries [776, 779]. Hence, a lower and reasonable threshold for intervention is proposed.

**Operative strategy.** Numerous interventional options have been reported to treat KD. Treatment can be open, endovascular or hybrid [772, 774, 776, 779]. A recent large registry has shown that open procedures are performed less frequently than endovascular approaches (36% vs 64%) [774]. The most common open approach in this registry was ligation/resection and subclavian transposition/bypass to release compression and to re-established arterial circulation through a thoracotomy [774]. Open aortic replacement of the aorta may be considered based

on anatomy in patients with a KD. In symptomatic patients (dysphagia, dyspnoea) operative management should guarantee full decompression of the involved surrounding structures. To meet that goal, if possible, open repair and resection of the vascular abnormality have been proposed. Direct repair through a thoracotomy under CPB with or without the use of HCA with selective carotid-to-subclavian artery bypass provides excellent exposure and represents an optimal management for this anomaly [780]. TAR via the FET procedure may be considered in the presence of concomitant aortic arch dilatation [779]. Endovascular approaches may be considered in patients with suitable anatomy, particularly in patients with increased operative risk. The most common endovascular approach was TEVAR and carotid-subclavian bypass [774]. All treatment modalities can be performed safely with low rates of mortality, stroke and a high likelihood of symptomatic relief [772, 774, 776, 779]. Reinterventions are more common in patients receiving endovascular treatments compared to open surgery [774]. In young patients, given the relatively low incidence of comorbidities, open repair through a thoracotomy is preferred due to its durability and efficacy in symptom relief [774, 776].

## Coarctation of the aorta

**Recommendation Table 32: Rare conditions: coarctation of the aorta**

Recommendations	Class <sup>a</sup>	Level <sup>b</sup>	Ref <sup>c</sup>
In patients with a diagnosis of CoA, primary or recurrent and with clinical significance, treatment is recommended.	I	C	-
Asymptomatic patients with a diagnosis of CoA but in whom there is a systolic gradient across the stenosis at rest (>20 mmHg) and/or SBP difference above 10 mmHg combined with coarctation-attributed HF and/or proximal hypertension should be considered for open or endovascular repair.	IIa	C	-
Regardless of the pressure gradient, patients with documented HTA with >50% aortic luminal narrowing in relation to the aortic diameter at the level of the diaphragm (based on MRI, CT or invasive angiography measurements) should be considered for treatment.	IIa	C	-
For adult patients with a diagnosis of CoA, referral to a specialized aortic centre should be considered.	IIa	C	-
In patients with a diagnosis of coarctation of the native thoracic aorta as well as after previous repair and suitable anatomy, endovascular repair should be considered as an alternative to open surgical repair.	IIa	C	-
In patients requiring coarctation re-repair, extra anatomical bypass from the ascending to the descending aorta may be considered at the time of concomitant cardiac repair.	IIb	C	-

<sup>a</sup>Class of recommendation.

<sup>b</sup>Level of evidence.

<sup>c</sup>References.

CoA: coarctation of the aorta; CT: computed tomography; HF: heart failure; HTA: hypertension arterialis; MRI: magnetic resonance imaging; SBP: systolic blood pressure.

**Burden of disease.** Coarctation of the aorta is a congenital heart defect that occurs in approximately 1 out of 2900 live births, with a 4/1 male-to-female ratio, even though its prevalence is underestimated [781–783]. It appears when blood flow in the pulmonary trunk is higher than aortic flow in the early phases of development. Coarctation of the aorta is the seventh most common congenital heart defect [784] and is frequently associated with other cardiovascular malformations such as BAV, aortic arch hypoplasia, mitral valve abnormalities, Shone complex, patent ductus arteriosus and atrial or ventricular septal defects [782]. Coarctation of the aorta is classified into 2 forms according to its relationship with the ductus arteriosus: preductal, with early onset presentation, and post-ductal, which is usually diagnosed in older children or young adults. The most common presentation in young adults is upper extremity hypertension. In the latter, differential systemic blood pressure between upper and lower extremities can often exceed 20 mmHg [785].

**Diagnosis.** Patients with CoA should undergo TTE for initial assessment [786, 787] because this modality provides functional and anatomical information regarding site, structure and extent of CoA, LV function and the presence of hypertrophy and concomitant cardiac abnormalities. The best view to visualize the aortic isthmus, and therefore the site of CoA, is a suprasternal view [788].

Flow turbulence can often be appreciated on colour-flow Doppler with increased peak systolic velocity with prolonged diastolic extension. The 2018 American Heart Association/American College of Cardiology Guidelines for the Management of Adults with Congenital Heart Disease defined significant native or recurrent CoA when the upper extremity/lower extremity resting peak-to-peak gradient is more than 20 mmHg or more than 10 mmHg plus either decreased LV systolic function, aortic regurgitation or collateral flow [786]. However, according to the 2020 European Society of Cardiology Guidelines for the management of adult congenital heart disease, Doppler gradients are not useful for disease extent quantification [787]. If extensive collateral arteries develop with long-standing disease, gradients are not reliable and are often underestimated [787]. In the case of suboptimal acoustic windows, cardiac MRI [789, 790] is recommended.

Computed tomography angiography is the preferred imaging modality for preoperative assessment because of its short acquisition time and excellent spatial resolution [791], as well as a valid follow-up method. Thin-section axial images with post processing such as multiplanar views, maximum-intensity projections and volume rendering allow for precise assessment of aortic and access axes assessment. In particular, essential anatomical information includes the site and degree of CoA, relationships with great vessels and assessment of collateral circulation. In addition, head CTA is recommended for exclusion of intracranial aneurysms, which are often present in patients with CoA and account for 5% of deaths [792].

Patients with CoA require life-long imaging surveillance, whether operated on or not. Magnetic resonance imaging techniques are a useful tool in reducing life-long radiation while providing adequate spatiotemporal resolution and can substitute CTA. In addition, 4D flow MR can provide additional insights into the COA abnormal haemodynamics involved [790].

**Treatment.** Before the introduction of surgical treatment, the mean age of death was 34 years, with a quarter of patients dying

during their second decade of life [793]. Gross [794] and Crafoord [795] performed the first open repair for CoA independently in 1944, preceded by the *in vivo* animal experiments of Blalock and Park [796]. Balloon angioplasty for CoA was first performed in 1982 [797], though open repair has been the gold standard of treatment for many years. Over the last decade, catheter-based treatment has gained momentum and is now an alternative treatment in adolescents and adult patients, with excellent results [798, 799]. More recent studies highlighted the effectiveness and complications during follow-up of open surgical, hybrid and endovascular repair for treating CoA [800]. However, stenting is not usually an option for neonates, infants and children. The latter are treated with open surgical repair techniques, such as end-to-end repair [794, 795], patch aortoplasty [801–803] or interposition grafting [804].

**Endovascular intervention.** Although self-expandable stents are still considered a valid therapeutic option, most interventionalists favour balloon-expandable stents because their radial force can overcome elastic recoil in CoA [805]. Bare metal stent fracture has been reported in up to 24% in the COAST II trial [806, 807]. Covered stents seem to better distribute radial force to the stent struts, thereby reducing stent fracture. Moreover, they offer the possibility to treat narrower lesions because they protect against vascular injury. Bare metal stents can be used in selected patients with a high risk of blocking vital aortic branches or in those with milder narrowing [808]. Currently, bioresorbable and custom-made stents are also under investigation but have not reached the clinical arena [807, 809]. Procedural technical success is assessed in 2 ways: anatomical, with a post-stenting remaining stenosis of <30%, and haemodynamic, with a residual transstenotic gradient of <10 mmHg. Additionally, anti-hypertensive treatment is often necessary, even after endovascular treatment.

**Open surgery.** Surgical treatment options include direct end-to-end repair, frequently performed in infants and younger patients [794, 795, 810, 811], patch aortoplasty [801–803], extra-anatomical bypass from the LSA to the descending aorta or, typically in redo surgery, from the ascending aorta distal thoracic or abdominal aorta [800, 804, 812–814]. Surgical repair techniques are associated with high technical success and low mortality rates. However, reinterventions are often necessary, thus making imaging and clinical follow-up necessary [812, 814, 815]. Generally, in patients affected by CoA, long-term survival is reduced compared to that of sex- and age-matched populations [812].

## Inflammatory disease of the aorta

Inflammatory diseases of the aorta are uncommon, and our level of understanding is still limited. A number of conditions with protean manifestations are usually grouped as a mixed catch-all including Takayasu arteritis (TA), giant cell arteritis (GCA), Behcet disease and immunoglobulin G4-related aortitis [816].

Due to a variety of clinical presentations, imaging patterns and histologic descriptions, classifications and interpretations of findings are frequently difficult [817]. Histologic examination of surgical specimens is the fundamental tool to appropriately establish a diagnosis of aortitis with a yield of around 4% in the scanty surgical series with some numbers [817]. The general term 'aortitis' includes non-infectious diseases as well primary aortic infections

of different kinds. It seems that primary aortic infections are mostly bacterial and related to sites of calcification, old vascular grafts, penetrating ulcers and areas of turbulent flows [817], in line with what is hypothesized for the aortic valves [818, 819]. In other words, and according to previous discussions, the border between inflammation and infection is blurred. Furthermore, research has been underway for more than a couple of decades to depict eventual relationships between infection and aortic diseases, including aneurysms and atherosclerosis [820–825]. Moreover, aortitis in general is a heterogeneous group of diseases with protean manifestations and age presentations with a number of shared features across the spectra of ages and pathologies [826].

The surgical interest in inflammatory disease of the aorta relies on the potential complications that include aortic aneurysms and dissections, penetrating aortic ulcers, IMHs and eventual rupture [827, 828] like those for any other aortic disease discussed in these guidelines. Giant cell arteritis and TA are the most common inflammatory conditions of the large-calibre vessels, and there are a number of less frequently diagnosed causes of aortitis. The diagnostic criteria were well outlined a decade ago [829]. The actual incidence and prevalence of inflammatory aortic diseases is difficult to establish; however, the yield of surgical series ranges around 3–5% [817, 830]. Age at onset seems to identify that subset of patients with a more aggressive pattern of aortic and peripheral vascular disease [831] in all major forms of inflammatory aortic disease. Knowledge accumulated in the past decade suggests that imaging currently plays a major role in the diagnosis and follow-up of inflammatory diseases of the aorta. Computed tomography and <sup>18</sup>F-FDG PET are useful for the diagnosis of suspected inflammatory disease of the aorta and for the evaluation of therapy during the follow-up period, all this being widely recommended [141]. Although the mainstay of therapy in these infrequent conditions is surgical treatment, the role of adjunctive therapies like systemic steroids is not fully elucidated regarding postoperative outcomes; recent collective experience does not confirm a negative impact of steroids on surgical outcomes [832].

## Takayasu arteritis

Takayasu arteritis is a non-specific inflammatory disease, a panarteritis of unknown aetiology and predominant female presentation that involves the aorta and its main branches [833, 834]. Takayasu arteritis is more prevalent in Japan and other Asian countries, South America and Mexico [835–837]. It was first described by the Japanese ophthalmologist Takayasu [838]. As stated, its aetiology is still unknown, but research suggests that an autoimmune process is responsible for the genesis of the disease, which results in destruction of the elastic media layer [839]. Its diagnostic criteria were proposed by Ishikawa in a landmark contribution [840]. The Numano classification, which considers 6 types of angiographic pattern in TA, has greatly assisted in the reporting of TA, outlining ethnic differences in arterial lesion topography [841].

Most of the literature available so far refers to isolated case reports or short surgical series covering all vascular territories and those producing substantial information cover long periods of time. Valve disease in the form of aortic regurgitation requiring valve replacement is also uncommon [842, 843]. Active inflammation, confirmed on histologic examination of surgical

specimens, confers an increased risk for late valve detachment in the case of aortic valve and root replacement. Other series addressed major challenging issues like aortic arch involvement in TA [844]. Involvement of the pulmonary arteries and its corresponding surgical treatment with a variety of bypass techniques has also been reported [845, 846]. Surgical therapy for supra-aortic and multi-arterial level obstruction in TA has also been performed through open and end-vascular techniques. Although failure rates are high, the open surgical approach offers better follow-up latency and a lesser rate of vascular complications [847–850]. The indications for peripheral vascular reconstruction in patients with TA must be carefully individualized [851]. As reported in one of the largest series available, complex aortic obstruction like the mid-aortic syndrome can also cause morphologic changes in the left ventricle, which improve with appropriate surgical bypass treatment [852].

Medical treatment of TA has also evolved over time. Although glucocorticoid therapy has been the mainstay of medical therapy for decades, new drug regimens have been introduced in clinical practice. The so-called synthetic disease-modifying antirheumatic drugs, also known by the acronym DMARD (methotrexate, azathioprine, mycophenolate and others) in combination with low-dose steroids, seem to stabilize the disease by reducing the inflammatory component. However, their complications have to be taken into consideration [853].

## Giant cell arteritis

Hutchinson first described GCA, a granulomatous inflammatory disease of medium- and large- sized arteries in 1890 [854], and Horton described it histologically in a case of inflamed temporal artery in 1932 [855]. Further characterization was available in the mid-1940s [856]. It is a chronic condition that mostly affects adults over the age of 50 with a female predominance and familial clustering. Post-mortem studies confirmed a prevalence in the general population of 1% [857]. In a small cohort of 46 patients, the prevalence is 1–3 cases per 10 000 adults over 50 years old. Aortic dissection is a major complication and is the initial form of presentation of GCA in about 40% of the patients [857]. Being a disease of adults, its incidence increases with age. Due to previous descriptions, the temporal artery biopsy has been considered the gold standard for its diagnosis [858, 859]. Aortic dissections, aneurysms and vascular rupture may develop. Symptoms of aortitis defined by the presence of chest, dorsal, lumbar or abdominal pain or unknown aortic insufficiency with recent dyspnoea unexplained by any other cause than aortitis (musculoskeletal degenerative disease, atherosclerotic or other AD) may herald an AAE [860]. Giant cell arteritis, although infrequent, seems to be associated with escalating costs of care [861].

The surgical treatment of GCA entails radical resection of the ascending aorta and aortic arch if indicated, which are the vascular segments most frequently involved by the disease, and according to the topography of the lesion. As in the case of TA, there are no large series of patients undergoing surgery. Most of the literature is based on isolated cases. Reported findings at operation confirm a typical gross external cobblestone appearance of the aorta [862, 863]. Histological analyses confirm disruption of the medial elastic continuity. Recent data suggest that aortic atheroma, aortitis of the descending thoracic aorta on imaging and a history of aortic surgery, stroke or upper or lower limb ischaemia at diagnosis are associated with the development

of symptomatic vascular complications [864]. Aortic dissection is a major complication and is the initial form of presentation of GCA in about 40% of the patients [865]. Considering the patterns of presentation, imaging follow-up is recommended for all patients with GCA and other inflammatory ADs [866]. Outcomes of surgery are excellent, especially in patients undergoing elective procedures [867].

## Infectious aortitis

The term ‘infectious aortitis’ (IA) currently describes the infections of the native aortic tissue. It is steadily replacing the previously established and universally used ‘mycotic’ coined by William Osler in 1885 [868], while addressing the embolic nature of endocarditis. Infectious aortitis results from septic embolization, haematogenous spread from distant sources or contiguous spread from adjacent organs. As generally agreed, treatment involves, like in other infectious conditions, parenteral broad-spectrum antibiotics and eventually open surgical repair if a source has been identified. This treatment is currently recommended worldwide [141]. This treatment notwithstanding, there is little agreement about diagnosis and reporting, which has been recently addressed by an expert panel [869].

Infectious aortitis is a serious and frequently life-threatening condition that, if untreated, requires prompt diagnosis and aggressive therapy. Initial empiric antibiotic therapy followed by surgical resection of the involved arterial segment and *in situ* reconstruction whenever possible or the patient’s condition allows is the preferred approach. Although IA has classically been regarded as an embolic complication of infective endocarditis, a diversity of bacteria and fungi are associated with it [870]. Syphilitic aortitis used to be frequent in the beginning of the 20th century, but microbiology has dramatically changed during the antibiotic era, and syphilitic aortitis is now extremely rare [871, 872]. Some of the most commonly associated pathogens are now *Staphylococcus aureus*, *Streptococcus* species and *Salmonella* spp, which is the main reason why empirical antibiotic therapy has to address gram-positive cocci and gram-negative rods before a microbiological diagnosis is made. Infectious aortitis is an uncommon condition even in the subset of patients with inflammatory diseases of the aorta, although its actual prevalence and incidence may vary according to specific populations [873]. Despite a growing variety of pathogens, cardiovascular risk factors and immunosuppression seem to play a role [874, 875]. This observation applies to the majority of patients with IA, because it occurs with fungal, tubercular or other mycobacterial infections [588, 875, 876]. Because IA is an uncommon condition and the available literature is, as for most inflammatory diseases of the aorta, based on case reports or short institutional series, many different pathogens have been reported [875].

Diagnosis of IA currently relies, like other forms of aortitis, on advanced imaging techniques. Computed tomography and MRI help define the thickening of the aortic wall, size an aneurysm if present and detect complications like contained rupture [875]. Furthermore, the combination of imaging techniques such as TOE in the case of the thoracic aorta facilitates surgical planning. The multimodal approach is widely accepted to improve diagnostic accuracy [729, 877]. The diagnostic accuracy of <sup>18</sup>F-FDG PET/CT is high and higher than that of contrast-enhanced CT. Although PET/CT demonstrates an excellent sensitivity, its

specificity may be hampered because of false positive findings [878]. Moreover, PET/CT has a significant impact on patient management that is more pronounced with baseline than with follow-up examinations and has value in the follow-up of patients with infectious native aortic aneurysms at different levels [879, 880].

The surgical principles in IA are the same as those in other infectious/inflammatory processes such as infective endocarditis. Then, surgery aims to debride and remove as much inflammatory/infected tissue on gross intraoperative examination and to restore vascular anatomy, preferably through the anatomical route [141]. Surgery addresses major complications like rupture and helps control sepsis if present; however, one should keep in mind that in-hospital mortality is significant [881]. Late outcomes are favourable regardless of the topography of the disease [690, 882]. Open surgery continues to be the standard of treatment in IA [141]. However, for specific subsets of patients, non-resectional treatment has been proposed [883], including antibiotic therapy alone and antibiotic therapy with endovascular repair. A hybrid or bridging approach with endovascular therapy in mandatory combination with antibiotic therapy is also used with controversial results. Therefore, these strategies are limited to patients unfit for open surgery. A nationwide survey in Sweden estimated acceptable outcomes in the short and long term with endovascular repair of thoracic infected aneurysms [884]; however, they expressed concerns about reinfections and reoperations. A systematic review suggested that endovascular repair of infected abdominal aortic aneurysms appears to be associated with superior short-term survival compared with open surgical repair; therefore, it may become an alternative therapy, considering the associated infection-related complications [691]. However, another recent meta-analysis concluded that, although operative and 1-year survival were similar between open surgical and endovascular repair, recurrent infection was more frequent after endovascular repair, which is a major limitation that also supports the critical role of lifelong surveillance [692].

## AORTIC DISEASE IN WOMEN: PREGNANCY AND POST PARTUM

**Recommendation Table 33: Aortic disease in women: pregnancy and post partum**

Recommendations	Class <sup>a</sup>	Level <sup>b</sup>	Ref <sup>c</sup>
<b>Delivery in pregnant patients with aortopathy</b>			
In pregnant patients with a history of aortic dissection, C-section is recommended.	I	C	-
In pregnant patients with an aortic diameter of <40 mm, vaginal delivery is recommended.	I	C	-
C-section should be considered in pregnant patients with a diameter ≥45 mm of the aortic root or ascending aorta.	Ila	C	-
<b>Surgery before pregnancy in women with aortic disease</b>			
Aortic repair before pregnancy is recommended in patients with Marfan's syndrome and aortic root diameter ≥45 mm.	I	C	-

Continued

With an aortic root diameter of 40–45 mm, aortic repair before pregnancy may be considered in the presence of risk factors for aortic dissection (family history or rapid growth > 3 mm/year).	I <b>b</b>	C	-
<b>Pregnancy in patients with aortopathy: dissection and surgery in pregnancy</b>			
Urgent aortic repair is recommended with foetal monitoring in patients with acute type A aortic dissection during the first 2 trimesters.	I	C	-
In patients with acute type A aortic dissection during the third trimester, urgent caesarean delivery immediately followed by aortic surgery is recommended.	I	C	-
OMT is recommended in patients with acute type B aortic dissection during pregnancy unless complications develop.	I	C	-

<sup>a</sup>Class of recommendation.

<sup>b</sup>Level of evidence.

<sup>c</sup>References.

OMT: optimal medical therapy.

## Aortic disease in women

Overall, ADs are reported to occur less frequently in women. In a recent report [885] of the DANCANVAS I & II trials, which offered cardiovascular screening with CT scans to 14 989 Danish men and women aged 60–74 years, the prevalence of aneurysms at the levels of the ascending, arch, descending and abdominal aorta was 0.1%, <0.1%, 0.1% and 3.7% in men and 0.1%, 0.0%, 0.1% and 0.4% in women, respectively. A large study in Canada (2005–2015) that investigated events involving the thoracic aorta showed that 29% of TAA repairs and 39% of dissections were observed in women, with 45% of aorta-related deaths [886]. In the German Registry for Acute Aortic Dissection type A, which includes 3380 patients throughout the country (2006–2015), women were half less affected by AD. Compared to men, they were older at the age of presentation, with lower rates of extension to the abdominal aorta and malperfusion and with similar outcomes at 30 days [887]. One specific presentation of aortic dissection in women is during pregnancy, a period when the risk for such complications is substantially increased: The incidence of AD is reported to be 1.45/100 000 during pregnancy compared to 0.12/100 000 when not gravid [888]. The maternal mortality due to AD is high, up to 30%, whereas the foetal mortality can reach 50% [889]. Another particular clinical presentation in women is related to the increased risk of AD in case of Turner syndrome [890].

The lower rates of aneurysms, especially at the level of the abdominal aorta, should be tempered by the fact that a similar aortic diameter threshold (of 30 mm) in both genders may underestimate the actual prevalence of aneurysms in women. The gender disparity in AAA prevalence is much less when a definition of >1.5 times the suprarenal aortic diameter is used, rather than a unique threshold of 30 mm [891, 892]. Indeed, the diameter of the abdominal aorta in women is on average 2–3 mm smaller than that in men [891, 892]. At a given diameter, the risk of AAA rupture is 3- to 4-fold higher compared to that in men [423, 893]. The average diameter of a ruptured aorta is around

50 mm, which is 10 mm less than the same diameter in men [423]. This difference has opened the debate on whether a similar diameter threshold should be used to decide intervention in women and in men [894].

In the Global Registry for Endovascular Aortic Treatment, which includes 3758 patients, women were treated at an older age and had a more hostile AAA anatomy, with higher rates of redo interventions [895]. The reported results regarding gender differences in outcome after elective intervention for AAA are contradictory: In a large US database, the 10-year mortality was 14% lower in women than that in men after EVAR, whereas the survival was similar after open surgery [896]. In contrast, data issued from a contemporary Dutch national registry show an increased mortality after AAA repair in women, but this is related to excess mortality after surgery, with comparable death rates between the 2 genders after EVAR [897].

## Pregnancy

The condition of pregnancy is associated with haemodynamic and hormonal changes and is considered to constitute some risk for pregnancy-associated arterial and aortic dissection in a woman with a known aortopathy [898]. Such arterial dissection may be seen throughout pregnancy or in the post-partum period of up to 1 year, with a peak around the third trimester and up to 3 months post partum. Women with known aortopathy including hereditary connective tissue disorders (Marfan syndrome [899, 900], Loews–Dietz syndrome [390, 901], vascular Ehlers–Danlos syndrome [389], HTAD and Turner syndrome) are at risk of pregnancy-related vascular dissection. Type A aortic dissection usually exhibits this pre-existing aortic root dilation whereas TBAD may occur without known aneurysmatic changes [899, 901].

It is recommended that women with a risk for aortopathy having a planned pregnancy undergo imaging including echocardiography, MRI or CT, to elucidate the entire vascular condition. Surveillance imaging throughout pregnancy and several weeks post partum using ultrasound is recommended to monitor for congenital changes in aortic size. In women with normal aortas and low risk, vaginal delivery is potentially an option with efforts to lessen haemodynamic stress during the second stage of labour. Women at increased risk of aortic complications or known significant aortopathies are typically recommended to undergo a caesarean delivery [900, 902].

In women with one of the previously mentioned hereditary conditions, or a known aortopathy, pre-pregnancy genetic counselling, baseline aortic imaging and understanding of the potential risk of dissection with the aim of shared decision-making with the patient are recommended.

## Assisted delivery in pregnant patients with a risk of aortic dissection

Based on recent observational evidence, the risk of type A dissection in the context of a pregnancy in Marfan patients is related to the pre-pregnancy diameter of the aortic root with a relatively low risk of 1% for dissection and a root dimension of 40 mm or less, and an increasing risk with an aortic dimension surpassing >45 mm [903, 904]. Any evidence of progressive dilation of the aortic root and uncontrolled hypertension also determine an increased risk of vascular complications with pregnancy [905,

906]. In the grey zone between 40 mm and 45 mm of root dimension, shared decision-making with a patient is required [907, 908], because recommendations are not clear: The World Health Organization classification for cardiovascular risk for women with Marfan syndrome and moderate aortic dilation is risk class III, whereas those with an aortic root diameter of >45 mm are considering to be in risk class IV [909]. Because of the increased risk of aortic dissection, pregnancy should be avoided when the aortic root is >45 mm and pre-emptive repair should be considered.

Type B dissection in the context of pregnancy is often associated with connective tissue disorders: For instance, 20–40% of cases are seen in the context of Marfan syndrome and may happen without pre-existing aortic dilatation [902, 905, 908]. Vascular and aortic dissection may also occur after delivery in the post-partum period, most likely within 3 months, but in rare cases up to 1 year [910]. Patients at risk in their families should realize a slightly enhanced risk of contracting aortic dissection, even in the post-partum period.

## Surgery before pregnancy in women with aortic conditions or hereditary connective tissue disorders

Pre-emptive surgery prior to a planned pregnancy and the decision to proceed to a surgical intervention for the aortic root or ascending aorta, or both, are complex issues that require a thorough discussion with the patient, the patient's family and the care team, taking into consideration the specific disorder, the underlying genetic variant, previous observation of the growing dimension of the aortic root, the specific family history and certainly the individual phenotype of the given female patient. Ideally, the specialist team involved in this decision-making process may comprise specialists in aortopathy, cardiologists, clinical geneticists, foetal medicine specialists and aortic surgeons, ideally at an experienced AC. In the planning phase of any pre-emptive aortic surgery, the risk and the potential benefit should be discussed in detail, with operations ranging from a valve-sparing root replacement operation such as a David 5 and the Yacoub procedure, to a rapid procedure involving the aorta according to the Paediatric Emergency Assessment, Recognition, and Stabilization (PEARS) concept. Moreover, despite the option for preventive surgery to the ascending aorta, a certain risk remains of pregnancy-related distal dissection, with the risk being highest in women with Loews–Dietz syndrome and underlying pathogenic variants in the TGFBR1 and TGFBR2 genes [911].

Because phenotypic features are usually absent in patients with non-syndromic HTAD with pathogenic variants in multiple genes (e.g. ACTA2, NYH11, MYLK, PRKG1), the first manifestation of a vascular disease may be acute aortic dissection with up to 20% occurring in relationship to pregnancy.

## Aortic dissection and aortic surgery in pregnancy

Usually during pregnancy, if marked aortic dilation is present or rapid aortic diameter progression >3 mm is noted, a certain risk of maternal aortic dissection should be discussed. If it is early in the pregnancy, high maternal risk of morbidity or death may warrant a pregnancy termination in selected cases [904, 912]. Prophylactic aortic surgery during pregnancy requires a complex

decision-making process and should be individualized based on maternal and foetal risk assessment. A dedicated care team usually located at an AC should be involved. Cardiac surgery in the first trimester has the risk of foetal developmental defects, whereas surgery in the third trimester is associated with risk to foetal and maternal circulation. Semi-elective surgery during pregnancy may have its lowest collective risk to foetal development and maternal safety during the second trimester [903, 912]. If a type A aortic dissection occurs during pregnancy, urgent obstetric and cardiac surgical consultation is needed because management depends on the viability of the foetus and the condition of the mother. If type A aortic dissection occurs in the first 26 weeks of pregnancy, emergency cardiac surgery should be performed, recognizing the risk of foetal loss [388, 903]. In a later stage of pregnancy with a higher likelihood of independent foetal survival after 28 weeks, caesarean delivery followed by aortic repair provides the best chances of foetal and maternal survival.

In the aggregate, prophylactic aortic surgery during pregnancy requires a complex decision-making process, and management should be individualized based on maternal and foetal risk and benefits. Emergency aortic surgery for type A dissection during pregnancy has a high risk of foetal loss in the first trimester and the best chances of survival of foetus and mother in the third trimester, if managed in an experienced AC.

## RADIATION PROTECTION

**Recommendation Table 34: Radiation protection**

Recommendations	Class <sup>a</sup>	Level <sup>b</sup>	Ref <sup>c</sup>
During endovascular aortic repair, the following radiation dose reduction strategies to protect the patient are recommended: <ul style="list-style-type: none"> <li>Positioning the image intensifier as close to the patient as possible</li> <li>Using digital subtraction acquisitions and lateral angulations</li> <li>Minimizing the time of exposure to radiation</li> </ul>	I	C	-
During endovascular aortic repair, the following radiation dose reduction strategies to protect the physician are recommended: <ul style="list-style-type: none"> <li>Keep the personnel the greatest possible distance from the source of the radiation</li> <li>Wear personal lead shields (apron, thyroid, shins and goggles)</li> <li>Use mobile lead shields</li> </ul>	I	C	-

<sup>a</sup>Class of recommendation.

<sup>b</sup>Level of evidence.

<sup>c</sup>References.

X-ray radiation is ionizing radiation that damages tissue at the molecular level. The health effects of exposure to ionizing radiation are divided into deterministic and stochastic effects. Deterministic effects are based on tissue damage and may occur by exposure of 0.1 Gy or more. They include, for example, erythema of the skin and lens opacities. Stochastic effects of ionizing radiation are chance events whose probability increases with dose, but the severity is independent of the dose. Both cancer risk and hereditary disorders are stochastic effects. An exposure

of 100 mSv is estimated to add 1% lifetime risk of a cancer-related death in a 40-year-old patient [913]. Coronary CTA performed with 64-detector CT results in radiation doses ranging from 9 to 21 mSv [914]. A complex endovascular aortic repair with fenestrated technology may result in an effective dose of up to 180 mSv [914, 915].

Because x-ray radiation is used for diagnosis of AD during aortic interventions and following up the treatments results, it is important to minimize the risk of radiation-by-radiation dose reduction whenever possible.

Computed tomography angiography plays a major role in assessing AD. However, the major limitation of CTA is a high effective radiation dose. It is essential to carefully check the indication and perform CTA only if other imaging modalities will not provide sufficient information. In most cases, following an aneurysm with a small diameter is possible with magnetic resonance imaging and ultrasonography without any exposure to ionizing radiation.

'As low as reasonably achievable' principles to protect patient and team members should be applied by physicians performing aortic interventions [916]. It is not only necessary for health-care personnel to wear full protective shielding [917] but also to use radiation shielding glasses in the operating room and to maintain as much distance as possible from the patient whenever digital subtraction angiography is performed. Image fusion of CTA images with fluoroscopy has been demonstrated to reduce the radiation dose during complex endovascular procedures [918, 919]. Furthermore, the real-time dosimetry from personal dosimeters worn by each individual working in the operating room where radiation is applied, increases the awareness of radiation exposure [920].

## INTENSIVE CARE UNIT POSTOPERATIVE MANAGEMENT OF PATIENTS UNDERGOING AORTIC SURGERY

**Recommendation Table 35: Intensive care unit postoperative management of patients undergoing aortic surgery**

Recommendations	Class <sup>a</sup>	Level <sup>b</sup>	Ref <sup>c</sup>
The enhanced recovery after surgery concept is recommended in stable patients undergoing aortic repair.	I	C	-
Normothermia is recommended in the early postoperative phase.	I	C	-
The femoral artery should be considered as preferred for arterial pressure monitoring postoperatively.	IIa	C	-
Close monitoring of lactate levels as a surrogate for postoperative malperfusion is recommended.	I	C	-
Point-of-care monitoring, in addition to regular laboratory coagulation parameters, should be considered in the early postoperative phase after open aortic repair.	IIa	B	[921, 922]

Continued

Rescue protocols for postoperative SCI after aortic arch surgery procedures that include CSF drainage and blood pressure elevation are recommended.	I	C	-
Immediate CSF drainage in patients with new onset of paraplegia after TEVAR or open TAAA replacement is recommended.	I	C	-
For patients with ILT after FET procedures, therapeutic anticoagulation is recommended.	I	C	-
Early TEVAR extension may be considered in patients with ILT after a FET implant.	IIb	C	-

<sup>a</sup>Class of recommendation.

<sup>b</sup>Level of evidence.

<sup>c</sup>References.

CSF: cerebrospinal fluid; FET: frozen elephant trunk; ILT: intraluminal thrombi; SCI: spinal cord injury; TAAA: thoraco-abdominal aortic aneurysm; TEVAR: thoracic endovascular aortic repair.

## Basic postoperative monitoring

Once the patient is admitted to the ICU, arterial pressure monitoring is usually simplified to single- or maximum double-site arterial monitoring. The literature reveals a central or femoral-to-radial pressure gradient in 45% and 34% of patients undergoing cardiac surgery, especially in patients with smaller body surface or body height, prolonged aortic cross-clamping or the use of vasopressin [923, 924]. An underestimation of central blood pressure via radial arterial monitoring carries the risk of misguided vasoactive therapy with potential sequelae for the patient, because femoral lines reflect distal body perfusion and help to detect post-repair pressure gradients across the aortic arch or the thoraco-abdominal aorta. Therefore, femoral arterial pressure monitoring should be preferred in the early postoperative phase.

Monitoring heart function and cardiac output during complex open surgical repair is one major domain of the anaesthesiologist on site. Transoesophageal echocardiography is reliable for monitoring heart function but also for evaluating operative results after valve replacement or repair and is therefore recommended during open surgical repair. Respecting the results of patients' preoperative examinations and taking the intraoperative course into account might result in considering the use of invasive tools for cardiac output monitoring. In the case of postoperative signs of hypoperfusion syndrome, invasive cardiac output measurement might help to better discriminate between primarily cardiac hypoperfusion syndrome causing malperfusion of end organs and isolated end-organ malperfusion. Pulmonary artery catheter or continuous cardiac output monitoring using arterial waveform analysis should be considered as first-line monitoring measures.

Due to the interaction of temperature and the coagulation system, respectively, and the higher rate of blood loss, postoperative inadvertent hypothermia should be avoided, and patients should be kept normothermic in the postoperative phase [925].

## Clinical assessment on arrival and reassessment protocol

Basic clinical assessment on admission to the ICU is necessary for definition of treatment goals. Different scores (e.g. the Sequential Organ Failure Assessment score) have been implemented and are part of the admission process for the basic assessment of patients admitted to the ICU. In general, clinical assessment should address respiratory, cardiovascular, hepatic, coagulation, renal and neurologic systems. Rescoring is normally performed on a 24-hour basis. For abnormalities that need closer monitoring, i.e. urine production, lactate levels and coagulation, a reassessment is normally performed 3 and 6 hours after admission to the ICU. Neurologic evaluation should be facilitated as soon as possible after aortic repair by weaning the patient from sedatives and enabling spontaneous ventilation.

## Detection of clinical and subclinical malperfusion

Postoperative malperfusion is an important predictor of hospital mortality after aortic surgery. Especially in patients with acute aortic dissection, preoperative malperfusion syndrome has an impact on early survival and influences the treatment approach [229, 926, 927]. Detection of malperfusion can be challenging in an ICU setting. Based on the complexity of aortic repair, lactate levels as well as myocardial, kidney and liver enzymes might be slightly elevated on admission to the ICU. Data on lactate levels and clearance on the perioperative outcome underline the importance of serial lactate level measurements in the early postoperative period until postoperative day 4 [928]. Adherence to an enhanced recovery protocol after surgery should be pursued, including early weaning from sedatives and transferring the patient to an intermittent mandatory ventilation mode. This practice further leads to the benefit of a more reliable clinical evaluation of the patient in terms of neurologic, visceral or lower limb malperfusion [929, 930]. Routine control of cardiac, liver, kidney and muscle enzymes is part of every standard ICU protocol.

## Coagulation management, thromboelastography and transfusion

Unfractionated heparin is administered intraoperatively in open as well as endovascular aortic repair and is routinely reversed by giving protamine. Hypothermia, haemodilution and loss of coagulation factors as well as platelets challenge coagulation management intraoperatively. Once the patient is admitted to the ICU, laboratory as well as point-of-care (POC) coagulation monitoring (thromboelastography) is required in order to maintain haemostasis and detect haemostatic abnormalities early. In accordance with the 2017 EACTS/EACTA Guidelines for Patient Blood Management, transfusion strategies should be implemented [922, 931]. The role of hypofibrinogenemia has been studied in the setting of cardiac surgery, underlining its importance in the bleeding rate. Liberal substitution of fibrinogen should be recommended in patients with low fibrinogen levels and evidence of postoperative microvascular bleeding. In terms of transfusion triggers for platelet concentrates in bleeding patients, a cut-off

below 50 ( $10^9/l$ ) for patients on antiplatelet therapy has been proposed [931, 932].

### Special consideration for certain aortic procedures

**Aortic arch replacement.** Overall, perioperative mortality and morbidity are significantly higher following aortic arch operations compared to other cardiac procedures [125, 127]. This result is due to the complexity of the underlying pathology (which variably extends into the descending aorta) and the inherent risks of surgical procedures involving the aortic arch, resulting from the manipulation of supra-aortic arteries and the need for HCA in a majority of cases. These disease and procedure-related features result in a significant risk of embolic events and ischaemic organ damage. Postoperative ICU management of aortic arch surgery procedures follows the principles and recommendations that apply to regular cardiac surgery procedures [933]. However, ICU management of aortic arch procedures has to account for typical major adverse events.

A significant number of aortic arch operations are performed in patients with an acute aortic dissection. Malperfusion syndrome is a major driver of adverse outcomes in this subset of patients [38, 227, 928, 934]. In addition, postoperative distal malperfusion may occur after an elective FET implant for chronic aortic dissection as a result of reduced organ perfusion via the excluded false lumen [935]. Hence, regular postoperative monitoring of serum lactate values is essential after aortic arch surgery.

Although clinical experience suggests that meticulous blood pressure monitoring is especially important in aortic arch surgery to balance the risks of malperfusion and bleeding, there is no scientific evidence suggesting an optimal blood pressure range during the early postoperative course after aortic arch surgery [933]. Invasive blood pressure monitoring is a crucial part of postoperative ICU monitoring of patients following aortic arch operations. Because many centres use multiple invasive arterial lines intraoperatively, it seems reasonable to prolong pressure monitoring via an upper body and lower body arterial line throughout the first 12–48 hours after surgery to monitor for postoperative blood pressure differences and acute changes in regional perfusion.

Managing haemostasis in aortic arch surgery is challenging. Long CPB times and hypothermia result in coagulopathy [936]. Patients with aortic dissection suffer from hyperfibrinolysis [937]. The 24/7 availability of POC testing is limited in most centres. In patients with major postoperative bleeding, POC protocols might hamper expeditious haemostasis, especially following aortic surgery. Consequently, transfusion management usually follows local protocols. In general, complex aortic arch surgery results in the transfusion of a significant amount of blood products and coagulation factors [938]. The value of specific transfusion regimens with supplementary application of coagulation factors remains unclear [939, 940].

The risk of procedural stroke after complex aortic arch repairs has been shown to be 5–15%. Together with preoperative strokes due to acute pathologies, up to 20% of aortic arch surgery patients suffer from a stroke [358]. Of these, 14% have been classified as intracranial bleedings in a recent study [162]. Expeditious diagnosis is critical to evaluate early therapeutic consequences. Regular clinical assessments are recommended [933]. They may be combined with NIRS in the ICU to detect life-threatening conditions in a timely fashion, such as acute cerebral malperfusion or

pericardial tamponade [941]. Although NIRS is non-specific and may fail to detect certain pathologies [942], large NIRS differences compared to baseline or fast changes may trigger a further diagnostic workup. Although the value of NIRS to guide decision-making on the ICU remains unclear, it is used intraoperatively during aortic arch procedures on a regular basis and may therefore remain in place for the initial phase in the ICU.

An SCI is a rare but serious complication after an FET implant. An SCI after an FET implant occurs due to the occlusion of a varying number of intercostal arteries that feed the arterial collateral spinal network [357, 358, 943]. The length of the FET stent graft, the HCA temperature, the HCA time [944, 945] and the postoperative low blood pressure [946] have been identified as predictors of SCIs. Consequently, most centres have adopted a policy of implanting short FET grafts, potentially in zone 2, to limit the coverage of the intercostal arteries [357, 358, 943]. This strategy might necessitate a multistage treatment of the aortic pathology but may reduce overall morbidity, especially SCIs [371, 947, 948]. Prophylactic placement of a CSF drain in all FET cases had been proposed by some centres to reduce the risk of SCI [357]. A CSF drain can be weaned from postoperative day 2 or 3 by increasing CSF pressure stepwise or temporarily stopping CSF drainage, if the patient does not exhibit postoperative signs of SCI. In cases of SCI, patients should at least be treated with CSF drainage for 5 days to allow for reorganization of the arterial collateral spinal network [949]. Patients treated with CSF drainage should be kept in a lying position to avoid intracranial pressure drop, possibly resulting in a subdural haematoma. The benefits of CSF drainage have to be weighed against the risk of potential complications [950]. With the evolution of the FET implantation strategy and decreasing rates of SCI, most centres now limit the use of prophylactic CSF drainage to high-risk cases and use it as a measure to acutely rescue postoperative SCI [357, 946, 951]. Rescue protocols to treat postoperative SCI comprise CSF drainage and blood pressure elevation [951, 952].

Recently, a specific and so far unknown complication after FET procedures has been described: intraluminal thrombi (ILT) can form within the stent graft during the early postoperative phase after FET implantation [938, 953, 954]. ILT develop more frequently in female patients, patients with degenerative aneurysms, patients with anticipated type Ib endoleaks, and patients with a large stent graft diameter in relation to body height. Conservative management of major bleeding increases the risk of ILT. Therapeutic anticoagulation is protective against ILT. So far, the evidence suggests that conditions in line with the concept of Virchow's triad [e.g. decreased blood flow velocity within the stent graft (small body size/low cardiac output/large stent grafts), large graft pockets with turbulent flow, increased blood coagulability] favour ILT formation. The risk of ILT might increase exponentially with the existence of multiple risk factors [938]. ILT within FETs has distinct morphologic features with a high risk of embolization [938, 953]. ILT was a predictor of early mortality in 1 study and should be treated with therapeutic anticoagulation. Early TEVAR extension might be considered. The role of temporary, prophylactic therapeutic anticoagulation after an FET implant remains unclear [938].

### Endovascular and open repair of the descending aorta.

Endovascular treatment of the descending thoracic aorta represents a less invasive procedure and is associated with fewer early deaths and complications in comparison to open surgery,

including postoperative pain, bleeding and wound infection [601]. In elective TEVAR of a descending thoracic aortic aneurysm or dissection, the postoperative management focuses on the treatment of blood pressure, the neurologic monitoring and the early mobilization of the patient [955]. Optimal medical treatment of blood pressure is recommended in all types of AD and should always be part of the postoperative management. The use of  $\beta$ -blockers should be considered as a first-line treatment along with the implementation of calcium channel antagonists and/or renin-angiotensin inhibitors, if required [324]. However, directly after TEVAR and/or within the first postoperative days, a low blood pressure may be associated with increased risk of SCI, especially in patients after extensive endo-coverage of the descending aorta, in patients with previous abdominal aortic interventions and in patients after coverage of the LSA without additional artery revascularization [176, 956, 957]. After open descending repair, most intercostal arteries are sacrifices, and most of the time only a limited number of intercostal arteries are re-implanted. In both patient cohorts, slightly higher systolic blood pressure (mean arterial pressure 80–90 mmHg) and haemoglobin levels of 10 mg/dl may be considered up to the exclusion of a neurologic deficit and according to the individual patient's risk for paraplegia [958]. In case of paraplegia, higher blood pressure levels should be continued, and placement of a CSF drain should follow immediately after correction of the coagulopathy.

Iliofemoral artery complications may occur in up to 12% after TEVAR either after surgical or percutaneous artery access [959, 960]. Abdominal or flank pain and acute blood loss and femoral neuropathy may indicate the presence of a retroperitoneal haematoma requiring prompt intervention and coagulopathy treatment [955].

In acute thoracic aortic syndrome, the postoperative management is more complex; it includes strict evaluation of visceral and peripheral malperfusion sequelae, prolonged respiratory recovery and treatment of pleural effusion [961, 962]. Especially in acute complicated TBAD, the ICU team should be aware of the characteristics of the true lumen and perfusion of the peripheral arteries before and after the intervention in order to estimate the individual patient's risk for organ ischaemia and to initiate specific examinations and treatment. Blood pressure differences between the upper and low extremities may indicate residual true lumen collapse and imminent malperfusion in visceral and more distal aortic segments. Pulse deficit and peripheral perfusion should be evaluated in both legs to estimate the level of true lumen collapse or thrombosis at the iliac artery axis and more distally. The early diagnosis and treatment of abdominal or peripheral compartment syndrome are crucial for the recovery and survival of the patient. Thorough repeated examinations of the clinical status and the inflammatory parameters can provide information about the progress of organ ischaemia. Computed contrast enhanced tomography or invasive angiography in hybrid operating room settings should be considered in order to verify the diagnosis and to initiate immediate treatment.

The risk of acute RTAD after TEVAR is reported to be 1.4–3.17% [365, 626]. In the ICU setting, echocardiography is recommended to exclude or detect the presence of a dissection flap in the proximal aorta and pericardial effusion in case of chest pain, haemodynamic depression and stroke followed by CT angiography.

## LIVING WITH AORTIC DISEASE

**Recommendation Table 36: Living with aortic disease**

Recommendations	Class <sup>a</sup>	Level <sup>b</sup>	Ref <sup>c</sup>
<b>Exercise and sports</b>			
Thorough education regarding the individual risks and benefits of exercise is recommended.	I	C	-
For patients with adequately controlled BP, 30–60 min of mild-to-moderate dynamic exercise at least 3–4 days per week is recommended.	I	C	-
Intense static exercise (e.g. heavy weightlifting or activities requiring the Valsalva manoeuvre) and collision sports are not recommended.	III	C	-
<b>Cardiac rehabilitation</b>			
In patients after invasive treatment of aortic pathologies, an individual cardiac rehabilitation programme under medical supervision is recommended.	I	C	-
<b>Surveillance</b>			
In any patients receiving treatment of aortic pathologies, a disease- and treatment-based individual surveillance programme in a specialized aortic centre with a dedicated out-patient clinic is recommended.	I	C	-
Imaging-based quality control after every open or endovascular aortic procedure is recommended, irrespective of the treated segment before discharge.	I	C	-
TTE is the recommended imaging modality after any kind of root surgery.	I	C	-
In patients after treatment for acute aortic dissection or IMH irrespective of treatment modality, CTA surveillance is recommended after 6 months and 12 months and, in case of stable conditions, annually thereafter for 5 years.	I	C	-
In patients after endovascular treatment irrespective of the underlying aortic disease, CTA surveillance is recommended after 6 months and 12 months and, in case of stable conditions, annually thereafter for 5 years.	I	C	-
In patients after open surgical treatment for non-aortic dissection or IMH pathologies, imaging surveillance is recommended after 12 months and 24 months and, in case of stable conditions, should be extended thereafter.	I	C	-
In patients with stable aortic conditions, extended surveillance intervals should be considered after 5 years based on an individual protocol.	IIa	C	-
In case of non-operability, no option or informed consent of refraining from treatment, stopping surveillance is recommended.	I	C	-

<sup>a</sup>Class of recommendation.

<sup>b</sup>Level of evidence.

<sup>c</sup>References.

BP: blood pressure; CTA: computed tomography angiography; IMH: intramural haematoma; TTE: transthoracic echocardiography.

## Exercise and sports

Engaging in exercise and strenuous sports is an especially important topic for young patients suffering from AD, especially those with an aortic aneurysm or inherited AD. There are 2 main forms of exercise in principle: dynamic (isotonic) and static (isometric) exercise. Dynamic exercise increases systolic blood pressure and lowers diastolic blood pressure and peripheral vascular resistance, which leads to a mild total drop in mean blood pressure [963]. Accordingly, systolic values above 210 mmHg rarely occur despite maximum effort, but when they do, the increase lasts longer than during static exercise, because systolic values can exceed 500 mmHg due to increased vascular resistance [964]. These considerations have led to the theory that static exercise is more likely to trigger sudden catastrophic events like aortic dissection or rupture, whereas periodic dynamic exercise may cause aortic growth. Although there are a few case reports of adverse events in athletes, there are no substantial data on the incidence of survival, risk for AAEs or even thereafter in any subpopulation. Accordingly, all hypotheses and recommendations in the literature are based on expert opinions [965, 966].

A patient with connective tissue disease involving the aorta or one already diagnosed with an aortic pathology should be individually advised by clinicians by expounding upon the positive and negative effects of exercise on the given AD. Accordingly, there is insufficient data and evidence to encourage or discourage any particular type of sport. A major effect of sports is obviously the positive effect on quality of life—a factor of utmost importance, especially in patients diagnosed with inherent AD who are still burdened by stigmatization and social difficulties that should not be exacerbated by the unnecessary prohibition of physical activity. This issue must be discussed openly to enable shared decision-making with the patient, parents and coach(es).

Nevertheless, a patient with an aortic aneurysm or who has had an aortic dissection should be encouraged to engage in sports. Low-dynamic, low-static exercise is superior to high-dynamic, high-static exercise. Weightlifting in particular has to be performed cautiously due to the substantial increase in blood pressure [967]. Because the maximum increase in blood pressure occurs at the level when an additional repetition cannot be carried out, irrespective of the amount of weight, patients with AD should only use low weights and stop exercise well before muscle fatigue occurs [968].

The effect of sexual activity on blood pressure increase is only moderate when applying the same principles for sports and exercise in general. Therefore, moderate sexual activity is safe and is not restricted in patients with AD.

Continuing to participate in dynamic sports with or without risking body collision inevitably requires stricter imaging surveillance via echocardiography, MRI or CTA in certain patients. This situation also applies to patients who have undergone elective aortic surgery when remaining segments are dilated.

Exercise after surgery for acute aortic dissection is also encouraged to achieve an increase in oxygen uptake, maximum workload and quality of life by lowering resting blood pressure [969]. Nevertheless, close surveillance via a low-static and low-dynamic individual programme overseen by an experienced team is recommended. Moreover, these patients are encouraged to take part in all activities of daily life including cycling and gardening [970].

Further investigation and studies are needed to specify both low-risk and high-risk exercise and patients at risk for aortic rupture or dissection.

## Returning to work

After open heart surgery, most patients returned to work after an average of 30 weeks, whereas 34% never did. The data on acute aortic dissection are even more alarming: 12 months after discharge, only a quarter of patients had returned to work after undergoing repair for ATAAD [971]. Lin *et al.* [971] identified several risk factors lowering the likelihood of returning to work, including manual or semi-skilled professional employment.

Requirements for returning to work are adequate blood pressure control and pain management achievable without opioids. Accordingly, most patients can return to their jobs after 4–12 weeks provided its physical demands are not excessive. There are too little data to justify encouraging or discouraging any one type of employment. Nevertheless, heavy lifting (high static demand), intensive physical activity and positions associated with a high stress level might be unsuitable for individuals who have undergone acute aortic dissection repair or chronic aortic dissection repair. Patients should therefore discuss returning to work with their physician or surgeon regarding time points and the need for additional surveillance.

## Rehabilitation

Cardiopulmonary exercise testing revealed impaired fitness of patients after aortic aneurysm or dissection repair compared to the predicted normal values [972, 973]. Because cardiopulmonary capacity and fitness are strongly associated with cardiovascular disease and death, improvement after treatment for AD is substantial. Studies have shown that cardiac rehabilitation (CR) programmes are safe and achieve an increase in maximum workload and peak oxygen uptake [969, 973]. Therefore, an individualized CR programme based on the patient's underlying AD and individual baseline physical fitness level is beneficial in order to reduce the risk of morbidity, mortality and psycho-social effects [972, 974]. The CR programme should be started as early as possible and carried out under professional medical supervision in close cooperation with the primary treating AC [974].

## Surveillance and follow-up

The goal of the initial treatment after diagnosis of ADs is either symptom relief, prophylaxis of AAEs or immediate management of the latter, irrespective of the treatment modality. Although current treatment options are evolving and perioperative outcomes have significantly improved over the last decades, there is still no cure for ADs without the need for further surveillance. In patients with non-dissection and medically managed dissection without invasive treatment, disease progression may cause rupture, dissection, malperfusion or local complications. Therefore, the goal of surveillance is to identify these complications as soon as possible, not only by early diagnosis but also by identifying risk factors for these events during the follow-up period. In patients who have undergone surgery or endovascular treatment, often only a minor aortic segment is addressed, namely, the

segment that is at the highest risk of AAEs or is the suspected origin of the latter. However, in the majority of patients, distal and proximal aortic segments remain untreated, and both disease progression and treatment-associated complications can occur at any time. Whereas this is less likely in non-dissection patients after open surgical treatment, it is more likely after endovascular treatment and in patients with aortic dissection in whom closure of the primary entry tear was achieved but the dissection extends into several untreated segments. For example, in patients who have had proximal repair for ATAAD with a residual dissection of the aortic arch and downstream aorta, the aortic growth rate is reported to be 1.5 mm/year [975] and 0.56 mm/year in non-dissection patients after arch replacement [976]. This distinction is particularly important because a substantial number of patients after initial repair reach the threshold for further arch or descending interventions in order to prevent subsequent aortic events. However, it has been shown that arch replacement using the FET technique can be performed safely even in this high-risk population with residual aortic dissection after previous proximal or distal repair [977]. Nevertheless, even after intended single-stage treatment by TAR using a hybrid prosthesis, distal aortic failure and subsequent reintervention rates are substantial [371, 948, 978, 979]. After endovascular aortic repair of the thoracic or abdominal aorta, the risks for endoleaks, dSINE, malperfusion, aortic dilation and dissection progression are substantial and inevitably necessitate subsequent reinterventions and have an impact on long-term survival [625, 980–982]. Identification of risk factors for these subsequent events and an understanding of the underlying mechanisms are evolving [625, 978, 980–982]. Hence, the majority of these risk factors can be identified in the first CTA scan after treatment; also, during follow-up, a surveillance programme is indispensable. Because there are no data on the superiority of any one surveillance programme, it has to be individualized based on the patient's AD and treatment, respectively. Nevertheless, as a general rule, the more untreated segments there are remaining, the more frequently the patient should be seen, whereas there is a gradient from high-risk patients (dissection patients with endovascular or medical treatment) to low-risk patients (aneurysm patients after open repair) for subsequent aortic events that should be taken into account for planning an individual surveillance programme in each patient. Lifelong surveillance including CTA scans causes substantial radiation exposure and therefore carries a relevant risk for cancer especially in young patients. Extending follow-up intervals or using MRI in patients with multiple serial unremarkable follow-up scans helps substantially to address this issue.

Despite evaluation of the morphologic aspects of the aorta, mental health is a major issue, especially in patients suffering from acute aortic dissection. This acute event, which causes the patient to face morbidity and death, leads to physical inactivity, anxiety and even depression [983] with a major impact on the person's quality of life. Standardized screening for mental health-related issues and adequate treatment if beneficial are of considerable importance.

## FUTURE DIRECTIONS AND GAPS IN KNOWLEDGE

The evidence supporting most of the recommendations in this document is largely categorized as 'Level C' for several reasons. Aortic diseases are less common compared to other cardiovascular diseases and are often life-threatening. This situation results in

studies with a limited number of participants, thereby impacting the LoE, which relies heavily on small cohort studies and expert opinions. Furthermore, the treatment of ADs often involves different specialties, including vascular and cardiac surgeons as well as interventionalists, which leads to smaller patient groups and influences the interpretation of treatment results.

The writing committee strongly encourages all involved societies and participants to focus on generating more data through prospective RCTs. Several areas have been identified where more research is needed, gaps that the global aortic community should strive to address:

- Identifying diagnostic biomarkers for confirming aortic dissection;
- Standardizing follow-up protocols specific to each disease and treatment modality;
- Providing uniform reports of intraoperative times and temperatures, detailing both degrees and location of measurement;
- Determining the extent of repair required in ATAAD;
- Evaluating the use of endovascular treatment in patients with HTAD;
- Addressing these unmet needs to further our understanding and management of these complex diseases;
- Understanding the regenerating response;
- Creating automated measurements of aortic dimensions.

## KEY MESSAGES

Our understanding of the aortic organ is continually evolving, especially in regard to its pathophysiology, the timing for treatment and the application of current and the development of new therapeutic strategies. Aortic disease has emerged as a specialty with significant health economic relevance. Several components of this guideline already establish the foundational structure necessary to meet the needs of treating the aortic organ within a specialized centre by a dedicated interdisciplinary aortic team.

Given the advancements over the past 2 decades, our current perspective and our optimistic view into the future of aortic medicine, we believe that this guideline provides a valuable platform. It serves as an advisor and companion to physicians treating patients with AD and lays the groundwork for future collaborative efforts among specialties and societies to grow and prosper together.

## ACKNOWLEDGEMENTS

We would like to extend our sincere gratitude to Giulia Zuodar, the project's manager, who provided invaluable support during the development process.

## FUNDING

This article was produced by and is the sole responsibility of The European Association for Cardio-Thoracic Surgery and The Society of Thoracic Surgeons.

**Conflict of interest:** Martin Czerny reports consultancy fees from Medira and NEOS, and consultancy for Terumo Aortic, Medtronic, and Endospan which however did not generate any payments since accepting the role of guideline Chair throughout the entire production process; a one-time direct personal payment (speaking honorarium) from Abbott; payment to their institution from Terumo aortic for postmarket registries for study nurses. Martin Czerny holds shares from TEVAR Ltd. and from Ascense Medical. Martin Grabenwöger reports direct personal payment from Edwards and Artivion. Alessandro Della Corte reports participation in a company sponsored meeting by Edwards LifeSciences for the MVT Aortic Course 2022. Andreas Martens reports direct personal payment (speaker fees) from Terumo Aortic. Andreas Martens reports research funding from Terumo Aortic for the Thoraflex Registry and from Artivion for the NEOSD + On-X Registry. Bartosz Rylski reports holding shares from Ascense medical, direct personal payment for consulting activities from Terumo Aortic and Medtronic. Carlos A. Mestres reports direct personal payment from Edwards Lifesciences for participation in a Clinical Events Committee and a direct personal payment (speaker fees) from Cytosorbens Corp. Christopher L. Schlett reports an unrestricted research grant from Siemens Healthineers and one from Bayer Healthcare. Eduard Quintana reports direct personal payment (speaker fees) from Atricure and from Medtronic. Gabriele Piffaretti reports direct personal payment (speaker fees) from WL Gore, Terumo Aortic, and Lifetech. John A. Eleftheriades reports holding shares from CoolSpine. Karen M. Kim reports sitting on the Board of Advisors of the STS Political Action Committee. Konstantinos Tsagakis reports direct personal payment (speaker fees, honoraria, consultancy, and advisory board fees) from Jotec GmbH. Mario Lescan reports receiving direct personal payment for Relay custom made/Relay Pro/Fenestrated Anaconda from Terumo Aortic; Nexus/En-side/E-tegra/E-iliac from Artivion; and VBX/VIABAHN from Gore. Maximilian Kreibich reports direct personal payment (speaker honoraria) from Terumo Aortic. Nimesh D. Desai reports providing consultancy services for WL Gore, Terumo Aortic and Artivion. Ourania Preventza reports direct personal payment from WL Gore and associates for Stent graft, and from Terumo Aortic for hybrid graft and Dacron graft. Ourania Preventza also reports participation in a symposium sponsored by Astrazeneca, where the speaker honorarium was donated to Women in Thoracic Surgery. Ourania Preventza provided consultancy for Abiomed on assist cardiac devices and for Intrassa for a stent graft (unpaid). Santi Trimarchi reports direct personal payment for participation in an advisory board and for consultancy from Medtronic. Victor Aboyans reports direct personal payment from Amarin on Vazkepa; from Bayer on Rivaroxaban; and from NovoNordisk on Ozempic. The other authors have reported no disclosures.

## REFERENCES

- [1] Erbel R, Alfonso F, Boileau C, Dirsch O, Eber B, Haverich A et al. Task Force on Aortic Dissection, European Society of Cardiology. Diagnosis and management of aortic dissection. *Eur Heart J* 2001;22:1642–81.
- [2] Sousa-Uva M, Head SJ, Thielmann M, Cardillo G, Benedetto U, Czerny M et al. Methodology manual for European Association for Cardio-Thoracic Surgery (EACTS) clinical guidelines. *Eur J Cardiothorac Surg* 2015;48:809–16.
- [3] ten Dijke P, Arthur HM. Extracellular control of TGFbeta signalling in vascular development and disease. *Nat Rev Mol Cell Biol* 2007;8:857–69.
- [4] Kau T, Sinzig M, Gasser J, Lesnik G, Rabitsch E, Celestin S et al. Aortic development and anomalies. *Semin Intervent Radiol* 2007;24:141–52.
- [5] Shen YH, LeMaire SA, Webb NR, Cassis LA, Daugherty A, Lu HS. Aortic aneurysms and dissections series: art II: dynamic signaling responses in aortic aneurysms and dissections. *Arterioscler Thromb Vasc Biol* 2020;40:e78–86.
- [6] Humphrey JD, Schwartz MA, Tellides G, Milewicz DM. Role of mechanotransduction in vascular biology: focus on thoracic aortic aneurysms and dissections. *Circ Res* 2015;116:1448–61.
- [7] Xu J, Shi GP. Vascular wall extracellular matrix proteins and vascular diseases. *Biochim Biophys Acta* 2014;1842:2106–19.
- [8] Cook JR, Clayton NP, Carta L, Galatioto J, Chiu E, Smaldone S et al. Dimorphic effects of transforming growth factor- $\beta$  signaling during aortic aneurysm progression in mice suggest a combinatorial therapy for Marfan syndrome. *Arterioscler Thromb Vasc Biol* 2015;35:911–7.
- [9] Chou E, Pirruccello JP, Ellinor PT, Lindsay ME. Genetics and mechanisms of thoracic aortic disease. *Nat Rev Cardiol* 2023;20:168–80.
- [10] Johnston KW, Rutherford RB, Tilson MD, Shah DM, Hollier L, Stanley JC. Suggested standards for reporting on arterial aneurysms. Subcommittee on reporting standards for arterial aneurysms, ad hoc committee on reporting standards, Society for Vascular Surgery and North American Chapter, International Society for Cardiovascular Surgery. *J Vasc Surg* 1991;13:452–8.
- [11] Paruchuri V, Salhab KF, Kuzmik G, Gubernikoff G, Fang H, Rizzo JA et al. Aortic size distribution in the general population: explaining the size paradox in aortic dissection. *Cardiology* 2015;131:265–72.
- [12] McClure RS, Brogly SB, Lajkosz K, Payne D, Hall SF, Johnson AP. Epidemiology and management of thoracic aortic dissections and thoracic aortic aneurysms in Ontario, Canada: a population-based study. *J Thorac Cardiovasc Surg* 2018;155:2254–64.e4.
- [13] Landenhed M, Engström G, Gottsäter A, Caulfield MP, Hedblad B, Newton-Cheh C et al. Risk profiles for aortic dissection and ruptured or surgically treated aneurysms: a prospective cohort study. *J Am Heart Assoc* 2015;4:e001513.
- [14] Oladokun D, Patterson BO, Sobocinski J, Karthikesalingam A, Loftus I, Thompson MM et al. Systematic review of the growth rates and influencing factors in thoracic aortic aneurysms. *Eur J Vasc Endovasc Surg* 2016;51:674–81.
- [15] Mehrabi Nasab E, Athari SS. The prevalence of thoracic aorta aneurysm as an important cardiovascular disease in the general population. *J Cardiothorac Surg* 2022;17:51.
- [16] Vandroux D, Aboyans V, Houehanou YC, Saka D, Sonou A, Houinato D et al. TAHES study investigators. Normal values of proximal aorta diameters in healthy Sub Saharan Africans: the TAHES study. *Echocardiography* 2022;39:576–83.
- [17] Pacini D, Di Marco L, Fortuna D, Belotti LM, Gabbieri D, Zussa C et al. Acute aortic dissection: epidemiology and outcomes. *Int J Cardiol* 2013;167:2806–12.
- [18] Melvinsdottir IH, Lund SH, Agnarsson BA, Sigvaldason K, Gudbjartsson T, Geirsson A. The incidence and mortality of acute thoracic aortic dissection: results from a whole nation study. *Eur J Cardiothorac Surg* 2016;50:1111–7.
- [19] Howard DP, Banerjee A, Fairhead JF, Perkins J, Silver LE, Rothwell PM; Oxford Vascular Study. Population-based study of incidence and outcome of acute aortic dissection and premorbid risk factor control: 10-year results from the Oxford Vascular Study. *Circulation* 2013;127:2031–7.
- [20] Smedberg C, Steuer J, Leander K, Hultgren R. Sex differences and temporal trends in aortic dissection: a population-based study of incidence, treatment strategies, and outcome in Swedish patients during 15 years. *Eur Heart J* 2020;41:2430–8.
- [21] Yeh TY, Chen CY, Huang JW, Chiu CC, Lai WT, Huang YB. Epidemiology and medication utilization pattern of aortic dissection in taiwan: a population-based study. *Medicine (Baltimore)* 2015;94:e1522.
- [22] Lee JH, Cho Y, Cho YH, Kang H, Lim TH, Jang HJ et al. Incidence and mortality rates of thoracic aortic dissection in Korea—inferred from the Nationwide Health Insurance Claims. *J Korean Med Sci* 2020;35:e360.
- [23] Dinh MM, Bein KJ, Delaney J, Berendsen Russell S, Royle T. Incidence and outcomes of aortic dissection for emergency departments in New South Wales, Australia 2017–2018: a data linkage study. *Emerg Med Australas* 2020;32:599–603.
- [24] Yamaguchi T, Nakai M, Yano T, Matsuyama M, Yoshino H, Miyamoto Y et al. Population-based incidence and outcomes of acute aortic dissection in Japan. *Eur Heart J Acute Cardiovasc Care* 2021;10:701–9.
- [25] Obel LM, Lindholt JS, Lasota AN, Jensen HK, Benhassen LL, Mørkved AL et al. Clinical characteristics, incidences, and mortality rates for type A and B aortic dissections: a nationwide danish population-based cohort study from 1996 to 2016. *Circulation* 2022;146:1903–17.

- [26] Ohle R, Savage DW, McIsaac S, Yadav K, Caswell J, Conlon M. Epidemiology, mortality and miss rate of acute aortic syndrome in Ontario, Canada: a population-based study. *CJEM* 2023;25:57-64.
- [27] Aboyns V, Boukhris M. Dissecting the epidemiology of aortic dissection. *Eur Heart J Acute Cardiovasc Care* 2021;10:710-1.
- [28] DeMartino RR, Sen I, Huang Y, Bower TC, Oderich GS, Pochettino A et al. Population-based assessment of the incidence of aortic dissection, intramural hematoma, and penetrating ulcer, and its associated mortality from 1995 to 2015. *Circ Cardiovasc Qual Outcomes* 2018;11:e004689.
- [29] Evangelista Masip A, López-Sainz Á, Barros Membrilla AJ, Calvo Iglesias F, López Ayerbe J, Azqueta Molluna M et al. Spanish Registry of Acute Aortic Syndrome (RESA). Changes in therapeutic management and lower mortality in acute aortic syndrome. *Rev Esp Cardiol (Engl Ed)* 2022;75:816-24.
- [30] Abdallah N, Mouchati C, Crowley C, Hanna L, Goodall R, Salciccioli JD et al. Trends in mortality from aortic dissection analyzed from the World Health Organization Mortality Database from 2000 to 2017. *Int J Cardiol* 2022;360:83-90.
- [31] Golledge J, Muller J, Daugherty A, Norman P. Abdominal aortic aneurysm: pathogenesis and implications for management. *Arterioscler Thromb Vasc Biol* 2006;26:2605-13.
- [32] Lindholt JS, Søgaard R. Population screening and intervention for vascular disease in Danish men (VIVA): a randomised controlled trial. *Lancet* 2017;390:2256-65.
- [33] Wanhainen A, Hultgren R, Linné A, Holst J, Gottsäter A, Langenskiöld M et al. Swedish Aneurysm Screening Study Group (SASS). Outcome of the Swedish Nationwide Abdominal Aortic Aneurysm Screening Program. *Circulation* 2016;134:1141-8.
- [34] Oliver-Williams C, Sweeting MJ, Turton G, Parkin D, Cooper D, Rodd C et al. Gloucestershire and Swindon Abdominal Aortic Aneurysm Screening Programme. Lessons learned about prevalence and growth rates of abdominal aortic aneurysms from a 25-year ultrasound population screening programme. *Br J Surg* 2018;105:68-74.
- [35] Jacomelli J, Summers L, Stevenson A, Lees T, Earnshaw JJ. Impact of the first 5 years of a national abdominal aortic aneurysm screening programme. *Br J Surg* 2016;103:1125-31.
- [36] Norman PE, Spilsbury K, Semmens JB. Falling rates of hospitalization and mortality from abdominal aortic aneurysms in Australia. *J Vasc Surg* 2011;53:274-7.
- [37] Sandiford P, Mosquera D, Bramley D. Trends in incidence and mortality from abdominal aortic aneurysm in New Zealand. *Br J Surg* 2011;98:645-51.
- [38] Sievers HH, Rylski B, Czerny M, Baier ALM, Kreibich M, Siepe M et al. Aortic dissection reconsidered: type, entry site, malperfusion classification adding clarity and enabling outcome prediction. *Interact CardioVasc Thorac Surg* 2020;30:451-7.
- [39] Czerny M, Siepe M, Beyersdorf F, Feisst M, Gabel M, Pilz M et al. Prediction of mortality rate in acute type A dissection: the German Registry for Acute Type A Aortic Dissection score. *Eur J Cardiothorac Surg* 2020;58:700-6.
- [40] Turina MI, Shennib H, Dunning J, Cheng D, Martin J, Muneretto C et al. EACTS/ESCVA committee. EACTS/ESCVA best practice guidelines for reporting treatment results in the thoracic aorta. *Eur J Cardiothorac Surg* 2009;35:927-30.
- [41] Rylski B, Pacini D, Beyersdorf F, Quintana E, Schachner T, Tzagakis K et al. EACTS Vascular Domain, EJCTS and ICVTS Editorial Committees. Standards of reporting in open and endovascular aortic surgery (STORAGE guidelines). *Eur J Cardiothorac Surg* 2019;56:10-20.
- [42] Lombardi JV, Hughes GC, Appoo JJ, Bavaria JE, Beck AW, Cambria RP et al. Society for Vascular Surgery (SVS) and Society of Thoracic Surgeons (STS) reporting standards for type B aortic dissections. *Ann Thorac Surg* 2020;109:959-81.
- [43] Oderich GS, Forbes TL, Chaer R, Davies MG, Lindsay TF, Mastracci T et al. Writing Committee Group. Reporting standards for endovascular aortic repair of aneurysms involving the renal-mesenteric arteries. *J Vasc Surg* 2021;73:4s-52s.
- [44] Nienaber CA, Clough RE. Management of acute aortic dissection. *Lancet* 2015;385:800-11.
- [45] Daily PO, Trueblood HW, Stinson EB, Wuerflein RD, Shumway NE. Management of acute aortic dissections. *Ann Thorac Surg* 1970;10:237-47.
- [46] De Bakey ME, Henly WS, Cooley DA, Morris GC Jr, Crawford ES, Beall AC Jr. Surgical management of dissecting aneurysms of the aorta. *J Thorac Cardiovasc Surg* 1965;49:130-49.
- [47] Nienaber CA, Clough RE, Sakalihasan N, Suzuki T, Gibbs R, Mussa F et al. Aortic dissection. *Nat Rev Dis Primers* 2016;2:16071.
- [48] Urbanski PP, Wagner M. Acute non-A-non-B aortic dissection: surgical or conservative approach? *Eur J Cardiothorac Surg* 2016;49:1249-54.
- [49] von Segesser LK, Killer I, Ziswiler M, Linka A, Ritter M, Jenni R et al. Dissection of the descending thoracic aorta extending into the ascending aorta. A therapeutic challenge. *J Thorac Cardiovasc Surg* 1994;108:755-61.
- [50] Rylski B, Pérez M, Beyersdorf F, Reser D, Kari FA, Siepe M et al. Acute non-A non-B aortic dissection: incidence, treatment and outcome. *Eur J Cardiothorac Surg* 2017;52:1111-7.
- [51] Fillinger MF, Greenberg RK, McKinsey JF, Chaikof EL; Society for Vascular Surgery Ad Hoc Committee on TEVAR Reporting Standards. Reporting standards for thoracic endovascular aortic repair (TEVAR). *J Vasc Surg* 2010;52:1022-33, 33.e15.
- [52] Marrocco-Trischitta MM, Sturla F. Blood flow helical pattern in type III arch configuration as a potential risk factor for type B aortic dissection. *Eur J Cardiothorac Surg* 2021;61:132-9.
- [53] Malaisrie SC, Szeto WY, Halas M, Girardi LN, Coselli JS, Sundt TM 3rd et al. AATS Clinical Practice Standards Committee: Adult Cardiac Surgery. 2021 The American Association for Thoracic Surgery expert consensus document: Surgical treatment of acute type A aortic dissection. *J Thorac Cardiovasc Surg* 2021;162:735-58.e2.
- [54] Chikwe J, Cavallaro P, Itagaki S, Seigerman M, Diluozzo G, Adams DH. National outcomes in acute aortic dissection: influence of surgeon and institutional volume on operative mortality. *Ann Thorac Surg* 2013;95:1563-9.
- [55] Santini F, Montalbano G, Casali G, Messina A, Iafrancesco M, Luciani GB et al. Clinical presentation is the main predictor of in-hospital death for patients with acute type A aortic dissection admitted for surgical treatment: a 25 years experience. *Int J Cardiol* 2007;115:305-11.
- [56] Benedetto U, Sinha S, Dimagli A, Cooper G, Mariscalco G, Uppal R et al. UK Aortic Group. Decade-long trends in surgery for acute Type A aortic dissection in England: a retrospective cohort study. *Lancet Reg Health Eur* 2021;7:100131.
- [57] Grimm JC, Magruder JT, Crawford TC, Sciortino CM, Zehr KJ, Mandal K et al. Differential outcomes of type A dissection with malperfusion according to affected organ system. *Ann Cardiothorac Surg* 2016;5:202-8.
- [58] Kreibich M, Desai ND, Bavaria JE, Szeto WY, Vallabhajosyula P, Itagaki R et al. Preoperative neurological deficit in acute type A aortic dissection. *Interact CardioVasc Thorac Surg* 2020;30:613-9.
- [59] Leshnowar BG, Keeling WB, Duwayri YM, Jordan WD Jr, Chen EP. The "thoracic endovascular aortic repair-first" strategy for acute type A dissection with mesenteric malperfusion: initial results compared with conventional algorithms. *J Thorac Cardiovasc Surg* 2019;158:1516-24.
- [60] Roselli EE, Atkins MD, Brinkman W, Coselli J, Desai N, Estrera A et al. ARISE: first-in-human evaluation of a novel stent graft to treat ascending aortic dissection. *J Endovasc Ther* 2022;30:550-60.
- [61] Nashef SA, Roques F, Sharples LD, Nilsson J, Smith C, Goldstone AR et al. EuroSCORE II. *Eur J Cardiothorac Surg* 2012;41:734-44; discussion 44-5.
- [62] Bowdish ME, D'Agostino RS, Hourani VH, Schwann TA, Krohn C, Desai N et al. STS adult cardiac surgery database: 2021 update on outcomes, quality, and research. *Ann Thorac Surg* 2021;111:1770-80.
- [63] Augoustides JG, Geirsson A, Szeto WY, Walsh EK, Cornelius B, Pochettino A et al. Observational study of mortality risk stratification by ischemic presentation in patients with acute type A aortic dissection: the Penn classification. *Nat Clin Pract Cardiovasc Med* 2009;6:140-6.
- [64] Nežić DG, Živković IS, Miličić MD, Milačić PA, Košević DN, Boričić MI et al. On-line risk prediction models for acute type A aortic dissection surgery: validation of the German Registry of Acute Aortic Dissection Type A score and the European System for Cardiac Operative Risk Evaluation II. *Eur J Cardiothorac Surg* 2022;61:1068-75.
- [65] Sugiyama K, Watanuki H, Tochio M, Futamura Y, Kitagawa Y, Makino S et al. Impact of GERAADA score in patients with acute type A aortic dissection. *J Cardiothorac Surg* 2022;17:127.
- [66] Patrick WL, Yarlagadda S, Bavaria JE, Kelly JJ, Kalva S, Grimm JC et al. The Penn classification system for malperfusion in acute type A dissection: a 25-year experience. *Ann Thorac Surg* 2023;115:1109-17.
- [67] Tien M, Ku A, Martinez-Acero N, Zvara J, Sun EC, Cheung AT. The Penn classification predicts hospital mortality in acute Stanford type A

- and type B aortic dissections. *J Cardiothorac Vasc Anesth* 2020;34:867–73.
- [68] Pisano C, Balistreri CR, Torretta F, Capuccio V, Allegra A, Argano V et al. Penn classification in acute aortic dissection patients. *Acta Cardiol* 2016;71:235–40.
- [69] Roux PM, Guilmet D. Acute dissection of the aorta in 1986. *Presse Med* 1986;15:1924–7.
- [70] Dake MD, Thompson M, van Sambeek M, Vermassen F, Morales JP; DEFINE Investigators. DISSECT: a new mnemonic-based approach to the categorization of aortic dissection. *Eur J Vasc Endovasc Surg* 2013;46:175–90.
- [71] Augoustides JG, Szeto WY, Desai ND, Pochettino A, Cheung AT, Savino JS et al. Classification of acute type A dissection: focus on clinical presentation and extent. *Eur J Cardiothorac Surg* 2011;39:519–22.
- [72] Kosiorowska M, Berezowski M, Widenka K, Kreibich M, Beyersdorf F, Czerny M et al. Non-A non-B acute aortic dissection with entry tear in the aortic arch. *Interact CardioVasc Thorac Surg* 2022;34:878–84.
- [73] Della Corte A, Body SC, Booher AM, Schaefer HJ, Milewski RK, Michelena HI et al. International Bicuspid Aortic Valve Consortium (BAVCon) Investigators. Surgical treatment of bicuspid aortic valve disease: knowledge gaps and research perspectives. *J Thorac Cardiovasc Surg* 2014;147:1749–57, 57.e1.
- [74] Verma S, Yanagawa B, Kalra S, Ruel M, Peterson MD, Yamashita MH et al. Knowledge, attitudes, and practice patterns in surgical management of bicuspid aortopathy: a survey of 100 cardiac surgeons. *J Thorac Cardiovasc Surg* 2013;146:1033–40.e4.
- [75] Hiratzka LF, Creager MA, Isselbacher EM, Svensson LG, Nishimura RA, Bonow RO et al. Surgery for aortic dilatation in patients with bicuspid aortic valves: a statement of clarification from the American College of Cardiology/American Heart Association Task Force on Clinical Practice Guidelines. *J Am Coll Cardiol* 2016;67:724–31.
- [76] Hardikar AA, Marwick TH. The natural history of guidelines: the case of aortopathy related to bicuspid aortic valves. *Int J Cardiol* 2015;199:150–3.
- [77] Della Corte A, Bancone C, Quarto C, Dialecto G, Covino FE, Scardone M et al. Predictors of ascending aortic dilatation with bicuspid aortic valve: a wide spectrum of disease expression. *Eur J Cardiothorac Surg* 2007;31:397–404.
- [78] Schaefer BM, Lewin MB, Stout KK, Gill E, Prueitt A, Byers PH et al. The bicuspid aortic valve: an integrated phenotypic classification of leaflet morphology and aortic root shape. *Heart* 2008;94:1634–8.
- [79] Fazel SS, Mallidi HR, Lee RS, Sheehan MP, Liang D, Fleischman D et al. The aortopathy of bicuspid aortic valve disease has distinctive patterns and usually involves the transverse aortic arch. *J Thorac Cardiovasc Surg* 2008;135:901–2, 907.e1–2.
- [80] Michelena HI, Della Corte A, Evangelista A, Maleszewski JJ, Edwards WD, Roman MJ et al. Endorsed by the Heart Valve Society (HVS), European Association of Cardiovascular Imaging (EACVI), Society of Thoracic Surgeons (STS), American Association for Thoracic Surgery (AATS), Society for Cardiovascular Magnetic Resonance (SCMR), Society of Cardiovascular Computed Tomography (SCCT), North American Society for Cardiovascular Imaging (NASCI) and the International Bicuspid Aortic Valve Consortium (BAVCon). International consensus statement on nomenclature and classification of the congenital bicuspid aortic valve and its aortopathy, for clinical, surgical, interventional and research purposes. *Eur J Cardiothorac Surg* 2021;60:448–76.
- [81] Della Corte A. Phenotypic heterogeneity of bicuspid aortopathy: a potential key to decode the prognosis? *Heart* 2014;100:96–7.
- [82] Della Corte A, Bancone C, Buonocore M, Dialecto G, Covino FE, Manduca S et al. Pattern of ascending aortic dimensions predicts the growth rate of the aorta in patients with bicuspid aortic valve. *JACC Cardiovasc Imaging* 2013;6:1301–10.
- [83] Dayan V, Zuasnabar A, Citro R, Bossone E, Michelena HI, Parma G et al. Bicuspid Aortic Valve Consortium—BAVCON. Aortopathy and regurgitation in bicuspid valve patients increase the risk of aortopathy in relatives. *Int J Cardiol* 2019;286:117–20.
- [84] Girdauskas E, Rouman M, Disha K, Espinoza A, Misfeld M, Borger MA et al. Aortic dissection after previous aortic valve replacement for bicuspid aortic valve disease. *J Am Coll Cardiol* 2015;66:1409–11.
- [85] Etz CD, von Aspern K, Hoyer A, Girrbaach FF, Leontyev S, Bakhtiyar F et al. Acute type A aortic dissection: characteristics and outcomes comparing patients with bicuspid versus tricuspid aortic valve. *Eur J Cardiothorac Surg* 2015;48:142–50.
- [86] Rylski B, Desai ND, Bavaria JE, Vallabhajosyula P, Moser W, Pochettino A et al. Aortic valve morphology determines the presentation and surgical approach to acute type A aortic dissection. *Ann Thorac Surg* 2014;97:1991–6.
- [87] Della Corte A, Lo Presti F, Saade W, Rubino AS, Palmieri L, Patanè F et al. Acute type A aortic dissection in bicuspid versus tricuspid aortic valve patients: focus on geometrical features of the aorta. *Eur J Cardiothorac Surg* 2023;63:ezac576.
- [88] Girdauskas E, Geist L, Disha K, Kazakbaev I, Groß T, Schulz S et al. Genetic abnormalities in bicuspid aortic valve root phenotype: preliminary results. *Eur J Cardiothorac Surg* 2017;52:156–62.
- [89] Bollache E, Guzzardi DG, Sattari S, Olsen KE, Di Martino ES, Malaisrie SC et al. Aortic valve-mediated wall shear stress is heterogeneous and predicts regional aortic elastic fiber thinning in bicuspid aortic valve-associated aortopathy. *J Thorac Cardiovasc Surg* 2018;156:2112–20.e2.
- [90] Forte A, Bancone C, Cobellis G, Buonocore M, Santarpino G, Fischlein TJM et al. A possible early biomarker for bicuspid aortopathy: circulating transforming growth factor  $\beta$ -1 to soluble endoglin ratio. *Circ Res* 2017;120:1800–11.
- [91] Wang Y, Wu B, Li J, Dong L, Wang C, Shu X. Impact of aortic insufficiency on ascending aortic dilatation and adverse aortic events after isolated aortic valve replacement in patients with a bicuspid aortic valve. *Ann Thorac Surg* 2016;101:1707–14.
- [92] Wojnarski CM, Roselli EE, Idrees JJ, Zhu Y, Carnes TA, Lowry AM et al. Machine-learning phenotypic classification of bicuspid aortopathy. *J Thorac Cardiovasc Surg* 2018;155:461–9.e4.
- [93] G n reux P, Piazza N, Alu MC, Nazif T, Hahn RT, Pibarot P et al. VARC-3 WRITING COMMITTEE. Valve Academic Research Consortium 3: updated endpoint definitions for aortic valve clinical research. *J Am Coll Cardiol* 2021;77:2717–46.
- [94] von Allmen RS, Weiss S, Tev aeai HT, K emmerli C, Tinner C, Carrel TP et al. Completeness of follow-up determines validity of study findings: results of a prospective repeated measures cohort study. *PLoS One* 2015;10:e0140817.
- [95] Kim KM, Arghami A, Habib R, Daneshmand MA, Parsons N, Elhalabi Z et al. The Society of Thoracic Surgeons Adult Cardiac Surgery Database: 2022 update on outcomes and research. *Ann Thorac Surg* 2023;115:566–74.
- [96] Shimizu H, Hirahara N, Motomura N, Miyata H, Takamoto S. Current status of cardiovascular surgery in Japan, 2013 and 2014: a report based on the Japan Cardiovascular Surgery Database 5. Thoracic aortic surgery. *Gen Thorac Cardiovasc Surg* 2017;65:671–8.
- [97] Elefteriades JA, Farkas EA. Thoracic aortic aneurysm clinically pertinent controversies and uncertainties. *J Am Coll Cardiol* 2010;55:841–57.
- [98] Liang L, Liu M, Martin C, Elefteriades JA, Sun W. A machine learning approach to investigate the relationship between shape features and numerically predicted risk of ascending aortic aneurysm. *Biomech Model Mechanobiol* 2017;16:1519–33.
- [99] Martin C, Sun W, Elefteriades J. Patient-specific finite element analysis of ascending aorta aneurysms. *Am J Physiol Heart Circ Physiol* 2015;308:H1306–16.
- [100] Rampoldi V, Trimarchi S, Eagle KA, Nienaber CA, Oh JK, Bossone E et al. International Registry of Acute Aortic Dissection (IRAD) Investigators. Simple risk models to predict surgical mortality in acute type A aortic dissection: the International Registry of Acute Aortic Dissection score. *Ann Thorac Surg* 2007;83:55–61.
- [101] Tolenaar JL, Froehlich W, Jonker FH, Upchurch GR Jr, Rampoldi V, Tsai TT et al. Predicting in-hospital mortality in acute type B aortic dissection: evidence from International Registry of Acute Aortic Dissection. *Circulation* 2014;130:S45–50.
- [102] Mori M, Shioda K, Wang X, Mangi AA, Yun JJ, Darr U et al. Perioperative risk profiles and volume-outcome relationships in proximal thoracic aortic surgery. *Ann Thorac Surg* 2018;106:1095–104.
- [103] Umana-Pizano JB, Nissen AP, Sandhu HK, Miller CC, Loghin A, Safi HJ et al. Acute type A dissection repair by high-volume vs low-volume surgeons at a high-volume aortic center. *Ann Thorac Surg* 2019;108:1330–6.
- [104] Khan H, Hussain A, Chaubey S, Sameh M, Salter I, Deshpande R et al. Acute aortic dissection type A: impact of aortic specialists on short and long term outcomes. *J Card Surg* 2021;36:952–8.
- [105] Misfeld M, Etz CD, Leontyev S, Borger MA. The aortic team and bicuspid aortic valve patients. *Ann Cardiothorac Surg* 2022;11:459–61.
- [106] Crawford EE, McCarthy PM, Malaisrie SC, Mehta CK, Puthumana JJ, Robinson JD et al. The need for comprehensive multidisciplinary programs, complex interventions, and precision medicine for bicuspid aortic valve disease. *Ann Cardiothorac Surg* 2022;11:369–79.

- [107] Jędrzejczak T, Rynio P, Lewandowski M, Żych A, Rybicka A, Żukowski M et al. Multidisciplinary aortic arch procedures within the "Aortic Team". *Kardiocir Torakochirurgia Pol* 2022;19:11–5.
- [108] Tanious A, Wooster M, Giarelli M, Armstrong PA, Johnson B, Illig KA et al. Positive impact of an aortic center designation. *Ann Vasc Surg* 2018;46:142–6.
- [109] Gifford ED, de Virgilio C. Aortic centers of excellence: shifting the focus. *JAMA Surg* 2016;151:845.
- [110] Rawson TM, Gill D, Buckley J, Renton S. The role of the multidisciplinary team in decision-making for vascular graft infection. *J Vasc Surg* 2015;62:1686.
- [111] Andersen ND, Benrashed E, Ross AK, Pickett LC, Smith PK, Daneshmand MA et al. The utility of the aortic dissection team: outcomes and insights after a decade of experience. *Ann Cardiothorac Surg* 2016;5:194–201.
- [112] Andersen ND, Ganapathi AM, Hanna JM, Williams JB, Gaca JG, Hughes GC. Outcomes of acute type a dissection repair before and after implementation of a multidisciplinary thoracic aortic surgery program. *J Am Coll Cardiol* 2014;63:1796–803.
- [113] Beller JP, Scheinerman JA, Balsam LB, Ursomanno P, DeAnda A Jr. Operative strategies and outcomes in type A aortic dissection after the enactment of a multidisciplinary aortic surgery team. *Innovations (Phila)* 2015;10:410–5.
- [114] Mazer LM, Chiakof EL, Goodney PP, Edwards MS, Corriere MA. Single versus multi-specialty operative teams: association with perioperative mortality after endovascular abdominal aortic aneurysm repair. *Am Surg* 2012;78:207–12.
- [115] Field ML, Kuduvali M, Oo A. Multidisciplinary team-led management of acute Type B aortic dissection in the United Kingdom? *J R Soc Med* 2011;104:53–8.
- [116] Harris KM, Strauss CE, Duval S, Unger BT, Kroshus TJ, Inampudi S et al. Multidisciplinary standardized care for acute aortic dissection: design and initial outcomes of a regional care model. *Circ Cardiovasc Qual Outcomes* 2010;3:424–30.
- [117] Matsuda H, Ogino H, Fukuda T, Iritani O, Sato S, Iba Y et al. Multidisciplinary approach to prevent spinal cord ischemia after thoracic endovascular aneurysm repair for distal descending aorta. *Ann Thorac Surg* 2010;90:561–5.
- [118] Laheij RJ, van Marrewijk CJ, Buth J, Harris PL; EUROSTAR Collaborators. The influence of team experience on outcomes of endovascular stenting of abdominal aortic aneurysms. *Eur J Vasc Endovasc Surg* 2002;24:128–33.
- [119] Hamadeh N, van Rompaey C, Metreau E, New World Bank Country Classifications by Income Level: 2021-2022. 2021. <https://blogs.worldbank.org/opendata/new-world-bank-country-classifications-income-level-2021-2022> (1 July 2021, date last accessed).
- [120] Lodewyckx CL, Prior HJ, Hiebert BM, Nickel NC, Yamashita MH, Ouzounian M et al. A province-wide analysis of the epidemiology of thoracic aortic disease: incidence is increasing in a sex-specific way. *Can J Cardiol* 2020;36:1729–38.
- [121] Wang Z, You Y, Yin Z, Bao Q, Lei S, Yu J et al. Burden of aortic aneurysm and its attributable risk factors from 1990 to 2019: an analysis of the Global Burden of Disease Study 2019. *Front Cardiovasc Med* 2022;9:901225.
- [122] Huang X, Wang Z, Shen Z, Lei F, Liu YM, Chen Z et al. Projection of global burden and risk factors for aortic aneurysm—timely warning for greater emphasis on managing blood pressure. *Ann Med* 2022;54:553–64.
- [123] Chen MM, Zhang X, Liu YM, Chen Z, Li H, Lei F et al. Heavy disease burden of high systolic blood pressure during 1990–2019: highlighting regional, sex, and age specific strategies in blood pressure control. *Front Cardiovasc Med* 2021;8:754778.
- [124] Tsai JP, Jan YT, Yun CH, Sung KT, Liu CC, Kuo JY et al. Associations of cigarette smoking and burden of thoracic aortic calcification in asymptomatic individuals: a dose-response relationship. *PLoS One* 2020;15:e0227680.
- [125] Beckmann A, Meyer R, Lewandowski J, Markewitz A, Bläßfeld D, Böning A. German Heart Surgery Report 2021: the annual updated registry of the German Society for Thoracic and Cardiovascular Surgery. *Thorac Cardiovasc Surg* 2022;70:362–76.
- [126] McClure RS, Brogly SB, Lajkosz K, McClintock C, Payne D, Smith HN et al. Economic burden and healthcare resource use for thoracic aortic dissections and thoracic aortic aneurysms—a population-based cost-of-illness analysis. *J Am Heart Assoc* 2020;9:e014981.
- [127] Martens A, Beckmann E, Kaufeld T, Umminger J, Fleissner F, Koigeldiyev N et al. Total aortic arch repair: risk factor analysis and follow-up in 199 patients. *Eur J Cardiothorac Surg* 2016;50:940–8.
- [128] Czerny M, Pacini D, Aboyans V, Al-Attar N, Eggebrecht H, Evangelista A et al. Current options and recommendations for the use of thoracic endovascular aortic repair in acute and chronic thoracic aortic disease: an expert consensus document of the European Society for Cardiology (ESC) Working Group of Cardiovascular Surgery, the ESC Working Group on Aorta and Peripheral Vascular Diseases, the European Association of Percutaneous Cardiovascular Interventions (EAPCI) of the ESC and the European Association for Cardio-Thoracic Surgery (EACTS). *Eur J Cardiothorac Surg* 2021;59:65–73.
- [129] Sanaïha Y, Kavianpour B, Downey P, Morchi R, Shemin RJ, Benharash P. National study of index and readmission mortality and costs for thoracic endovascular aortic repair in patients with renal disease. *Ann Thorac Surg* 2020;109:458–64.
- [130] Columbo JA, Goodney PP, Gladders BH, Tsougranis G, Wanken ZJ, Trooboff SW et al. Medicare costs for endovascular abdominal aortic aneurysm treatment in the Vascular Quality Initiative. *J Vasc Surg* 2021;73:1056–61.
- [131] Rocha RV, De Mestral C, Tam DY, Lee DS, Al-Omran M, Austin PC et al. Health care costs of endovascular compared with open thoracoabdominal aortic aneurysm repair. *J Vasc Surg* 2021;73:1934–41.e1.
- [132] D'Oria M, Sen I, Day CN, Mandrekar J, Weiss S, Bower TC et al. Burden and causes of readmissions following initial discharge after aortic syndromes. *J Vasc Surg* 2021;73:836–43.e3.
- [133] Martín M, Morís C, Lozano I, Llana JM, Vega F, Fernández F et al. Percutaneous treatment of thoracic aorta diseases. A multidisciplinary approach. *Rev Esp Cardiol* 2005;58:27–33.
- [134] Davies MG, Lumsden AB. Acute aortic treatment center. *Methodist DeBakey Cardiovasc J* 2011;7:8–10.
- [135] Bonser RS, Ranasinghe AM, Loubani M, Evans JD, Thalji NM, Bachel JE et al. Evidence, lack of evidence, controversy, and debate in the provision and performance of the surgery of acute type A aortic dissection. *J Am Coll Cardiol* 2011;58:2455–74.
- [136] Czerny M, Schmidli J, Adler S, van den Berg JC, Bertoglio L, Carrel T et al. EACTS/ESVS scientific document group. Current options and recommendations for the treatment of thoracic aortic pathologies involving the aortic arch: an expert consensus document of the European Association for Cardio-Thoracic surgery (EACTS) and the European Society for Vascular Surgery (ESVS). *Eur J Cardiothorac Surg* 2019;55:133–62.
- [137] Preventza O. In type A aortic dissection repair, an effective team approach and relational coordination are more important for patients' outcomes than surgeon volume. *J Thorac Cardiovasc Surg* 2017;154:407–8.
- [138] Mariscalco G, Maselli D, Zanobini M, Ahmed A, Bruno VD, Benedetto U et al. Aortic centres should represent the standard of care for acute aortic syndrome. *Eur J Prev Cardiol* 2018;25:3–14.
- [139] Chisci E, de Donato G, Fargion A, Ventrone G, Parlani G, Setacci C et al. Televascolare Toscana Group. One-year experience of a regional service model of teleconsultation for planning and treatment of complex thoracoabdominal aortic disease. *J Vasc Surg* 2018;67:974–83.
- [140] Berger T, Kreibich M, Rylski B, Schibilsky D, Pooth JS, Fagu A et al. Composition of the surgical team in aortic arch surgery—a risk factor analysis. *Eur J Cardiothorac Surg* 2022;62:ezac171.
- [141] Isselbacher EM, Preventza O, Hamilton Black J 3rd, Augoustides JG, Beck AW, Bolen MA et al. 2022 ACC/AHA Guideline for the diagnosis and management of aortic disease: a report of the American Heart Association/American College of Cardiology Joint Committee on Clinical Practice Guidelines. *Circulation* 2022;146:e334–482.
- [142] Grabenwöger M, Alfonso F, Bachel J, Bonser R, Czerny M, Eggebrecht H et al. European Association of Percutaneous Cardiovascular Interventions (EAPCI). Thoracic Endovascular Aortic Repair (TEVAR) for the treatment of aortic diseases: a position statement from the European Association for Cardio-Thoracic Surgery (EACTS) and the European Society of Cardiology (ESC), in collaboration with the. *Eur J Cardiothorac Surg* 2012;42:17–24.
- [143] McClure RS, Berry RF, Dagenais F, Forbes TL, Grewal J, Keir M et al. The many care models to treat thoracic aortic disease in Canada: a nationwide survey of cardiac surgeons, cardiologists, interventional radiologists, and vascular surgeons. *CJC Open* 2021;3:787–800.
- [144] Carrel T, Sundt TM 3rd, von Kodolitsch Y, Czerny M. Acute aortic dissection. *Lancet* 2023;401:773–88.
- [145] Verhagen JMA, Kempers M, Cozijnsen L, Bouma BJ, Duijnhouwer AL, Post JG et al. National Working Group on BAV & TAA. Expert consensus recommendations on the cardiogenetic care for patients with thoracic

- aortic disease and their first-degree relatives. *Int J Cardiol* 2018;258:243–8.
- [146] Larson DB, Krishnaraj A, Mendelson DS, Langlotz CP, Wald C. Moving toward seamless interinstitutional electronic image transfer. *J Am Coll Radiol* 2022;19:460–8.
- [147] Beckmann E, Martens A, Krueger H, Kaufeld T, Korte W, Stettinger A et al. Aortic valve-sparing root replacement (David): learning curve and impact on outcome. *Interact CardioVasc Thorac Surg* 2020;30:754–61.
- [148] Hafen L, Shutze WP, Potluri S, Squiers JJ, DiMaio JM, Brinkman WT. Heart team approach for comprehensive management of aortic coarctation in the adult. *Ann Cardiothorac Surg* 2022;11:37–45.
- [149] Drayton DJ, Howard S, Hammond C, Bekker HL, Russell DA, Howell SJ. Multidisciplinary team decisions in management of abdominal aortic aneurysm: a service and quality evaluation. *EJVES Vasc Forum* 2022;54:49–53.
- [150] Martinez BD, Zarins CK, Daunt DA, Coleman LA, Saenz Y, Fogarty TJ et al. A porcine model for endolaparoscopic abdominal aortic repair and endoscopic training. *JSL* 2003;7:129–36.
- [151] Tozzi P, Ferrari E, Reuthebuch O, Matt P, Huber C, Eckstein F et al. Humanoids for teaching and training coronary artery bypass surgery to the next generation of cardiac surgeons. *Interact CardioVasc Thorac Surg* 2022;34:185–92.
- [152] Barth U, Meyer F, Halloul Z. [Specifics of teaching in vascular surgery in an interdisciplinary surgical setting]. *Chirurgie (Heidelberg)* 2022;93:966–75.
- [153] Smit FE, Jones TJ, Mestres CA, Sadaba JR, Pillay J, Yankah C et al. Integrated interdisciplinary simulation programmes: an essential addition to national and regional cardiothoracic surgical training and education programmes. *Eur J Cardiothorac Surg* 2019;55:811–6.
- [154] Korte W, Merz C, Kirchhoff F, Heimeshoff J, Goecke T, Beckmann E et al. Train early and with deliberate practice: simple coronary surgery simulation platform results in fast increase in technical surgical skills in residents and students. *Interact CardioVasc Thorac Surg* 2020;30:871–8.
- [155] Skov RAC, Lawaetz J, Konge L, Westerlin L, Aasvang EK, Meyhoff CS et al. Simulation-based education of endovascular scrub nurses reduces stress and improves team performance. *J Surg Res* 2022;280:209–17.
- [156] Ramella A, Migliavacca F, Rodriguez Matas JF, Heim F, Dedola F, Marconi S et al. Validation and verification of high-fidelity simulations of thoracic stent-graft implantation. *Ann Biomed Eng* 2022;50:1941–53.
- [157] Czerny M, Bachet J, Bavaria J, Bonser RS, Borger MA, De Paulis R et al. The future of aortic surgery in Europe. *Eur J Cardiothorac Surg* 2013;43:226–30.
- [158] Bottle A, Mariscalco G, Shaw MA, Benedetto U, Saratzis A, Mariani S et al. Unwarranted variation in the quality of care for patients with diseases of the thoracic aorta. *J Am Heart Assoc* 2017;6:e004913.
- [159] Kolh P, De Hert S, De Rango P. The concept of risk assessment and being unfit for surgery. *Eur J Vasc Endovasc Surg* 2016;51:857–66.
- [160] Ganapathi AM, Englum BR, Hanna JM, Schechter MA, Gaca JG, Hurwitz LM et al. Frailty and risk in proximal aortic surgery. *J Thorac Cardiovasc Surg* 2014;147:186–91.e1.
- [161] Panthofer AM, Olson SL, Harris DG, Matsumura JS. Derivation and validation of thoracic sarcopenia assessment in patients undergoing thoracic endovascular aortic repair. *J Vasc Surg* 2019;69:1379–86.
- [162] Berger T, Kreibich M, Mueller F, Breurer-Kellner L, Rylski B, Kondov S et al. Risk factors for stroke after total aortic arch replacement using the frozen elephant trunk technique. *Interact CardioVasc Thorac Surg* 2022;34:865–71.
- [163] O'Driscoll JM, Bahia SS, Gravina A, Di Fino S, Thompson MM, Karthikesalingam A et al. Transthoracic echocardiography provides important long-term prognostic information in selected patients undergoing endovascular abdominal aortic repair. *Circ Cardiovasc Imaging* 2016;9:e003557.
- [164] Wenzel JP, Nikorowitsch J, Bei der Kellen R, Dohm L, Girdauskas E, Lund G et al. Comparison of cine cardiac magnetic resonance and echocardiography derived diameters of the aortic root in a large population-based cohort. *Sci Rep* 2022;12:15307.
- [165] Sutarjono B, Ahmed AJ, Ivanova A, Buchel B, Rauscher J, O'Connell A et al. Diagnostic accuracy of transthoracic echocardiography for the identification of proximal aortic dissection: a systematic review and meta-analysis. *Sci Rep* 2023;13:5886.
- [166] Ganapathi AM, Englum BR, Schechter MA, Vavalle JP, Harrison JK, McCann RL et al. Role of cardiac evaluation before thoracic endovascular aortic repair. *J Vasc Surg* 2014;60:1196–203.
- [167] Gertz ZM, Levitt SA, Epps KC, Bavaria JE, Moser GW, Kolansky DM. Cardiac catheterization in patients with ascending aortic aneurysms: safety, success, and prevalence of coronary artery disease. *J Invasive Cardiol* 2014;26:241–4.
- [168] Evangelista A, Sitges M, Jondeau G, Nijveldt R, Pepi M, Cuellar H et al. Multimodality imaging in thoracic aortic diseases: a clinical consensus statement from the European Association of Cardiovascular Imaging and the European Society of Cardiology working group on aorta and peripheral vascular diseases. *Eur Heart J Cardiovasc Imaging* 2023;24:e65–85.
- [169] Milewicz DM, Guo D, Hostetler E, Marin I, Pinard AC, Cecchi AC. Update on the genetic risk for thoracic aortic aneurysms and acute aortic dissections: implications for clinical care. *J Cardiovasc Surg (Torino)* 2021;62:203–10.
- [170] Halvorsen S, Mehilli J, Cassese S, Hall TS, Abdelhamid M, Barbato E et al. ESC Scientific Document Group. 2022 ESC Guidelines on cardiovascular assessment and management of patients undergoing non-cardiac surgery. *Eur Heart J* 2022;43:3826–924.
- [171] Sorrentino R, Santoro C, Bardi L, Rigolin V, Gentile F. Non-cardiac surgery in patients with valvular heart disease. *Heart* 2022;108:1171–8.
- [172] Katz S, Ford AB, Moskowitz RW, Jackson BA, Jaffe MW. Studies of illness in the aged. The index of ADL: a standardized measure of biological and psychosocial function. *JAMA* 1963;185:914–9.
- [173] Lansky AJ, Messé SR, Brickman AM, Dwyer M, van der Worp HB, Lazar RM et al. Proposed standardized neurological endpoints for cardiovascular clinical trials: an Academic Research Consortium Initiative. *J Am Coll Cardiol* 2017;69:679–91.
- [174] Pal SK, Katheria V, Hurria A. Evaluating the older patient with cancer: understanding frailty and the geriatric assessment. *CA Cancer J Clin* 2010;60:120–32.
- [175] Fann JL. Descending thoracic and thoracoabdominal aortic aneurysm. *Coron Artery Dis* 2023;13:93–102.
- [176] Czerny M, Eggebrecht H, Sodeck G, Verzini F, Cao P, Maritati G et al. Mechanisms of symptomatic spinal cord ischemia after TEVAR: insights from the European Registry of Endovascular Aortic Repair Complications (EuREC). *J Endovasc Ther* 2012;19:37–43.
- [177] Papatheev V, Stoinova V, Aleksandrov A, Todorova-Papantcheva D, Hristov S, Petkov D et al. The role of Willis circle variations during unilateral selective cerebral perfusion: a study of 500 circles. *Eur J Cardiothorac Surg* 2013;44:743–53.
- [178] Abjigitova D, Veen KM, van Tussenbroek G, Mokhles MM, Bekkers JA, Takkenberg JJM et al. Cerebral protection in aortic arch surgery: systematic review and meta-analysis. *Interact CardioVasc Thorac Surg* 2022;35:ivac128.
- [179] Heber UM, Mayrhofer M, Gottardi R, Kari FA, Heber S, Windisch A et al. The intraspinal arterial collateral network: a new anatomical basis for understanding and preventing paraplegia during aortic repair. *Eur J Cardiothorac Surg* 2021;59:137–44.
- [180] Etz CD, Kari FA, Mueller CS, Silovitz D, Brenner RM, Lin HM et al. The collateral network concept: a reassessment of the anatomy of spinal cord perfusion. *J Thorac Cardiovasc Surg* 2011;141:1020–8.
- [181] Etz CD, Kari FA, Mueller CS, Brenner RM, Lin HM, Griep RB. The collateral network concept: remodeling of the arterial collateral network after experimental segmental artery sacrifice. *J Thorac Cardiovasc Surg* 2011;141:1029–36.
- [182] Petroff D, Czerny M, Kölbl T, Melissano G, Lonn L, Haunschild J et al. Paraplegia prevention in aortic aneurysm repair by thoracoabdominal staging with 'minimally invasive staged segmental artery coil embolisation' (MIS<sup>2</sup>ACE): trial protocol for a randomised controlled multicentre trial. *BMJ Open* 2019;9:e025488.
- [183] Schlett CL, Hendel T, Hirsch J, Weckbach S, Caspers S, Schulz-Menger J et al. Quantitative, organ-specific interscanner and intrascanner variability for 3 T whole-body magnetic resonance imaging in a multicenter, multivendor study. *Invest Radiol* 2016;51:255–65.
- [184] Rajendran K, Petersilka M, Henning A, Shanblatt ER, Schmidt B, Flohr TG et al. First clinical photon-counting detector CT system: technical evaluation. *Radiology* 2022;303:130–8.
- [185] Euler A, Higashigaito K, Mergen V, Sartoretto T, Zanini B, Schmidt B et al. High-pitch photon-counting detector computed tomography angiography of the aorta: intraindividual comparison to energy-integrating detector computed tomography at equal radiation dose. *Invest Radiol* 2022;57:115–21.
- [186] Yoshida S, Akiba H, Tamakawa M, Yama N, Hareyama M, Morishita K et al. Thoracic involvement of type A aortic dissection and intramural

- hematoma: diagnostic accuracy—comparison of emergency helical CT and surgical findings. *Radiology* 2003;228:430–5.
- [187] Thoongsuwan N, Stern EJ. Chest CT scanning for clinical suspected thoracic aortic dissection: beware the alternate diagnosis. *Emerg Radiol* 2002;9:257–61.
- [188] Catalán P, Leta R, Hidalgo A, Montiel J, Alomar X, Viladés D et al. Ruling out coronary artery disease with noninvasive coronary multidetector CT angiography before noncoronary cardiovascular surgery. *Radiology* 2011;258:426–34.
- [189] Kurtelius A, Vántti N, Rezaei Jahromi B, Tähtinen O, Manninen H, Koskenvuo J et al. Association of intracranial aneurysms with aortic aneurysms in 125 patients with fusiform and 4253 patients with saccular intracranial aneurysms and their family members and population controls. *J Am Heart Assoc* 2019;8:e013277.
- [190] Lee D, Ahn SJ, Cho ES, Kim YB, Song SW, Jung WS et al. High prevalence of intracranial aneurysms in patients with aortic dissection or aneurysm: feasibility of extended aorta CT angiography with involvement of intracranial arteries. *J Neurointerv Surg* 2017;9:1017–21.
- [191] van der Molen AJ, Reimer P, Dekkers IA, Bongartz G, Bellin MF, Bertolotto M et al. Post-contrast acute kidney injury—part 1: definition, clinical features, incidence, role of contrast medium and risk factors: recommendations for updated ESUR Contrast Medium Safety Committee guidelines. *Eur Radiol* 2018;28:2845–55.
- [192] Powell JT. Mortality results for randomised controlled trial of early elective surgery or ultrasonographic surveillance for small abdominal aortic aneurysms. The UK Small Aneurysm Trial Participants. *Lancet* 1998;352:1649–55.
- [193] Monti CB, van Assen M, Stillman AE, Lee SJ, Hoelzer P, Fung GSK et al. Evaluating the performance of a convolutional neural network algorithm for measuring thoracic aortic diameters in a heterogeneous population. *Radiol Artif Intell* 2022;4:e210196.
- [194] Dux-Santoy L, Rodríguez-Palmares JF, Teixidó-Turà G, Ruiz-Muñoz A, Casas G, Valente F et al. Registration-based semi-automatic assessment of aortic diameter growth rate from contrast-enhanced computed tomography outperforms manual quantification. *Eur Radiol* 2022;32:1997–2009.
- [195] Macruz FBC, Lu C, Strout J, Takigami A, Brooks R, Doyle S et al. Quantification of the thoracic aorta and detection of aneurysm at CT: development and validation of a fully automatic methodology. *Radiol Artif Intell* 2022;4:e210076.
- [196] Wu J, Zafar MA, Li Y, Saeyeldin A, Huang Y, Zhao R et al. Ascending aortic length and risk of aortic adverse events: the neglected dimension. *J Am Coll Cardiol* 2019;74:1883–94.
- [197] Markl M, Hope MD. 4D flow imaging—state of the art. *Ann Cardiothorac Surg* 2022;11:468–9.
- [198] Bissell MM, Hess AT, Biasioli L, Glaze SJ, Loudon M, Pitcher A et al. Aortic dilation in bicuspid aortic valve disease: flow pattern is a major contributor and differs with valve fusion type. *Circ Cardiovasc Imaging* 2013;6:499–507.
- [199] Burriss NS, Nordsletten DA, Sotelo JA, Grogan-Kaylor R, Houben IB, Figueroa CA et al. False lumen ejection fraction predicts growth in type B aortic dissection: preliminary results. *Eur J Cardiothorac Surg* 2020;57:896–903.
- [200] Ruiz-Muñoz A, Guala A, Dux-Santoy L, Teixidó-Turà G, Servato ML, Valente F et al. False lumen rotational flow and aortic stiffness are associated with aortic growth rate in patients with chronic aortic dissection of the descending aorta: a 4D flow cardiovascular magnetic resonance study. *J Cardiovasc Magn Reson* 2022;24:20.
- [201] Takahashi K, Sekine T, Miyagi Y, Shirai S, Otsuka T, Kumita S et al. Four-dimensional flow analysis reveals mechanism and impact of turbulent flow in the dissected aorta. *Eur J Cardiothorac Surg* 2021;60:1064–72.
- [202] Oechtering TH, Sieren MM, Hunold P, Hennemuth A, Huellebrand M, Scharfschwerdt M et al. Time-resolved 3-dimensional magnetic resonance phase contrast imaging (4D Flow MRI) reveals altered blood flow patterns in the ascending aorta of patients with valve-sparing aortic root replacement. *J Thorac Cardiovasc Surg* 2020;159:798–810.e1.
- [203] Schulz CJ, Schmitt M, Böckler D, Geisbüsch P. Fusion imaging to support endovascular aneurysm repair using 3D-3D registration. *J Endovasc Ther* 2016;23:791–9.
- [204] García-Vázquez V, von Haxthausen F, Jäckle S, Schumann C, Kuhlemann I, Bouchagiar J et al. Navigation and visualisation with HoloLens in endovascular aortic repair. *Innov Surg Sci* 2018;3:167–77.
- [205] Marti P, Lampus F, Benevento D, Setacci C. Trends in use of 3D printing in vascular surgery: a survey. *Int Angiol* 2019;38:418–24.
- [206] Sartoretto T, Wildberger JE, Flohr T, Alkadhri H. Photon-counting detector CT: early clinical experience review. *Br J Radiol* 2023;96:20220544.
- [207] Dangelmaier J, Bar-Ness D, Daerr H, Muenzel D, Si-Mohamed S, Ehn S et al. Experimental feasibility of spectral photon-counting computed tomography with two contrast agents for the detection of endoleaks following endovascular aortic repair. *Eur Radiol* 2018;28:3318–25.
- [208] Silaschi M, Byrne J, Wendler O. Aortic dissection: medical, interventional and surgical management. *Heart* 2017;103:78–87.
- [209] Suzuki T, Isselbacher EM, Nienaber CA, Pyeritz RE, Eagle KA, Tsai TT et al. IRAD Investigators. Type-selective benefits of medications in treatment of acute aortic dissection (from the International Registry of Acute Aortic Dissection [IRAD]). *Am J Cardiol* 2012;109:122–7.
- [210] Alviar CL, Gutierrez A, Cho L, Krishnaswamy A, Saleh A, Lincoff MA et al. Clevidipine as a therapeutic and cost-effective alternative to sodium nitroprusside in patients with acute aortic syndromes. *Eur Heart J Acute Cardiovasc Care* 2020;9:55–12.
- [211] Evangelista A, Isselbacher EM, Bossone E, Gleason TG, Eusanio MD, Sechtem U et al. IRAD Investigators. Insights from the International Registry of Acute Aortic Dissection: a 20-year experience of collaborative clinical research. *Circulation* 2018;137:1846–60.
- [212] Pape LA, Awais M, Woznicki EM, Suzuki T, Trimarchi S, Evangelista A et al. Presentation, diagnosis, and outcomes of acute aortic dissection: 17-year trends from the International Registry of Acute Aortic Dissection. *J Am Coll Cardiol* 2015;66:350–8.
- [213] Inoue Y, Minatoya K, Oda T, Itonaga T, Seike Y, Tanaka H et al. Surgical outcomes for acute type A aortic dissection with aggressive primary entry resection. *Eur J Cardiothorac Surg* 2016;50:567–73.
- [214] Heo W, Song SW, Lee KH, Kim TH, Baek MY, Yoo KJ et al. Residual arch tears and major adverse events after acute DeBakey type I aortic dissection repair. *Ann Thorac Surg* 2018;106:1079–86.
- [215] Most H, Reinhard B, Gahl B, Englberger L, Kadner A, Weber A et al. Is surgery in acute aortic dissection type A still contraindicated in the presence of preoperative neurological symptoms? *Eur J Cardiothorac Surg* 2015;48:945–50.
- [216] Dumfarth J, Kofler M, Stastny L, Gasser S, Plaikner M, Semsroth S et al. Immediate surgery in acute type A dissection and neurologic dysfunction: fighting the inevitable? *Ann Thorac Surg* 2020;110:5–12.
- [217] Ghoreishi M, Sundt TM, Cameron DE, Holmes SD, Roselli EE, Pasrija C et al. Factors associated with acute stroke after type A aortic dissection repair: an analysis of the Society of Thoracic Surgeons National Adult Cardiac Surgery Database. *J Thorac Cardiovasc Surg* 2020;159:2143–54.e3.
- [218] Benedetto U, Mohamed H, Vitulli P, Petrou M. Axillary versus femoral arterial cannulation in type A acute aortic dissection: evidence from a meta-analysis of comparative studies and adjusted risk estimates. *Eur J Cardiothorac Surg* 2015;48:953–9.
- [219] Ren Z, Wang Z, Hu R, Wu H, Deng H, Zhou Z et al. Which cannulation (axillary cannulation or femoral cannulation) is better for acute type A aortic dissection repair? A meta-analysis of nine clinical studies. *Eur J Cardiothorac Surg* 2015;47:408–15.
- [220] Geirsson A, Shioda K, Olsson C, Ahlsson A, Gunn J, Hansson EC et al. Differential outcomes of open and clamp-on distal anastomosis techniques in acute type A aortic dissection. *J Thorac Cardiovasc Surg* 2019;157:1750–8.
- [221] Malvindi PG, Modi A, Miskolczi S, Kaarne M, Velissaris T, Barlow C et al. Open and closed distal anastomosis for acute type A aortic dissection repair. *Interact CardioVasc Thorac Surg* 2016;22:776–83.
- [222] Yao J, Bai T, Yang B, Sun L. The diagnostic value of D-dimer in acute aortic dissection: a meta-analysis. *J Cardiothorac Surg* 2021;16:343.
- [223] Harris KM, Nienaber CA, Peterson MD, Woznicki EM, Braverman AC, Trimarchi S et al. Early mortality in type A acute aortic dissection: insights from the International Registry of Acute Aortic Dissection. *JAMA Cardiol* 2022;7:1009–15.
- [224] Catalano MA, Mamdouhi T, Pupovac S, Kennedy KF, Brinster DR, Hartman A et al. Age, sex, and contemporary outcomes in surgical repair of type A aortic dissection: insights from the National Inpatient Sample. *JTCVS Open* 2022;11:23–36.
- [225] Ahmad RA, Orelaru F, Titsworth M, Wu X, Kim KM, Fukuhara S et al. Contemporary nonsurgical management of acute type A aortic dissection: better outcomes? *J Thorac Cardiovasc Surg* 2022;S0022-5223(22)01012-1.
- [226] De Freitas S, Rossi MJ, Abramowitz SD, Fatima J, Kiguchi MM, Vallabhaneni R et al. Systematic review and meta-analysis of endovascular interventions for Stanford type A aortic dissection. *J Vasc Surg* 2021;74:1721–31.e4.

- [227] Czerny M, Schoenhoff F, Etz C, Englberger L, Khaladj N, Zierer A et al. The impact of pre-operative malperfusion on outcome in acute type A aortic dissection: results from the GERAADA Registry. *J Am Coll Cardiol* 2015;65:2628-35.
- [228] Tsagakis K, Konorza T, Dohle DS, Kottenberg E, Buck T, Thielmann M et al. Hybrid operating room concept for combined diagnostics, intervention and surgery in acute type A dissection. *Eur J Cardiothorac Surg* 2013;43:397-404.
- [229] Wolfe SB, Sundt TM 3rd, Isselbacher EM, Cameron DE, Trimarchi S, Bekeredjian R et al. IRAD researchers. Survival after operative repair of acute type A aortic dissection varies according to the presence and type of preoperative malperfusion. *J Thorac Cardiovasc Surg* 2022;S0022-5223(22)01024-8.
- [230] Yang B, Norton EL, Rosati CM, Wu X, Kim KM, Khaja MS et al. Managing patients with acute type A aortic dissection and mesenteric malperfusion syndrome: a 20-year experience. *J Thorac Cardiovasc Surg* 2019;158:675-87.e4.
- [231] Xu X, Wu Y, Wu Z. Revascularization-first strategy versus central repair-first strategy for acute type A aortic dissection complicated with mesenteric malperfusion syndrome: a meta-analysis. *J Card Surg* 2022;37:4427-33.
- [232] Hashimoto O, Saito Y, Sasaki H, Yumoto K, Oshima S, Tobaru T et al. Angina Pectoris-Myocardial Infarction Multicenter Investigators. Treatment strategies and in-hospital mortality in patients with type A acute aortic dissection and coronary artery involvement. *J Thorac Cardiovasc Surg* 2024;167:596-601.e3.
- [233] Neri E, Toscano T, Papalia U, Frati G, Massetti M, Capannini G et al. Proximal aortic dissection with coronary malperfusion: presentation, management, and outcome. *J Thorac Cardiovasc Surg* 2001;121:552-60.
- [234] Tong G, Wu J, Chen Z, Zhuang D, Zhao S, Liu Y et al. Coronary malperfusion secondary to acute type A aortic dissection: surgical management based on a modified Neri classification. *J Clin Med* 2022;11:1693.
- [235] Kreibich M, Bavaria JE, Branchetti E, Brown CR, Chen Z, Khurshan F et al. Management of patients with coronary artery malperfusion secondary to type A aortic dissection. *Ann Thorac Surg* 2019;107:1174-80.
- [236] Morimoto N, Okada K, Okita Y. Lack of neurologic improvement after aortic repair for acute type A aortic dissection complicated by cerebral malperfusion: predictors and association with survival. *J Thorac Cardiovasc Surg* 2011;142:1540-4.
- [237] Chiu P, Rotto TJ, Goldstone AB, Whisenant JB, Woo YJ, Fischbein MP. Time-to-operation does not predict outcome in acute type A aortic dissection complicated by neurologic injury at presentation. *J Thorac Cardiovasc Surg* 2019;158:665-72.
- [238] Long SM, Tribble CG, Raymond DP, Fiser SM, Kaza AK, Kern JA et al. Preoperative shock determines outcome for acute type A aortic dissection. *Ann Thorac Surg* 2003;75:520-4.
- [239] Olsson C, Ahlsson A, Fuglsang S, Geirsson A, Gunn J, Hansson EC et al. Medium-term survival after surgery for acute type A aortic dissection is improving. *Eur J Cardiothorac Surg* 2017;52:852-7.
- [240] Kawahito K, Aizawa K, Kimura N, Yamaguchi A, Adachi H. Influence of residual primary entry following the tear-oriented strategy for acute type A aortic dissection. *Eur J Cardiothorac Surg* 2022;61:1077-84.
- [241] Inoue Y, Matsuda H, Matsuo J, Shijo T, Omura A, Seike Y et al. Efficacy of entry exclusion strategy for DeBakey type III retrograde Stanford type A acute aortic dissection. *Eur J Cardiothorac Surg* 2020;ezaa329.
- [242] Trimarchi S, de Beaufort HWL, Tolenaar JL, Bavaria JE, Desai ND, Di Eusanio M et al. Acute aortic dissections with entry tear in the arch: a report from the International Registry of Acute Aortic Dissection. *J Thorac Cardiovasc Surg* 2019;157:66-73.
- [243] Luo C, Qi R, Zhong Y, Chen S, Liu H, Guo R et al. Early and long-term follow-up for chronic type B and type non-A non-B aortic dissection using the frozen elephant trunk technique. *Front Cardiovasc Med* 2021;8:714638.
- [244] Wang W, Piao H, Wang Y, Li B, Zhu Z, Wang T et al. Early outcomes with a hybrid technique for repair of a non-A non-B aortic dissection. *J Thorac Cardiovasc Surg* 2022;163:1766-74.
- [245] Liu J, Yang F, Chen L, Xie E, Su S, Liu Y et al. Management and outcomes of non-A non-B aortic dissection. *Eur J Vasc Endovasc Surg* 2022;64:497-506.
- [246] Li Q, Wu Q, Wu W, Dai X, Fang G, Xie X et al. Triple-branched stent graft implantation for acute non-A-non-B aortic dissection. *Ann Thorac Surg* 2023;115:583-9.
- [247] Kreibich M, Siepe M, Berger T, Kondov S, Morlock J, Pingpoh C et al. The frozen elephant trunk technique for the treatment of type B and type non-A non-B aortic dissection. *Eur J Vasc Endovasc Surg* 2021;61:107-13.
- [248] Hauck SR, Kupferthaler A, Kern M, Rousseau H, Ferrer C, Iwakoshi S et al. Branched versus fenestrated thoracic endovascular aortic repair in the aortic arch: a multicenter comparison. *J Thorac Cardiovasc Surg* 2022;164:1379-89.e1.
- [249] Nienaber CA, Kische S, Rousseau H, Eggebrecht H, Rehders TC, Kundt G et al. INSTEAD-XL trial. Endovascular repair of type B aortic dissection: long-term results of the randomized investigation of stent grafts in aortic dissection trial. *Circ Cardiovasc Interv* 2013;6:407-16.
- [250] Nienaber CA, Rousseau H, Eggebrecht H, Kische S, Fattori R, Rehders TC et al. INSTEAD Trial. Randomized comparison of strategies for type B aortic dissection: the INvestigation of STEnt Grafts in Aortic Dissection (INSTEAD) trial. *Circulation* 2009;120:2519-28.
- [251] Brunkwall J, Kasprzak P, Verhoeven E, Heijmen R, Taylor P, Alric P et al. ADSORB Trialists. Endovascular repair of acute uncomplicated aortic type B dissection promotes aortic remodelling: 1 year results of the ADSORB trial. *Eur J Vasc Endovasc Surg* 2014;48:285-91.
- [252] Liu D, Luo H, Lin S, Zhao L, Qiao C. Comparison of the efficacy and safety of thoracic endovascular aortic repair with open surgical repair and optimal medical therapy for acute type B aortic dissection: a systematic review and meta-analysis. *Int J Surg* 2020;83:53-61.
- [253] Li FR, Wu X, Yuan J, Wang J, Mao C, Wu X. Comparison of thoracic endovascular aortic repair, open surgery and best medical treatment for type B aortic dissection: a meta-analysis. *Int J Cardiol* 2018;250:240-6.
- [254] Kreibich M, Berger T, Morlock J, Kondov S, Scheumann J, Kari FA et al. The frozen elephant trunk technique for the treatment of acute complicated type B aortic dissection. *Eur J Cardiothorac Surg* 2018;53:525-30.
- [255] Weiss G, Tsagakis K, Jakob H, Di Bartolomeo R, Pacini D, Barberio G et al. The frozen elephant trunk technique for the treatment of complicated type B aortic dissection with involvement of the aortic arch: multicentre early experience. *Eur J Cardiothorac Surg* 2015;47:106-14.
- [256] Estrera AL, Miller CC 3rd, Safi HJ, Goodrick JS, Keyhani A, Porat EE et al. Outcomes of medical management of acute type B aortic dissection. *Circulation* 2006;114:1384-9.
- [257] Muller M, Yau P, Pham A, Lipsitz EC, DeRose JJ, Cho JS et al. A comparison of endovascular repair to medical management for acute vs subacute uncomplicated type B aortic dissections. *J Vasc Surg* 2023;78:53-60.
- [258] Obel LM, Lindholt JS, Lasota AN, Jensen HK, Benhassen LL, Kristensen AL et al. Aortic dissections in the population-based Danish National Patient Registry from 1996-2016: a validation study. *Clin Epidemiol* 2022;14:51-8.
- [259] Weiss G, Wolner I, Folkmann S, Sodeck G, Schmidl J, Grabenwöger M et al. The location of the primary entry tear in acute type B aortic dissection affects early outcome. *Eur J Cardiothorac Surg* 2012;42:571-6.
- [260] Trimarchi S, Jonker FH, van Bogerijen GH, Tolenaar JL, Moll FL, Czerny M et al. Predicting aortic enlargement in type B aortic dissection. *Ann Cardiothorac Surg* 2014;3:285-91.
- [261] Evangelista A, Salas A, Ribera A, Ferreira-González I, Cuellar H, Pineda V et al. Long-term outcome of aortic dissection with patent false lumen: predictive role of entry tear size and location. *Circulation* 2012;125:3133-41.
- [262] Codner JA, Lou X, Duwayri YM, Chen EP, Binongo JN, Moon R et al. The distance of the primary intimal tear from the left subclavian artery predicts aortic growth in uncomplicated type B aortic dissection. *J Vasc Surg* 2019;69:692-700.
- [263] Evangelista A, Pineda V, Guala A, Bijnens B, Cuellar H, Rudenick P et al. False lumen flow assessment by magnetic resonance imaging and long-term outcomes in uncomplicated aortic dissection. *J Am Coll Cardiol* 2022;79:2415-27.
- [264] Ante M, Mylonas S, Skrypnik D, Bischoff MS, Rengier F, Brunkwall J et al. Prevalence of the computed tomographic morphological DISSECT predictors in uncomplicated Stanford type B aortic dissection. *Eur J Vasc Endovasc Surg* 2018;56:525-33.
- [265] Song JM, Kim SD, Kim JH, Kim MJ, Kang DH, Seo JB et al. Long-term predictors of descending aorta aneurysmal change in patients with aortic dissection. *J Am Coll Cardiol* 2007;50:799-804.

- [266] Juvonen T, Ergin MA, Galla JD, Lansman SL, McCullough JN, Nguyen K et al. Risk factors for rupture of chronic type B dissections. *J Thorac Cardiovasc Surg* 1999;117:776-86.
- [267] Beregi JP, Haulon S, Otal P, Thony F, Bartoli JM, Crochet D et al. Société Française d'Imagerie Cardio-Vasculaire (SFICV) Research Group on Aortic Dissection. Endovascular treatment of acute complications associated with aortic dissection: midterm results from a multicenter study. *J Endovasc Ther* 2003;10:486-93.
- [268] Kreibich M, Siepe M, Berger T, Beyersdorf F, Soschynski M, Schlett CL et al. Intervention rates and outcomes in medically managed uncomplicated descending thoracic aortic dissections. *J Thorac Cardiovasc Surg* 2021;165:958-65.e4.
- [269] Weissler EH, Osazuwa-Peters OL, Greiner MA, Hardy NC, Kougiyas P, O'Brien SM et al. Initial thoracic endovascular aortic repair vs medical therapy for acute uncomplicated type B aortic dissection. *JAMA Cardiol* 2023;8:44-53.
- [270] Schwartz SI, Durham C, Clouse WD, Patel VI, Lancaster RT, Cambria RP et al. Predictors of late aortic intervention in patients with medically treated type B aortic dissection. *J Vasc Surg* 2018;67:78-84.
- [271] Sailer AM, van Kuijk SM, Nelemans PJ, Chin AS, Kino A, Huininga M et al. Computed tomography imaging features in acute uncomplicated Stanford type-B aortic dissection predict late adverse events. *Circ Cardiovasc Imaging* 2017;10:e005709.
- [272] Mastrodicasa D, Willemink MJ, Turner VL, Hinostroza V, Codari M, Hanneman K et al. Registry of Aortic Diseases to Model Adverse Events and Progression (ROADMAP) in uncomplicated type B aortic dissection: study design and rationale. *Radiol Cardiothorac Imaging* 2022;4:e220039.
- [273] Lombardi JV, Gleason TG, Panneton JM, Starnes BW, Dake MD, Haulon S et al. STABLE II investigators. Five-year results of the STABLE II study for the endovascular treatment of complicated, acute type B aortic dissection with a composite device design. *J Vasc Surg* 2022;76:1189-97.e3.
- [274] The VIRTUE Registry Investigators. Mid-term outcomes and aortic remodelling after thoracic endovascular repair for acute, subacute, and chronic aortic dissection: the VIRTUE Registry. *Eur J Vasc Endovasc Surg* 2014;48:363-71.
- [275] Chia MC, Khorfan R, Eskandari MK. Adjunctive branch interventions during thoracic endovascular aortic repair for acute complicated type B dissection are not associated with inferior outcomes. *J Vasc Surg* 2021;74:895-901.
- [276] Liu Y, Jiang X, Chen B, Jiang J, Ma T, Dong Z et al. Risk factors and treatment outcomes for type B aortic dissection with malperfusion requiring adjunctive procedures after thoracic endovascular aortic repair. *J Vasc Surg* 2022;75:1192-200.e2.
- [277] Reutersberg B, Gleason T, Desai N, Ehrlich M, Evangelista A, Braverman A et al. Neurological event rates and associated risk factors in acute type B aortic dissections treated by thoracic aortic endovascular repair. *J Thorac Cardiovasc Surg* 2022;167:52-62.e5.
- [278] Lortz J, Leinburger F, Tsagakis K, Rammos C, Lind A, Schlosser T et al. Distal stent graft induced new entry: risk factors in acute and chronic type B aortic dissections. *Eur J Vasc Endovasc Surg* 2019;58:822-30.
- [279] Spinelli D, Weaver FA, Azzizadeh A, Magee GA, Piffaretti G, Benedetto F et al. Endovascular treatment of complicated versus uncomplicated acute type B aortic dissection. *J Thorac Cardiovasc Surg* 2023;165:4-13.e1.
- [280] Di Marco L, Pantaleo A, Leone A, Murana G, Di Bartolomeo R, Pacini D. The frozen elephant trunk technique: European Association for Cardio-Thoracic Surgery Position and Bologna Experience. *Korean J Thorac Cardiovasc Surg* 2017;50:1-7.
- [281] Lau C, Soletti GJ, Lawrence KM, Rahouma M, Iannacone E, Gambardella I et al. Contemporary outcomes of open repair of acute complicated type B aortic dissection. *J Vasc Surg* 2023;78:593-601.e4.
- [282] Erbel R, Aboyans V, Boileau C, Bossone E, Bartolomeo RD, Eggebrecht H et al. 2014 ESC Guidelines on the diagnosis and treatment of aortic diseases: document covering acute and chronic aortic diseases of the thoracic and abdominal aorta of the adult. The Task Force for the Diagnosis and Treatment of Aortic Diseases of the European Society of Cardiology (ESC). *Eur Heart J* 2014;35:2873-926.
- [283] Yen HT, Wu CC, Lee YW, Lo CM, Chen YY. CT characteristics and clinical implications of acute type A aortic intramural hematoma. *Front Cardiovasc Med* 2022;9:1041796.
- [284] Kim MS, Kim TH, Lee H, Song SW, Heo W, Sim SA et al. Note the descending aorta: predictors of postoperative major adverse aortic event in pure acute type A intramural hematoma. *J Thorac Dis* 2021;13:4935-46.
- [285] Moral S, Cuéllar H, Avegliano G, Ballesteros E, Salcedo MT, Ferreira-González I et al. Clinical implications of focal intimal disruption in patients with type B intramural hematoma. *J Am Coll Cardiol* 2017;69:28-39.
- [286] Evangelista A, Moral S, Ballesteros E, Castillo-Gandía A. Beyond the term penetrating aortic ulcer: a morphologic descriptor covering a constellation of entities with different prognoses. *Prog Cardiovasc Dis* 2020;63:488-95.
- [287] von Kodolitsch Y, Csösz SK, Koschyk DH, Schalwat I, Loose R, Karck M et al. Intramural hematoma of the aorta: predictors of progression to dissection and rupture. *Circulation* 2003;107:1158-63.
- [288] Estrera A, Miller C, Lee T-Y, De Rango P, Abdullah S, Walkes J-C et al. Acute type A intramural hematoma: analysis of current management strategy. *Circulation* 2009;120:S287-91.
- [289] Chou AS, Ziganshin BA, Charilaou P, Tranquilli M, Rizzo JA, Elefteriades JA. Long-term behavior of aortic intramural hematomas and penetrating ulcers. *J Thorac Cardiovasc Surg* 2016;151:361-72, 373.e1.
- [290] Chow SCY, Wong RHL, Lakhani I, Wong MV, Tse G, Yu PSY et al. Management of acute type A intramural hematoma: upfront surgery or individualized approach? A retrospective analysis and meta-analysis. *J Thorac Dis* 2020;12:680-9.
- [291] Kageyama S, Mitake H, Nakajima A, Kodama K, Hattori Y, Watanabe Y et al. A novel risk score on admission for predicting death or need for surgery in patients with acute type A intramural hematoma receiving medical therapy. *Heart Vessels* 2020;35:1164-70.
- [292] Watanabe S, Hanyu M, Arai Y, Nagasawa A. Initial medical treatment for acute type A intramural hematoma and aortic dissection. *Ann Thorac Surg* 2013;96:2142-6.
- [293] Nishigami K, Tsuchiya T, Shono H, Horibata Y, Honda T. Disappearance of aortic intramural hematoma and its significance to the prognosis. *Circulation* 2000;102:11243-7.
- [294] Kaji S, Akasaka T, Katayama M, Yamamuro A, Yamabe K, Tamita K et al. Long-term prognosis of patients with type B aortic intramural hematoma. *Circulation* 2003;108 Suppl 1:ii307-11.
- [295] Evangelista A, Dominguez R, Sebastia C, Salas A, Permanyer-Miralda G, Avegliano G et al. Long-term follow-up of aortic intramural hematoma: predictors of outcome. *Circulation* 2003;108:583-9.
- [296] Mesar T, Lin MJ, Kabir I, Dexter DJ, Rathore A, Panneton JM. Medical therapy in type B aortic intramural hematoma is associated with a high failure rate. *J Vasc Surg* 2020;71:1088-96.
- [297] Sueyoshi E, Imada T, Sakamoto I, Matsuoka Y, Hayashi K. Analysis of predictive factors for progression of type B aortic intramural hematoma with computed tomography. *J Vasc Surg* 2002;35:1179-83.
- [298] Evangelista A, Dominguez R, Sebastia C, Salas A, Permanyer-Miralda G, Avegliano G et al. Prognostic value of clinical and morphologic findings in short-term evolution of aortic intramural haematoma. Therapeutic implications. *Eur Heart J* 2004;25:81-7.
- [299] Choi SH, Choi SJ, Kim JH, Bae SJ, Lee JS, Song KS et al. Useful CT findings for predicting the progression of aortic intramural hematoma to overt aortic dissection. *J Comput Assist Tomogr* 2001;25:295-9.
- [300] Kitai T, Kaji S, Yamamuro A, Tani T, Kinoshita M, Ehara N et al. Impact of new development of ulcer-like projection on clinical outcomes in patients with type B aortic dissection with closed and thrombosed false lumen. *Circulation* 2010;122:S74-80.
- [301] Sadamatsu K, Takase S, Sagara S, Ohe K, Nishi JI, Tashiro H et al. Initial medical management in acute type A aortic dissection patients with a thrombosed false lumen in the ascending aorta combining intramural hematoma and retrograde dissection from the descending to the ascending aorta. *Eur Heart J Acute Cardiovasc Care* 2020;9:S13-20.
- [302] Wee I, Varughese RS, Syn N, Choong A. Non-operative management of type A acute aortic syndromes: a systematic review and meta-analysis. *Eur J Vasc Endovasc Surg* 2019;58:41-51.
- [303] Wang Y, Song S, Zhou C, Zhu W, Liu J, Shi Q et al. Thoracic endovascular aortic repair for retrograde type A intramural hematoma with intimal disruption in the descending aorta. *J Endovasc Ther* 2022;29:724-30.
- [304] Chen D, Luo M, Fang K, Shu C. Endovascular repair of acute zone 0 intramural hematoma with most proximal tear or ulcer-like projection in the descending aorta. *J Vasc Surg* 2022;75:1561-9.

- [305] Evangelista A, Czerny M, Nienaber C, Schepens M, Rousseau H, Cao P et al. Interdisciplinary expert consensus on management of type B intramural haematoma and penetrating aortic ulcer. *Eur J Cardiothorac Surg* 2015;47:209–17.
- [306] Li Z, Lu B, Chen Y, Hou Z, Chen B, Zhang Y et al. Acute type B aortic intramural hematoma: the added prognostic value of a follow-up CT. *Eur Radiol* 2019;29:6571–80.
- [307] Brown JA, Arnaoutakis GJ, Kilic A, Gleason TG, Aranda-Michel E, Sultan I. Medical and surgical management of acute type B aortic intramural hematoma. *J Card Surg* 2020;35:2324–30.
- [308] Chakos A, Twindyawardhani T, Evangelista A, Maldonado G, Piffaretti G, Yan TD et al. Endovascular versus medical management of type B intramural hematoma: a meta-analysis. *Ann Cardiothorac Surg* 2019;8:447–55.
- [309] Mesar T, Alie-Cusson FS, Lin MJ, Dexter DJ, Rathore A, Stokes GK et al. Impact of thoracic endovascular aortic repair timing on aortic remodeling in acute type B aortic intramural hematoma. *J Vasc Surg* 2022;75:464–72.e2.
- [310] Czerny M, Funovics M, Sodeck G, Dumfarth J, Schoder M, Juraszek A et al. Results after thoracic endovascular aortic repair in penetrating atherosclerotic ulcers. *Ann Thorac Surg* 2011;92:562–6.
- [311] Kreibich M, Kremer J, Vötsch A, Berger T, Farag M, Winkler A et al. Multicentre experience with the frozen elephant trunk technique to treat penetrating aortic ulcers involving the aortic arch. *Eur J Cardiothorac Surg* 2021;59:1238–44.
- [312] Oderich GS, Kärrkäinen JM, Reed NR, Tenorio ER, Sandri GA. Penetrating aortic ulcer and intramural hematoma. *Cardiovasc Intervent Radiol* 2019;42:321–34.
- [313] Ganaha F, Miller DC, Sugimoto K, Do YS, Minamiguchi H, Saito H et al. Prognosis of aortic intramural hematoma with and without penetrating atherosclerotic ulcer: a clinical and radiological analysis. *Circulation* 2002;106:342–8.
- [314] Bischoff MS, Geisbüsch P, Peters AS, Hyhlik-Dürr A, Böckler D. Penetrating aortic ulcer: defining risks and therapeutic strategies. *Herz* 2011;36:498–504.
- [315] Coady MA, Rizzo JA, Elefteriades JA. Pathologic variants of thoracic aortic dissections. Penetrating atherosclerotic ulcers and intramural hematomas. *Cardiol Clin* 1999;17:637–57.
- [316] Cooke JP, Kazmier FJ, Orszulak TA. The penetrating aortic ulcer: pathologic manifestations, diagnosis, and management. *Mayo Clin Proc* 1988;63:718–25.
- [317] Stanson AW, Kazmier FJ, Hollier LH, Edwards WD, Pairolero PC, Sheedy PF et al. Penetrating atherosclerotic ulcers of the thoracic aorta: natural history and clinicopathologic correlations. *Ann Vasc Surg* 1986;1:15–23.
- [318] Kupferthaler A, Hauck SR, Schwarz M, Kern M, Deinsberger J, Dachs TM et al. Endovascular repair of penetrating thoracic aortic ulcers using tubular stent grafts versus stent grafts with a proximal scallop. *J Endovasc Ther* 2023;15266028221149919.
- [319] Czerny M, Berger T, Kondov S, Siepe M, Saint Lebes B, Mokrane F et al. Results of endovascular aortic arch repair using the Relay Branch system. *Eur J Cardiothorac Surg* 2021;60:662–8.
- [320] Isernia G, Simonte G, Orrico M, Silingardi R, Gaggiano A, Covic T et al. Italian Najuta Registry study group. Preliminary results from an Italian National Registry on the outcomes of the Najuta fenestrated aortic arch endograft. *J Vasc Surg* 2023;77:1330–8.e2.
- [321] Neschis DG, Scalea TM, Flinn WR, Griffith BP. Blunt aortic injury. *N Engl J Med* 2008;359:1708–16.
- [322] Azizzadeh A, Keyhani K, Miller CC 3rd, Coogan SM, Safi HJ, Estrera AL. Blunt traumatic aortic injury: initial experience with endovascular repair. *J Vasc Surg* 2009;49:1403–8.
- [323] Lee WA, Matsumura JS, Mitchell RS, Farber MA, Greenberg RK, Azizzadeh A et al. Endovascular repair of traumatic thoracic aortic injury: clinical practice guidelines of the Society for Vascular Surgery. *J Vasc Surg* 2011;53:187–92.
- [324] Rimbau V, Böckler D, Brunkwall J, Cao P, Chiesa R, Coppi G et al. Editor's choice—Management of descending thoracic aorta diseases: clinical practice guidelines of the European Society for Vascular Surgery (ESVS). *Eur J Vasc Endovasc Surg* 2017;53:4–52.
- [325] Mandigers TJ, Bissacco D, Domanin M, D'Alessio I, Tolva VS, Piffaretti G et al. Cardiac and aortic modifications after endovascular repair for blunt thoracic aortic injury: a systematic review. *Eur J Vasc Endovasc Surg* 2022;64:176–87.
- [326] Mohapatra A, Liang NL, Makaroun MS, Schermerhorn ML, Farber A, Eslami MH. Improved outcomes of endovascular repair of thoracic aortic injuries at higher volume institutions. *J Vasc Surg* 2021;73:1314–9.
- [327] Rabin J, DuBose J, Sliker CW, O'Connor JV, Scalea TM, Griffith BP. Parameters for successful nonoperative management of traumatic aortic injury. *J Thorac Cardiovasc Surg* 2014;147:143–9.
- [328] Starnes BW, Lundgren RS, Gunn M, Quade S, Hatsukami TS, Tran NT et al. A new classification scheme for treating blunt aortic injury. *J Vasc Surg* 2012;55:47–54.
- [329] Harris DG, Rabin J, Starnes BW, Khoynzhad A, Conway RG, Taylor BS et al. Evolution of lesion-specific management of blunt thoracic aortic injury. *J Vasc Surg* 2016;64:500–5.
- [330] Gavant ML. Helical CT grading of traumatic aortic injuries. Impact on clinical guidelines for medical and surgical management. *Radiol Clin North Am* 1999;37:553–74.
- [331] DuBose JJ, Leake SS, Brenner M, Pasley J, O'Callaghan T, Luo-Owen X et al. Aortic Trauma Foundation. Contemporary management and outcomes of blunt thoracic aortic injury: a multicenter retrospective study. *J Trauma Acute Care Surg* 2015;78:360–9.
- [332] Fortuna GR Jr, Perlick A, DuBose JJ, Leake SS, Charlton-Ouw KM, Miller CC 3rd, et al. Injury grade is a predictor of aortic-related death among patients with blunt thoracic aortic injury. *J Vasc Surg* 2016;63:1225–31.
- [333] Kim JB, Spotnitz M, Lindsay ME, MacGillivray TE, Isselbacher EM, Sundt TM 3rd. Risk of aortic dissection in the moderately dilated ascending aorta. *J Am Coll Cardiol* 2016;68:1209–19.
- [334] Guo MH, Appoo JJ, Saczkowski R, Smith HN, Ouzounian M, Gregory AJ et al. Association of mortality and acute aortic events with ascending aortic aneurysm: a systematic review and meta-analysis. *JAMA Netw Open* 2018;1:e181281.
- [335] Masri A, Kalahasti V, Svensson LG, Roselli EE, Johnston D, Hammer D et al. Aortic cross-sectional area/height ratio and outcomes in patients with a trileaflet aortic valve and a dilated aorta. *Circulation* 2016;134:1724–37.
- [336] Kalogerakos PD, Zafar MA, Li Y, Mukherjee SK, Ziganshin BA, Rizzo JA et al. Root dilatation is more malignant than ascending aortic dilation. *J Am Heart Assoc* 2021;10:e020645.
- [337] Mansour AM, Peterss S, Zafar MA, Rizzo JA, Fang H, Charilaou P et al. Prevention of aortic dissection suggests a diameter shift to a lower aortic size threshold for intervention. *Cardiology* 2018;139:139–46.
- [338] Ganapathi AM, Ranney DN, Peterson MD, Lindsay ME, Patel HJ, Pyeritz RE et al. Location of aortic enlargement and risk of type A dissection at smaller diameters. *J Am Coll Cardiol* 2022;79:1890–7.
- [339] Borger MA, Fedak PWM, Stephens EH, Gleason TG, Girdauskas E, Ikonomidis JS et al. The American Association for Thoracic Surgery consensus guidelines on bicuspid aortic valve-related aortopathy: full online-only version. *J Thorac Cardiovasc Surg* 2018;156:e41–74.
- [340] Zafar MA, Li Y, Rizzo JA, Charilaou P, Saeyeldin A, Velasquez CA et al. Height alone, rather than body surface area, suffices for risk estimation in ascending aortic aneurysm. *J Thorac Cardiovasc Surg* 2018;155:1938–50.
- [341] Wojnarski CM, Svensson LG, Roselli EE, Idrees JJ, Lowry AM, Ehrlinger J et al. Aortic dissection in patients with bicuspid aortic valve-associated aneurysms. *Ann Thorac Surg* 2015;100:1666–73.
- [342] Bossone E, Eagle KA. Epidemiology and management of aortic disease: aortic aneurysms and acute aortic syndromes. *Nat Rev Cardiol* 2021;18:331–48.
- [343] Detaint D, Michelena HI, Nkomo VT, Vahanian A, Jondeau G, Sarano ME. Aortic dilatation patterns and rates in adults with bicuspid aortic valves: a comparative study with Marfan syndrome and degenerative aortopathy. *Heart* 2014;100:126–34.
- [344] Michelena HI, Khanna AD, Mahoney D, Margaryan E, Topolsky Y, Suri RM et al. Incidence of aortic complications in patients with bicuspid aortic valves. *JAMA* 2011;306:1104–12.
- [345] Rylski B, Blanke P, Beyersdorf F, Desai ND, Milewski RK, Siepe M et al. How does the ascending aorta geometry change when it dissects? *J Am Coll Cardiol* 2014;63:1311–9.
- [346] Vahanian A, Beyersdorf F, Pratz F, Milojevic M, Baldus S, Bauersachs J et al. ESC/EACTS Scientific Document Group. 2021 ESC/EACTS Guidelines for the management of valvular heart disease. *Eur J Cardiothorac Surg* 2021;60:727–800.
- [347] Williams JB, Peterson ED, Zhao Y, O'Brien SM, Andersen ND, Miller DC et al. Contemporary results for proximal aortic replacement in North America. *J Am Coll Cardiol* 2012;60:1156–62.
- [348] Sonsino A, Ellauzi H, Ziganshin BA, Zafar MA, Elefteriades JA. Rapid growth of thoracic aortic aneurysm: reality or myth? *J Thorac Cardiovasc Surg* 2022;S0022-5223(22)00731-0.

- [349] Czerny M, Rylski B, Della Corte A, Krüger T. Decision-making to perform elective surgery for patients with proximal thoracic aortic pathology: a European perspective. *J Thorac Cardiovasc Surg* 2022;163:2025–30.
- [350] Pape LA, Tsai TT, Isselbacher EM, Oh JK, O'Gara PT, Evangelista A et al. International Registry of Acute Aortic Dissection (IRAD) Investigators. Aortic diameter >or = 5.5 cm is not a good predictor of type A aortic dissection: observations from the International Registry of Acute Aortic Dissection (IRAD). *Circulation* 2007;116:1120–7.
- [351] Coady MA, Rizzo JA, Elefteriades JA. Developing surgical intervention criteria for thoracic aortic aneurysms. *Cardiol Clin* 1999;17:827–39.
- [352] Ziganshin BA, Zafar MA, Elefteriades JA. Descending threshold for ascending aortic aneurysmectomy: is it time for a "left-shift" in guidelines? *J Thorac Cardiovasc Surg* 2019;157:37–42.
- [353] Krüger T, Oikonomou A, Schibily D, Lescan M, Bregel K, Vöhringer L et al. Aortic elongation and the risk for dissection: the Tübingen Aortic Pathoanatomy (TAIPAN) project. *Eur J Cardiothorac Surg* 2017;51:1119–26.
- [354] Heuts S, Adriaans BP, Rylski B, Mihal C, Bekkers S, Olsthoorn JR et al. Evaluating the diagnostic accuracy of maximal aortic diameter, length and volume for prediction of aortic dissection. *Heart* 2020;106:892–7.
- [355] Elefteriades JA, Ziganshin BA, Zafar MA. Nonsize criteria for surgical intervention on the ascending thoracic aorta. *Aorta (Stamford)* 2023;11:71–86.
- [356] Hage A, Hage F, Dagenais F, Ouzounian M, Chung J, El-Hamamsy I et al. Canadian Thoracic Aortic Collaborative. Frozen elephant trunk for aortic arch reconstruction is associated with reduced mortality as compared to conventional techniques. *Semin Thorac Cardiovasc Surg* 2022;34:386–92.
- [357] Shrestha M, Kaufeld T, Beckmann E, Fleissner F, Umminger J, Abd Alhadi F et al. Total aortic arch replacement with a novel 4-branched frozen elephant trunk prosthesis: single-center results of the first 100 patients. *J Thorac Cardiovasc Surg* 2016;152:148–59.e1.
- [358] Tsagakis K, Pacini D, Grabenwöger M, Borger MA, Goebel N, Hemmer W et al. Results of frozen elephant trunk from the international E-vita Open registry. *Ann Cardiothorac Surg* 2020;9:178–88.
- [359] Teixido MT, Leonetti JP. Recurrent laryngeal nerve paralysis associated with thoracic aortic aneurysm. *Otolaryngol Head Neck Surg* 1990;102:140–4.
- [360] Isselbacher EM. Thoracic and abdominal aortic aneurysms. *Circulation* 2005;111:816–28.
- [361] Planer D, Elbaz-Greener G, Mangialardi N, Lindsay T, D'Onofrio A, Schelzig H et al. NEXUS arch: a multicenter study evaluating the initial experience with a novel aortic arch stent graft system. *Ann Surg* 2023;277:e460–6.
- [362] Wang H, Wagner M, Benrashid E, Keenan J, Wang A, Ranney D et al. Outcomes of reoperation after acute type A aortic dissection: implications for index repair strategy. *J Am Heart Assoc* 2017;6:e006376.
- [363] Bajona P, Quintana E, Schaff HV, Daly RC, Dearani JA, Greason KL et al. Aortic arch surgery after previous type A dissection repair: results up to 5 years. *Interact CardioVasc Thorac Surg* 2015;21:81–5.
- [364] Malvindi PG, van Putte BP, Sonker U, Heijmen RH, Schepens MA, Morshuis WJ. Reoperation after acute type A aortic dissection repair: a series of 104 patients. *Ann Thorac Surg* 2013;95:922–7.
- [365] Williams ML, de Boer M, Hwang B, Wilson B, Brookes J, McNamara N et al. Thoracic endovascular repair of chronic type B aortic dissection: a systematic review. *Ann Cardiothorac Surg* 2022;11:1–15.
- [366] Arafat A, Roselli EE, Idrees JJ, Feng K, Banaszak L, Eagleton M et al. Stent grafting acute aortic dissection: comparison of DeBakey extent IIIA versus IIIB. *Ann Thorac Surg* 2016;102:1473–81.
- [367] Fukuhara S, Khaja MS, Williams DM, Marko X, Yang B, Patel HJ et al. Aortic septotomy to optimize landing zones during thoracic endovascular aortic repair for chronic type B aortic dissection. *J Thorac Cardiovasc Surg* 2023;165:1776–86.e5.
- [368] de Beaufort HWL, Vos JA, Heijmen RH. Initial single-center experience with the knickerbocker technique during thoracic endovascular aortic repair to block retrograde false lumen flow in patients with type B aortic dissection. *J Endovasc Ther* 2022;15266028221134889.
- [369] Eleshra A, Kölbl T, Tsilimparis N, Panuccio G, Scheerbaum M, Debus ES et al. Candy-Plug Generation II for false lumen occlusion in chronic aortic dissection: feasibility and early results. *J Endovasc Ther* 2019;26:782–6.
- [370] Miletic KG, Kindzelski BA, Hodges KE, Beach J, Tong MZ, Bakaeen F et al. Impact of endovascular false lumen embolization on thoracic aortic remodeling in chronic dissection. *Ann Thorac Surg* 2021;111:495–501.
- [371] Kreibich M, Siepe M, Berger T, Kondov S, Morlock J, Pingphoh C et al. Downstream thoracic endovascular aortic repair following zone 2, 100-mm stent graft frozen elephant trunk implantation. *Interact CardioVasc Thorac Surg* 2022;34:1141–6.
- [372] Brownstein AJ, Ziganshin BA, Kuivaniemi H, Body SC, Bale AE, Elefteriades JA. Genes associated with thoracic aortic aneurysm and dissection: an update and clinical implications. *Aorta (Stamford)* 2017;5:11–20.
- [373] Milewicz DM, Regalado ES, Shendure J, Nickerson DA, Guo DC. Successes and challenges of using whole exome sequencing to identify novel genes underlying an inherited predisposition for thoracic aortic aneurysms and acute aortic dissections. *Trends Cardiovasc Med* 2014;24:53–60.
- [374] Milleron O, Arnoult F, Delorme G, Detaint D, Pellenc Q, Raffoul R et al. Pathogenic FBN1 genetic variation and aortic dissection in patients with Marfan syndrome. *J Am Coll Cardiol* 2020;75:843–53.
- [375] Martín C, Evangelista A, Serrano-Fiz S, Villar S, Ospina V, Martínez D et al. Aortic complications in Marfan syndrome: should we anticipate preventive aortic root surgery? *Ann Thorac Surg* 2020;109:1850–7.
- [376] Silverman DI, Gray J, Roman MJ, Bridges A, Burton K, Boxer M et al. Family history of severe cardiovascular disease in Marfan syndrome is associated with increased aortic diameter and decreased survival. *J Am Coll Cardiol* 1995;26:1062–7.
- [377] Finkbohner R, Johnston D, Crawford ES, Coselli J, Milewicz DM. Marfan syndrome. Long-term survival and complications after aortic aneurysm repair. *Circulation* 1995;91:728–33.
- [378] Gott VL, Greene PS, Alejo DE, Cameron DE, Naftel DC, Miller DC et al. Replacement of the aortic root in patients with Marfan's syndrome. *N Engl J Med* 1999;340:1307–13.
- [379] Silverman DI, Burton KJ, Gray J, Bosner MS, Kouchoukos NT, Roman MJ et al. Life expectancy in the Marfan syndrome. *Am J Cardiol* 1995;75:157–60.
- [380] Jondeau G, Detaint D, Tubach F, Arnoult F, Milleron O, Raoux F et al. Aortic event rate in the Marfan population: a cohort study. *Circulation* 2012;125:226–32.
- [381] Saeyeldin A, Zafar MA, Velasquez CA, Ip K, Gryaznov A, Brownstein AJ et al. Natural history of aortic root aneurysms in Marfan syndrome. *Ann Cardiothorac Surg* 2017;6:625–32.
- [382] Roman MJ, Rosen SE, Kramer-Fox R, Devereux RB. Prognostic significance of the pattern of aortic root dilation in the Marfan syndrome. *J Am Coll Cardiol* 1993;22:1470–6.
- [383] Schoenhoff FS, Langhammer B, Wustmann K, Reineke D, Kadner A, Carrel T. Decision-making in aortic root surgery in Marfan syndrome: bleeding, thromboembolism and risk of reintervention after valve-sparing or mechanical aortic root replacement. *Eur J Cardiothorac Surg* 2015;48:931–5.
- [384] den Hartog AW, Franken R, Zwinderman AH, Timmermans J, Scholte AJ, van den Berg MP et al. The risk for type B aortic dissection in Marfan syndrome. *J Am Coll Cardiol* 2015;65:246–54.
- [385] Schoenhoff FS, Yildiz M, Langhammer B, Jungi S, Wyss TR, Makaloski V et al. The fate of nonaortic arterial segments in Marfan patients. *J Thorac Cardiovasc Surg* 2019;157:2150–6.
- [386] Schoenhoff FS, Jungi S, Czerny M, Roost E, Reineke D, Matyas G et al. Acute aortic dissection determines the fate of initially untreated aortic segments in Marfan syndrome. *Circulation* 2013;127:1569–75.
- [387] Schoenhoff FS, Kadner A, Czerny M, Jungi S, Meszaros K, Schmidli J et al. Should aortic arch replacement be performed during initial surgery for aortic root aneurysm in patients with Marfan syndrome? *Eur J Cardiothorac Surg* 2013;44:346–51.
- [388] Loeyz BL, Schwarze U, Holm T, Callewaert BL, Thomas GH, Pannu H et al. Aneurysm syndromes caused by mutations in the TGF-beta receptor. *N Engl J Med* 2006;355:788–98.
- [389] Jondeau G, Ropers J, Regalado E, Braverman A, Evangelista A, Teixido G et al. Montalcino Aortic Consortium. International Registry of Patients Carrying TGFBR1 or TGFBR2 Mutations: results of the MAC (Montalcino Aortic Consortium). *Circ Cardiovasc Genet* 2016;9:548–58.
- [390] Tran-Fadulu V, Pannu H, Kim DH, Vick GW 3rd, Lonsford CM, Lafont AL et al. Analysis of multigenerational families with thoracic aortic aneurysms and dissections due to TGFBR1 or TGFBR2 mutations. *J Med Genet* 2009;46:607–13.
- [391] Hostetler EM, Regalado ES, Guo DC, Hanna N, Arnaud P, Muñoz-Mosquera L et al. SMAD3 pathogenic variants: risk for thoracic aortic

- disease and associated complications from the Montalcino Aortic Consortium. *J Med Genet* 2019;56:252–60.
- [392] van de Laar IM, Oldenburg RA, Pals G, Roos-Hesselink JW, de Graaf BM, Verhagen JM et al. Mutations in SMAD3 cause a syndromic form of aortic aneurysms and dissections with early-onset osteoarthritis. *Nat Genet* 2011;43:121–6.
- [393] Boileau C, Guo DC, Hanna N, Regalado ES, Detaint D, Gong L et al. National Heart, Lung, and Blood Institute (NHLBI) Go Exome Sequencing Project. TGF $\beta$ 2 mutations cause familial thoracic aortic aneurysms and dissections associated with mild systemic features of Marfan syndrome. *Nat Genet* 2012;44:916–21.
- [394] Lindsay ME, Schepers D, Bolar NA, Doyle JJ, Gallo E, Fert-Bober J et al. Loss-of-function mutations in TGF $\beta$ 2 cause a syndromic presentation of thoracic aortic aneurysm. *Nat Genet* 2012;44:922–7.
- [395] Bertoli-Avella AM, Gillis E, Morisaki H, Verhagen JMA, de Graaf BM, van de Beek G et al. Mutations in a TGF- $\beta$  ligand, TGF $\beta$ 3, cause syndromic aortic aneurysms and dissections. *J Am Coll Cardiol* 2015;65:1324–36.
- [396] Marsili L, Overwater E, Hanna N, Baujat G, Baars MJH, Boileau C et al. Phenotypic spectrum of TGF $\beta$ 3 disease-causing variants in a Dutch-French cohort and first report of a homozygous patient. *Clin Genet* 2020;97:723–30.
- [397] Aftab M, Cikach FS, Zhu Y, Idrees JJ, Rigelsky CM, Kalahasti V et al. Loews-Dietz syndrome: intermediate-term outcomes of medically and surgically managed patients. *J Thorac Cardiovasc Surg* 2019;157:439–50.e5.
- [398] Roselli EE, Idrees JJ, Lowry AM, Masabni K, Soltesz EG, Johnston DR et al. Beyond the aortic root: staged open and endovascular repair of arch and descending aorta in patients with connective tissue disorders. *Ann Thorac Surg* 2016;101:906–12.
- [399] Schoenhoff FS, Alejo DE, Black JH, Crawford TC, Dietz HC, Grimm JC et al. Management of the aortic arch in patients with Loews-Dietz syndrome. *J Thorac Cardiovasc Surg* 2020;160:1166–75.
- [400] Patel ND, Crawford T, Magruder JT, Alejo DE, Hibino N, Black J et al. Cardiovascular operations for Loews-Dietz syndrome: intermediate-term results. *J Thorac Cardiovasc Surg* 2017;153:406–12.
- [401] Egbe AC, Miranda WR, Bonnichsen CR, Jain CC, Crestanello JA, Francois C et al. Prevalence and risk of progressive aortic aneurysm and dissection in adults with conotruncal anomalies. *Eur Heart J Cardiovasc Imaging* 2022;23:1663–8.
- [402] Kuijpers JM, Koolbergen DR, Groenink M, Boekholdt SM, Meijboom FJ, Jongbloed MRM et al. Aortic dissection and prophylactic surgery in congenital heart disease. *Int J Cardiol* 2019;274:113–6.
- [403] Prendergast A, Ziganshin BA, Papanikolaou D, Zafar MA, Nicoli S, Mukherjee S et al. Phenotyping zebrafish mutant models to assess candidate genes associated with aortic aneurysm. *Genes (Basel)* 2022;13:123.
- [404] Maleszewski JJ. Inflammatory ascending aortic disease: perspectives from pathology. *J Thorac Cardiovasc Surg* 2015;149:5176–83.
- [405] Zafar MA, Chen JF, Wu J, Li Y, Papanikolaou D, Abdelbaky M et al. Yale Aortic Institute Natural History Investigators. Natural history of descending thoracic and thoracoabdominal aortic aneurysms. *J Thorac Cardiovasc Surg* 2021;161:498–511.e1.
- [406] Perez ZG, Zafar MA, Velasco JJ, Sonsino A, Ellauzi H, John C et al. Aortic size at the time of type A and type B dissections. *Ann Thorac Surg* 2023;116:262–8.
- [407] Coady MA, Rizzo JA, Hammond GL, Mandapati D, Darr U, Kopf GS et al. What is the appropriate size criterion for resection of thoracic aortic aneurysms? *J Thorac Cardiovasc Surg* 1997;113:476–91.
- [408] Coady MA, Rizzo JA, Hammond GL, Kopf GS, Elefteriades JA. Surgical intervention criteria for thoracic aortic aneurysms: a study of growth rates and complications. *Ann Thorac Surg* 1999;67:1922–53; discussion 1953–8.
- [409] Rylski B, Muñoz C, Beyersdorf F, Siepe M, Reser D, Carrel T et al. How does descending aorta geometry change when it dissects? *Eur J Cardiothorac Surg* 2018;53:815–21.
- [410] De Martino RR, Nolan BW, Goodney PP, Chang CK, Schanzer A, Cambria R et al. Vascular Study Group of Northern New England. Outcomes of symptomatic abdominal aortic aneurysm repair. *J Vasc Surg* 2010;52:5–12.e1.
- [411] Soden PA, Zettervall SL, Ultee KH, Darling JD, Buck DB, Hile CN et al. Outcomes for symptomatic abdominal aortic aneurysms in the American College of Surgeons National Surgical Quality Improvement Program. *J Vasc Surg* 2016;64:297–305.
- [412] Lederle FA, Wilson SE, Johnson GR, Reinke DB, Littooy FN, Acher CW et al. Aneurysm Detection and Management Veterans Affairs Cooperative Study Group. Immediate repair compared with surveillance of small abdominal aortic aneurysms. *N Engl J Med* 2002;346:1437–44.
- [413] Brown LC, Powell JT, Thompson SG, Epstein DM, Sculpher MJ, Greenhalgh RM. The UK EndoVascular Aneurysm Repair (EVAR) trials: randomised trials of EVAR versus standard therapy. *Health Technol Assess* 2012;16:1–218.
- [414] Cao P, De Rango P, Verzini F, Parlani G, Romano L, Cieri E; CAESAR Trial Group. Comparison of surveillance versus aortic endografting for small aneurysm repair (CAESAR): results from a randomised trial. *Eur J Vasc Endovasc Surg* 2011;41:13–25.
- [415] Ouriel K, Clair DG, Kent KC, Zarins CK; Positive Impact of Endovascular Options for treating Aneurysms Early (PIVOTAL) Investigators. Endovascular repair compared with surveillance for patients with small abdominal aortic aneurysms. *J Vasc Surg* 2010;51:1081–7.
- [416] Sweeting MJ, Thompson SG, Brown LC, Powell JT; RESCAN collaborators. Meta-analysis of individual patient data to examine factors affecting growth and rupture of small abdominal aortic aneurysms. *Br J Surg* 2012;99:655–65.
- [417] Lo RC, Lu B, Fokkema MT, Conrad M, Patel VI, Fillinger M et al. Vascular Study Group of New England. Relative importance of aneurysm diameter and body size for predicting abdominal aortic aneurysm rupture in men and women. *J Vasc Surg* 2014;59:1209–16.
- [418] Kent KC, Zwolak RM, Egorova NN, Riles TS, Manganaro A, Moskowitz AJ et al. Analysis of risk factors for abdominal aortic aneurysm in a cohort of more than 3 million individuals. *J Vasc Surg* 2010;52:539–48.
- [419] Ulug P, Powell JT, Martinez MA, Ballard DJ, Filardo G. Surgery for small asymptomatic abdominal aortic aneurysms. *Cochrane Database Syst Rev* 2020;7:CD001835.
- [420] Grootenboer N, van Sambeek MR, Arends LR, Hendriks JM, Hunink MG, Bosch JL. Systematic review and meta-analysis of sex differences in outcome after intervention for abdominal aortic aneurysm. *Br J Surg* 2010;97:1169–79.
- [421] Lederle FA, Walker JM, Reinke DB. Selective screening for abdominal aortic aneurysms with physical examination and ultrasound. *Arch Intern Med* 1988;148:1753–6.
- [422] Ulug P, Powell JT, Sweeting MJ, Bown MJ, Thompson SG; SWAN Collaborative Group. Meta-analysis of the current prevalence of screen-detected abdominal aortic aneurysm in women. *Br J Surg* 2016;103:1097–104.
- [423] Brown LC, Powell JT. Risk factors for aneurysm rupture in patients kept under ultrasound surveillance. *UK Small Aneurysm Trial Participants. Ann Surg* 1999;230:289–96.
- [424] Bown MJ, Sweeting MJ, Brown LC, Powell JT, Thompson SG; RESCAN Collaborators. Surveillance intervals for small abdominal aortic aneurysms: a meta-analysis. *JAMA* 2013;309:806–13.
- [425] Olson SL, Wijesinha MA, Panthofer AM, Blackwelder WC, Upchurch GR Jr, Terrin ML et al. Evaluating growth patterns of abdominal aortic aneurysm diameter with serial computed tomography surveillance. *JAMA Surg* 2021;156:363–70.
- [426] Karthaus EG, Tong TML, Vahi A, Hamming JF; Dutch Society of Vascular Surgery, the Steering Committee of the Dutch Surgical Aneurysm Audit and the Dutch Institute for Clinical Auditing. Saccular abdominal aortic aneurysms: patient characteristics, clinical presentation, treatment, and outcomes in the Netherlands. *Ann Surg* 2019;270:852–8.
- [427] Expert Panel on Detection, Evaluation, and Treatment of High Blood Cholesterol in Adults. Executive summary of the third report of the National Cholesterol Education Program (NCEP) expert panel on detection, evaluation, and treatment of high blood cholesterol in adults (adult treatment panel III). *JAMA* 2001;285:2486–97.
- [428] Kondov S, Rylski B, Kari FA, Wobser R, Leschka S, Siepe M et al. Descendo-bifemoral bypass grafting and renal artery revascularization to treat complex obliterative arteriopathy. *Interact CardioVasc Thorac Surg* 2017;24:655–8.
- [429] Diehm C, Schuster A, Allenberg JR, Darius H, Haberb R, Lange S et al. High prevalence of peripheral arterial disease and co-morbidity in 6880 primary care patients: cross-sectional study. *Atherosclerosis* 2004;172:95–105.
- [430] Fujimura N, Takahara M, Obara H, Ichihashi S, George RK, Igari K et al. Comparison of aortobifemoral bypass and endovascular treatment for chronic infrarenal abdominal aortic occlusion from the CHAOS (CHronic Abdominal Aortic Occlusion, ASian Multicenter) Registry. *J Endovasc Ther* 2022;30:828–37.
- [431] Grottemeyer D, Pourhassan S, Rehbein H, Voiculescu A, Reinecke P, Sandmayer W. The coral reef aorta—a single centre experience in 70 patients. *Int J Angiol* 2007;16:98–105.

- [432] Helder MRK, Schaff HV, Day CN, Pochettino A, Bagameri G, Greason KL et al. Regional and temporal trends in the outcomes of repairs for acute type A aortic dissections. *Ann Thorac Surg* 2020;109:26–33.
- [433] Puiu PC, Pingpoh C, Beyersdorf F, Czerny M, Keyl C, Kreibich M et al. Direct versus side graft cannulation from the right axillary artery in thoracic aortic surgery. *Ann Thorac Surg* 2021;112:1433–40.
- [434] Urbanski PP, Lenos A, Lindemann Y, Weigang E, Zacher M, Diegeler A. Carotid artery cannulation in aortic surgery. *J Thorac Cardiovasc Surg* 2006;132:1398–403.
- [435] Kreibich M, Chen Z, Rylski B, Bavaria JE, Brown CR, Branchetti E et al. Outcome after aortic, axillary, or femoral cannulation for acute type A aortic dissection. *J Thorac Cardiovasc Surg* 2019;158:27–34.e9.
- [436] Coselli JS, LeMaire SA, Köksoy C, Schmittling ZC, Curling PE. Cerebrospinal fluid drainage reduces paraplegia after thoracoabdominal aortic aneurysm repair: results of a randomized clinical trial. *J Vasc Surg* 2002;35:631–9.
- [437] Khan NR, Smalley Z, Nesvick CL, Lee SL, Michael LM 2nd. The use of lumbar drains in preventing spinal cord injury following thoracoabdominal aortic aneurysm repair: an updated systematic review and meta-analysis. *J Neurosurg Spine* 2016;25:383–93.
- [438] Malvindi PG, Alfonsi J, Berretta P, Cefarelli M, Gatta E, Di Eusanio M. Normothermic frozen retractor trunk: our experience and literature review. *Cardiovasc Diagn Ther* 2022;12:262–71.
- [439] Luehr M, Bachet J, Mohr FW, Etz CD. Modern temperature management in aortic arch surgery: the dilemma of moderate hypothermia. *Eur J Cardiothorac Surg* 2014;45:27–39.
- [440] Touati GD, Marticho P, Farag M, Carmi D, Szymanski C, Barry M et al. Totally normothermic aortic arch replacement without circulatory arrest. *Eur J Cardiothorac Surg* 2007;32:263–8.
- [441] Cao L, Guo X, Jia Y, Yang L, Wang H, Yuan S. Effect of deep hypothermic circulatory arrest versus moderate hypothermic circulatory arrest in aortic arch surgery on postoperative renal function: a systematic review and meta-analysis. *J Am Heart Assoc* 2020;9:e017939.
- [442] Lemaire SA, Jones MM, Conklin LD, Carter SA, Criddell MD, Wang XL et al. Randomized comparison of cold blood and cold crystalloid renal perfusion for renal protection during thoracoabdominal aortic aneurysm repair. *J Vasc Surg* 2009;49:11–9.
- [443] Köksoy C, LeMaire SA, Curling PE, Raskin SA, Schmittling ZC, Conklin LD et al. Renal perfusion during thoracoabdominal aortic operations: cold crystalloid is superior to normothermic blood. *Ann Thorac Surg* 2002;73:730–8.
- [444] Kahlberg A, Tshomba Y, Baccellieri D, Bertoglio L, Rinaldi E, Ardita V et al. CURITIBA Investigators. Renal perfusion with histidine-tryptophan-ketoglutarate compared with Ringer's solution in patients undergoing thoracoabdominal aortic open repair. *J Thorac Cardiovasc Surg* 2023;165:569–79.e5.
- [445] Tshomba Y, Kahlberg A, Melissano G, Coppi G, Marone E, Ferrari D et al. Comparison of renal perfusion solutions during thoracoabdominal aortic aneurysm repair. *J Vasc Surg* 2014;59:623–33.
- [446] Preventza O, Coselli JS, Price MD, Simpson KH, Yafei O, de la Cruz KI et al. Elective primary aortic root replacement with and without hemiarch repair in patients with no previous cardiac surgery. *J Thorac Cardiovasc Surg* 2017;153:1402–8.
- [447] Malaisrie SC, Duncan BF, Mehta CK, Badiwala MV, Rinewalt D, Kruse J et al. The addition of hemiarch replacement to aortic root surgery does not affect safety. *J Thorac Cardiovasc Surg* 2015;150:118–24.e2.
- [448] Rylski B, Milewski RK, Bavaria JE, Vallabhajosyula P, Moser W, Szeto WY et al. Long-term results of aggressive hemiarch replacement in 534 patients with type A aortic dissection. *J Thorac Cardiovasc Surg* 2014;148:2981–5.
- [449] Payabyab EC, Hemli JM, Mattia A, Kremers A, Vatsia SK, Scheinerman SJ et al. The use of innominate artery cannulation for antegrade cerebral perfusion in aortic dissection. *J Cardiothorac Surg* 2020;15:205.
- [450] Mohebbali J, Carvalho S, Lancaster RT, Ergul EA, Conrad MF, Clouse WD et al. Use of extracorporeal bypass is associated with improved outcomes in open thoracic and thoracoabdominal aortic aneurysm repair. *J Vasc Surg* 2018;68:941–7.
- [451] Wahlgren CM, Blohmé L, Günther A, Nilsson L, Olsson C. Outcomes of left heart bypass versus circulatory arrest in elective open surgical descending and thoraco-abdominal aortic repair. *Eur J Vasc Endovasc Surg* 2017;53:672–8.
- [452] Griep RB, Stinson EB, Hollingsworth JF, Buehler D. Prosthetic replacement of the aortic arch. *J Thorac Cardiovasc Surg* 1975;70:1051–63.
- [453] Kazui T, Kimura N, Komatsu S. Surgical treatment of aortic arch aneurysms using selective cerebral perfusion. Experience with 100 patients. *Eur J Cardiothorac Surg* 1995;9:491–5.
- [454] Bachet J, Guilmet D, Goudot B, Termignon JL, Teodori G, Dreyfus G et al. Cold cerebroplegia. A new technique of cerebral protection during operations on the transverse aortic arch. *J Thorac Cardiovasc Surg* 1991;102:85–94.
- [455] Yan TD, Bannon PG, Bavaria J, Coselli JS, Elefteriades JA, Griep RB et al. Consensus on hypothermia in aortic arch surgery. *Ann Cardiothorac Surg* 2013;2:163–8.
- [456] Abjigitova D, Notenboom ML, Veen KM, van Tussenbroek G, Bekkers JA, Mokhles MM et al. Optimal temperature management in aortic arch surgery: a systematic review and network meta-analysis. *J Card Surg* 2022;37:5379–87.
- [457] Preventza O, Coselli JS, Akvan S, Kashyap SA, Garcia A, Simpson KH et al. The impact of temperature in aortic arch surgery patients receiving antegrade cerebral perfusion for >30 minutes: how relevant is it really? *J Thorac Cardiovasc Surg* 2017;153:767–76.
- [458] Griep RB, Di Luozzo G. Hypothermia for aortic surgery. *J Thorac Cardiovasc Surg* 2013;145:S56–8.
- [459] Manoly I, Uzzaman M, Karangelis D, Kuduvali M, Georgakarakos E, Quarto C et al. Neuroprotective strategies with circulatory arrest in open aortic surgery—a meta-analysis. *Asian Cardiovasc Thorac Ann* 2022;30:635–44.
- [460] Vallabhajosyula P, Jassar AS, Menon RS, Komlo C, Gutsche J, Desai ND et al. Moderate versus deep hypothermic circulatory arrest for elective aortic transverse hemiarch reconstruction. *Ann Thorac Surg* 2015;99:1511–7.
- [461] Pacini D, Pantaleo A, Di Marco L, Leone A, Barberio G, Murana G et al. Visceral organ protection in aortic arch surgery: safety of moderate hypothermia. *Eur J Cardiothorac Surg* 2014;46:438–43.
- [462] Sun X, Yang H, Li X, Wang Y, Zhang C, Song Z et al. Randomized controlled trial of moderate hypothermia versus deep hypothermia anesthesia on brain injury during Stanford A aortic dissection surgery. *Heart Vessels* 2018;33:66–71.
- [463] Wu Y, Xiao L, Yang T, Wang L, Chen X. Aortic arch reconstruction: deep and moderate hypothermic circulatory arrest with selective antegrade cerebral perfusion. *Perfusion* 2017;32:389–93.
- [464] Tian DH, Wan B, Bannon PG, Misfeld M, LeMaire SA, Kazui T et al. A meta-analysis of deep hypothermic circulatory arrest versus moderate hypothermic circulatory arrest with selective antegrade cerebral perfusion. *Ann Cardiothorac Surg* 2013;2:148–58.
- [465] Zierer A, Aybek T, Risteski P, Dogan S, Wimmer-Greinecker G, Moritz A. Moderate hypothermia (30 degrees C) for surgery of acute type A aortic dissection. *Thorac Cardiovasc Surg* 2005;53:74–9.
- [466] Seese L, Chen EP, Badhwar V, Thibault D, Habib RH, Jacobs JP et al. Optimal circulatory arrest temperature for aortic hemiarch replacement with antegrade brain perfusion. *J Thorac Cardiovasc Surg* 2023;165:1759–70.e3.
- [467] Martens A, Koigeldiyev N, Beckmann E, Fleissner F, Kaufeld T, Krueger H et al. Do not leave the heart arrested. Non-cardioplegic continuous myocardial perfusion during complex aortic arch repair improves cardiac outcome. *Eur J Cardiothorac Surg* 2016;49:141–8.
- [468] Jakob H, Dohle D, Benedik J, Jánosi RA, Schlosser T, Wendt D et al. Long-term experience with the E-vita Open hybrid graft in complex thoracic aortic disease. *Eur J Cardiothorac Surg* 2017;51:329–38.
- [469] Leone A, Beckmann E, Martens A, Di Marco L, Pantaleo A, Reggiani LB et al. Total aortic arch replacement with frozen elephant trunk technique: results from two European institutes. *J Thorac Cardiovasc Surg* 2020;159:1201–11.
- [470] Berger T, Kreibich M, Rylski B, Morlock J, Kondov S, Scheumann J et al. Evaluation of myocardial injury, the need for vasopressors and inotropic support in beating-heart aortic arch surgery. *J Cardiovasc Surg (Torino)* 2020;61:505–11.
- [471] Murzi M, Miceli A, Di Stefano G, Cerillo AG, Kallushi E, Farneti P et al. Enhancing quality control and performance monitoring in thoracic aortic surgery: a 10-year single institutional experience. *Eur J Cardiothorac Surg* 2015;47:608–15.
- [472] Ad N, Holmes SD, Massimiano PS, Rongione AJ, Fornaresio LM, Fitzgerald D. The use of del Nido cardioplegia in adult cardiac surgery: a prospective randomized trial. *J Thorac Cardiovasc Surg* 2018;155:1011–8.
- [473] Pochettino A, Brinkman WT, Moeller P, Szeto WY, Moser W, Cornelius K et al. Antegrade thoracic stent grafting during repair of acute DeBakey

- I dissection prevents development of thoracoabdominal aortic aneurysms. *Ann Thorac Surg* 2009;88:482-9; discussion 489-90.
- [474] Comentale G, Pilato E. Safety of del Nido cardioplegia during frozen elephant trunk procedure: a case report of first experience in complex aortic surgery. *Perfusion* 2023;2676591231157202.
- [475] D'Angelo AM, Nemeth S, Wang C, Kossar AP, Takeda K, Takayama H et al. Re-dosing of del Nido cardioplegia in adult cardiac surgery requiring prolonged aortic cross-clamp. *Interact CardioVasc Thorac Surg* 2022;34:556-63.
- [476] Chen H, Wang L, Wan L, Xiao L, Chen X. Use of del Nido cardioplegia in acute aortic dissection surgery. *Perfusion* 2021;36:233-8.
- [477] Duan L, Hu GH, Wang E, Zhang CL, Huang LJ, Duan YY. Del Nido versus HTK cardioplegia for myocardial protection during adult complex valve surgery: a retrospective study. *BMC Cardiovasc Disord* 2021;21:604.
- [478] Lenoir M, Bouhout I, Jelassi A, Cartier R, Poirier N, El-Hamamsy I et al. Del Nido cardioplegia versus blood cardioplegia in adult aortic root surgery. *J Thorac Cardiovasc Surg* 2021;162:514-22.e2.
- [479] Chung MM, Erwin WC, Ning Y, Zhao Y, Chan C, D'Angelo A et al. A novel dosing strategy of del Nido cardioplegia in aortic surgery. *JTCVS Open* 2022;10:39-61.
- [480] Eris C, Engin M, Erdolu B, Kagan As A. Comparison of del Nido Cardioplegia vs. blood cardioplegia in adult aortic surgery: is the single-dose cardioplegia technique really advantageous? *Asian J Surg* 2022;45:1122-7.
- [481] Willekes H, Parker J, Fanning J, Leung S, Spurlock D, Murphy E et al. Del nido cardioplegia in ascending aortic surgery. *Semin Thorac Cardiovasc Surg* 2023;35:33-41.
- [482] Janssen C, Kellermann S, Münch F, Purbojo A, Cesnjevar RA, Ruffer A. Myocardial protection during aortic arch repair in a piglet model: beating heart technique compared with crystalloid cardioplegia. *Ann Thorac Surg* 2015;100:1758-66.
- [483] Ou CY, Hu HW, Lin TW, Roan JN, Hu YN, Wang YC et al. Continuous myocardial perfusion during distal anastomosis of acute type A aortic dissection. *Thorac Cardiovasc Surg* 2023. doi: 10.1055/s-0043-1761218.
- [484] Zhang MQ, Liao YQ, Yu H, Li XF, Shi W, Jing WW et al. Effect of ventilation strategy during cardiopulmonary bypass on postoperative pulmonary complications after cardiac surgery: a randomized clinical trial. *J Cardiothorac Surg* 2021;16:319.
- [485] Hemmes SN, Serpa Neto A, Schultz MJ. Intraoperative ventilatory strategies to prevent postoperative pulmonary complications: a meta-analysis. *Curr Opin Anaesthesiol* 2013;26:126-33.
- [486] Bignami E, Guarnieri M, Saggiotti F, Belletti A, Trumello C, Giambuzzi I et al. Mechanical ventilation during cardiopulmonary bypass. *J Cardiothorac Vasc Anesth* 2016;30:1668-75.
- [487] García-Delgado M, Navarrete-Sánchez I, Colmenero M. Preventing and managing perioperative pulmonary complications following cardiac surgery. *Curr Opin Anaesthesiol* 2014;27:146-52.
- [488] Costa Leme A, Hajjar LA, Volpe MS, Fukushima JT, De Santis Santiago RR, Osawa EA et al. Effect of intensive vs moderate alveolar recruitment strategies added to lung-protective ventilation on postoperative pulmonary complications: a randomized clinical trial. *JAMA* 2017;317:1422-32.
- [489] Smit B, Smulders YM, de Waard MC, Boer C, Vonk AB, Veerhoek D et al. Moderate hyperoxic versus near-physiological oxygen targets during and after coronary artery bypass surgery: a randomised controlled trial. *Crit Care* 2016;20:55.
- [490] Schreiber JU, Lancé MD, de Korte M, Artmann T, Aleksic I, Kranke P. The effect of different lung-protective strategies in patients during cardiopulmonary bypass: a meta-analysis and semiquantitative review of randomized trials. *J Cardiothorac Vasc Anesth* 2012;26:448-54.
- [491] Wiedemann D, Kocher A, Dorfmeister M, Vadehra A, Mahr S, Laufer G et al. Effect of cerebral protection strategy on outcome of patients with Stanford type A aortic dissection. *J Thorac Cardiovasc Surg* 2013;146:647-55.e1.
- [492] Samanidis G, Kanakis M, Khoury M, Balanika M, Antoniou T, Giannopoulos N et al. Antegrade and retrograde cerebral perfusion during acute type A aortic dissection repair in 290 patients. *Heart Lung Circ* 2021;30:1075-83.
- [493] Ganapathi AM, Hanna JM, Schechter MA, Englum BR, Castleberry AW, Gaca JG et al. Antegrade versus retrograde cerebral perfusion for hemi-arch replacement with deep hypothermic circulatory arrest: does it matter? A propensity-matched analysis. *J Thorac Cardiovasc Surg* 2014;148:2896-902.
- [494] Gergen AK, Kemp C, Ghincea CV, Feng Z, Cleveland JC Jr, Pal JD et al. Challenging paradigm limits of retrograde cerebral perfusion during lower body circulatory arrest. *J Surg Res* 2023;283:699-704.
- [495] Takagi H, Mitta S, Ando T. A contemporary meta-analysis of antegrade versus retrograde cerebral perfusion for thoracic aortic surgery. *Thorac Cardiovasc Surg* 2019;67:351-62.
- [496] Preventza O, Simpson KH, Cooley DA, Cornwell L, Bakaeen FG, Omer S et al. Unilateral versus bilateral cerebral perfusion for acute type A aortic dissection. *Ann Thorac Surg* 2015;99:80-7.
- [497] Tong G, Zhang B, Zhou X, Tao Y, Yan T, Wang X et al. Bilateral versus unilateral antegrade cerebral perfusion in total arch replacement for type A aortic dissection. *J Thorac Cardiovasc Surg* 2017;154:767-75.
- [498] Liu Z, Wang C, Zhang X, Wu S, Fang C, Pang X. Effect of different types of cerebral perfusion for acute type A aortic dissection undergoing aortic arch procedure, unilateral versus bilateral. *BMC Surg* 2020;20:286.
- [499] Angleitner P, Stelzmueller ME, Mahr S, Kaider A, Laufer G, Ehrlich M. Bilateral or unilateral antegrade cerebral perfusion during surgery for acute type A dissection. *J Thorac Cardiovasc Surg* 2020;159:2159-67.e2.
- [500] Etz CD, Weigang E, Hartert M, Lonn L, Mestres CA, Di Bartolomeo R et al. Contemporary spinal cord protection during thoracic and thoracoabdominal aortic surgery and endovascular aortic repair: a position paper of the vascular domain of the European Association for Cardio-Thoracic Surgery. *Eur J Cardiothorac Surg* 2015;47:943-57.
- [501] de Haan P, Kalkman CJ, Jacobs MJ. Spinal cord monitoring with myogenic motor evoked potentials: early detection of spinal cord ischaemia as an integral part of spinal cord protective strategies during thoracoabdominal aneurysm surgery. *Semin Thorac Cardiovasc Surg* 1998;10:19-24.
- [502] Etz CD, Halstead JC, Spielvogel D, Shahani R, Lazala R, Homann TM et al. Thoracic and thoracoabdominal aneurysm repair: is reimplantation of spinal cord arteries a waste of time? *Ann Thorac Surg* 2006;82:1670-7.
- [503] Maier S, Shcherbakova M, Beyersdorf F, Benk C, Kari FA, Siepe M et al. Benefits and risks of prophylactic cerebrospinal fluid catheter and evoked potential monitoring in symptomatic spinal cord ischemia low-risk thoracic endovascular aortic repair. *Thorac Cardiovasc Surg* 2019;67:379-84.
- [504] Khachatryan Z, Haunschild J, von Aspern K, Borger MA, Etz CD. Ischemic spinal cord injury-experimental evidence and evolution of protective measures. *Ann Thorac Surg* 2022;113:1692-702.
- [505] Haunschild J, von Aspern K, Herajärvi J, Dietze Z, Naumann J, Ossmann S et al. Impact of distal aortic perfusion on 'segmental steal' depleting spinal cord blood flow-a quantitative experimental approach. *Eur J Cardiothorac Surg* 2022;62:ezac213.
- [506] Maurel B, Delclaux N, Sobocinski J, Hertault A, Martin-Gonzalez T, Moussa M et al. The impact of early pelvic and lower limb reperfusion and attentive peri-operative management on the incidence of spinal cord ischemia during thoracoabdominal aortic aneurysm endovascular repair. *Eur J Vasc Endovasc Surg* 2015;49:248-54.
- [507] Etz CD, Zoli S, Mueller CS, Bodian CA, Di Luozzo G, Lazala R et al. Staged repair significantly reduces paraplegia rate after extensive thoracoabdominal aortic aneurysm repair. *J Thorac Cardiovasc Surg* 2010;139:1464-72.
- [508] Zoli S, Etz CD, Roder F, Brenner RM, Bodian CA, Kleinman G et al. Experimental two-stage simulated repair of extensive thoracoabdominal aneurysms reduces paraplegia risk. *Ann Thorac Surg* 2010;90:722-9.
- [509] Etz CD, Debus ES, Mohr FW, Kölbel T. First-in-man endovascular pre-conditioning of the paraspinous collateral network by segmental artery coil embolization to prevent ischemic spinal cord injury. *J Thorac Cardiovasc Surg* 2015;149:1074-9.
- [510] Branzan D, Etz CD, Moche M, Von Aspern K, Staab H, Fuchs J et al. Ischaemic preconditioning of the spinal cord to prevent spinal cord ischaemia during endovascular repair of thoracoabdominal aortic aneurysm: first clinical experience. *EuroIntervention* 2018;14:828-35.
- [511] Etz CD, Luehr M, Kari FA, Bodian CA, Smego D, Plestis KA et al. Paraplegia after extensive thoracic and thoracoabdominal aortic aneurysm repair: does critical spinal cord ischemia occur postoperatively? *J Thorac Cardiovasc Surg* 2008;135:324-30.
- [512] Etz CD, von Aspern K, Gudehus S, Luehr M, Girschbach FF, Ender J et al. Near-infrared spectroscopy monitoring of the collateral network prior to, during, and after thoracoabdominal aortic repair: a pilot study. *Eur J Vasc Endovasc Surg* 2013;46:651-6.

- [513] Etz CD, Luehr M, Kari FA, Lin HM, Kleinman G, Zoli S et al. Selective cerebral perfusion at 28 degrees C—is the spinal cord safe? *Eur J Cardiothorac Surg* 2009;36:946–55.
- [514] Khaladj N, Peterss S, Pichlmaier M, Shrestha M, von Wasielewski R, Hoy L et al. The impact of deep and moderate body temperatures on end-organ function during hypothermic circulatory arrest. *Eur J Cardiothorac Surg* 2011;40:1492–9.
- [515] Liang S, Liu Y, Zhang B, Dun Y, Guo H, Qian X et al. Postoperative hepatic dysfunction after frozen elephant trunk for type A aortic dissection. *Front Cardiovasc Med* 2021;8:739606.
- [516] Preventza O, Garcia A, Kashyap SA, Akvan S, Cooley DA, Simpson K et al. Moderate hypothermia  $\geq 24$  and  $\leq 28^\circ\text{C}$  with hypothermic circulatory arrest for proximal aortic operations in patients with previous cardiac surgery. *Eur J Cardiothorac Surg* 2016;50:949–54.
- [517] Miyamoto S, Takahashi S, Okahara S, Takahashi H, Katayama K, Watanabe M et al. Abdominal organ protection strategy for aortic arch aneurysm surgery. *Perfusion* 2018;33:512–9.
- [518] Haldenwang PL, Wahlers T, Himmels A, Wippermann J, Zeriuoh M, Kröner A et al. Evaluation of risk factors for transient neurological dysfunction and adverse outcome after repair of acute type A aortic dissection in 122 consecutive patients. *Eur J Cardiothorac Surg* 2012;42:e115–20.
- [519] Haverich A, Hagl C. Organ protection during hypothermic circulatory arrest. *J Thorac Cardiovasc Surg* 2003;125:460–2.
- [520] Kazui T, Washiyama N, Muhammad BA, Terada H, Yamashita K, Takinami M. Improved results of atherosclerotic arch aneurysm operations with a refined technique. *J Thorac Cardiovasc Surg* 2001;121:491–9.
- [521] Numata S, Tsutsumi Y, Monta O, Yamazaki S, Seo H, Yoshida S et al. Acute type A aortic dissection repair with mild-to-moderate hypothermic circulatory arrest and selective cerebral perfusion. *J Cardiovasc Surg (Torino)* 2015;56:525–30.
- [522] Svensson LG. Antegrade perfusion during suspended animation? *J Thorac Cardiovasc Surg* 2002;124:1068–70.
- [523] Allen BS, Veluz JS, Buckberg GD, Aeberhard E, Ignarro LJ. Deep hypothermic circulatory arrest and global reperfusion injury: avoidance by making a pump prime reperfusate—a new concept. *J Thorac Cardiovasc Surg* 2003;125:625–32.
- [524] Aftab M, Coselli JS. Renal and visceral protection in thoracoabdominal aortic surgery. *J Thorac Cardiovasc Surg* 2014;148:2963–6.
- [525] Wu D, Coselli JS, Johnson ML, LeMaire SA. Hepatopancreaticobiliary values after thoracoabdominal aneurysm repair. *Aorta (Stamford)* 2014;2:135–42.
- [526] Chiesa R, Melissano G, Civilini E, de Moura ML, Carozzo A, Zangrillo A. Ten years experience of thoracic and thoracoabdominal aortic aneurysm surgical repair: lessons learned. *Ann Vasc Surg* 2004;18:514–20.
- [527] Corvera J, Copeland H, Blitzer D, Hicks A, Manghelli J, Hess P et al. Open repair of chronic thoracic and thoracoabdominal aortic dissection using deep hypothermia and circulatory arrest. *J Thorac Cardiovasc Surg* 2017;154:389–95.
- [528] Coselli JS, LeMaire SA, Preventza O, de la Cruz KI, Cooley DA, Price MD et al. Outcomes of 3309 thoracoabdominal aortic aneurysm repairs. *J Thorac Cardiovasc Surg* 2016;151:1323–37.
- [529] LeMaire SA, Jamison AL, Carter SA, Wen S, Alankar S, Coselli JS. Deployment of balloon expandable stents during open repair of thoracoabdominal aortic aneurysms: a new strategy for managing renal and mesenteric artery lesions. *Eur J Cardiothorac Surg* 2004;26:599–607.
- [530] Moulakakis KG, Karaolani G, Antonopoulos CN, Kakisis J, Klonaris C, Preventza O et al. Open repair of thoracoabdominal aortic aneurysms in experienced centers. *J Vasc Surg* 2018;68:634–45.e12.
- [531] Safi HJ, Miller CC 3rd, Yawn DH, Iliopoulos DC, Subramaniam M, Harlin S et al. Impact of distal aortic and visceral perfusion on liver function during thoracoabdominal and descending thoracic aortic repair. *J Vasc Surg* 1998;27:145–52.
- [532] Green SY, Safi HJ, Coselli JS. A history of open thoracoabdominal aortic aneurysm repair: perspective from Houston. *J Cardiovasc Surg (Torino)* 2011;62:191–202.
- [533] Biancari F, Pettinari M, Mariscalco G, Mustonen C, Nappi F, Buech J et al. Outcome after surgery for iatrogenic acute type A aortic dissection. *J Clin Med* 2022;11:6729.
- [534] Estrera AL, Sandhu HK, Charlton-Ouw KM, Afifi RO, Azizzadeh A, Miller CC 3rd, et al. A quarter century of organ protection in open thoracoabdominal repair. *Ann Surg* 2015;262:660–8.
- [535] Brown JA, Serna-Gallegos D, Navid F, Thoma FW, Zhu J, Kumar R et al. The long-term impact of acute renal failure after aortic arch replacement for acute type A aortic dissection. *J Card Surg* 2022;37:2378–85.
- [536] Chen YL, Li HK, Wang L, Chen JW, Ma X. No safe renal warm ischemia time—The molecular network characteristics and pathological features of mild to severe ischemia reperfusion kidney injury. *Front Mol Biosci* 2022;9:1006917.
- [537] Belzer FO, Southard JH. Principles of solid-organ preservation by cold storage. *Transplantation* 1988;45:673–6.
- [538] Khullar V, Schaff HV, Dearani JA, Daly RC, Greason KL, Joyce LD et al. Open surgical repair remains the gold standard for treating aortic arch pathology. *Ann Thorac Surg* 2017;103:1413–20.
- [539] Chang Y, Guo H, Yu C, Sun X, Yang K, Qian X. Visceral protection in total arch replacement for aortic dissection: effect of lower body hypothermia. *J Card Surg* 2022;37:4841–9.
- [540] Böttcher W, Weixler V, Redlin M, Murin P, Dehmel F, Schmitt K et al. Acute kidney injury after neonatal aortic arch surgery: deep hypothermic circulatory arrest versus moderate hypothermia with distal aortic perfusion. *World J Pediatr Congenit Heart Surg* 2021;12:573–80.
- [541] Nota H, Asai T, Suzuki T, Kinoshita T, Ikegami H, Takashima N. Risk factors for acute kidney injury in aortic arch surgery with selective cerebral perfusion and mild hypothermic lower body circulatory arrest. *Interact CardioVasc Thorac Surg* 2014;19:955–61.
- [542] Crosina J, Lerner J, Ho J, Tangri N, Komenda P, Hiebert B et al. Improving the prediction of cardiac surgery-associated acute kidney injury. *Kidney Int Rep* 2017;2:172–9.
- [543] Arnaoutakis GJ, Bihorac A, Martin TD, Hess PJ Jr, Klodell CT, Ejaz AA et al. RIFLE criteria for acute kidney injury in aortic arch surgery. *J Thorac Cardiovasc Surg* 2007;134:1554–60.
- [544] Cooper WA, Duarte IG, Thourani VH, Nakamura M, Wang NP, Brown WM 3rd, et al. Hypothermic circulatory arrest causes multisystem vascular endothelial dysfunction and apoptosis. *Ann Thorac Surg* 2000;69:696–702.
- [545] Augoustides JG, Pochettino A, Ochroch EA, Cowie D, Weiner J, Gambone AJ et al. Renal dysfunction after thoracic aortic surgery requiring deep hypothermic circulatory arrest: definition, incidence, and clinical predictors. *J Cardiothorac Vasc Anesth* 2006;20:673–7.
- [546] Arnaoutakis GJ, Vallabhajosyula P, Bavaria JE, Sultan I, Siki M, Naidu S et al. The impact of deep versus moderate hypothermia on postoperative kidney function after elective aortic hemiarch repair. *Ann Thorac Surg* 2016;102:1313–21.
- [547] Englberger L, Suri RM, Greason KL, Burkhart HM, Sundt TM 3rd, Daly RC et al. Deep hypothermic circulatory arrest is not a risk factor for acute kidney injury in thoracic aortic surgery. *J Thorac Cardiovasc Surg* 2011;141:552–8.
- [548] Tsai JY, Pan W, Lemaire SA, Pisklak P, Lee VV, Bracey AW et al. Moderate hypothermia during aortic arch surgery is associated with reduced risk of early mortality. *J Thorac Cardiovasc Surg* 2013;146:662–7.
- [549] Vekstein AM, Yerokun BA, Jawitz OK, Doberne JW, Anand J, Karhausen J et al. Does deeper hypothermia reduce the risk of acute kidney injury after circulatory arrest for aortic arch surgery? *Eur J Cardiothorac Surg* 2021;60:314–21.
- [550] Boodhwani M, Rubens FD, Wozny D, Nathan HJ. Effects of mild hypothermia and rewarming on renal function after coronary artery bypass grafting. *Ann Thorac Surg* 2009;87:489–95.
- [551] Engelman R, Baker RA, Likosky DS, Grigore A, Dickinson TA, Shore-Lesserson L et al. American Society of ExtraCorporeal Technology. The Society of Thoracic Surgeons, The Society of Cardiovascular Anesthesiologists, and The American Society of ExtraCorporeal Technology: clinical practice guidelines for cardiopulmonary bypass—temperature management during cardiopulmonary bypass. *Ann Thorac Surg* 2015;100:748–57.
- [552] Tang Z, Lv Y, Wang B, Yang Z, Liu Y, Jiang H. Lower body perfusion reduces the morbidity of postoperative acute kidney injury in type a dissection: a propensity-matched analysis. *Braz J Cardiovasc Surg* 2023;38:346–52.
- [553] Miller CC 3rd, Villa MA, Achouh P, Estrera AL, Azizzadeh A, Coogan SM et al. Intraoperative skeletal muscle ischemia contributes to risk of renal dysfunction following thoracoabdominal aortic repair. *Eur J Cardiothorac Surg* 2008;33:691–4.
- [554] Miller CC 3rd, Grimm JC, Estrera AL, Azizzadeh A, Coogan SM, Walkes JC et al. Postoperative renal function preservation with nonischemic femoral arterial cannulation for thoracoabdominal aortic repair. *J Vasc Surg* 2010;51:38–42.

- [555] Kougias P, Branco BC, Braun J, Sharath S, Younes H, Barshes NR et al. Ischemia-induced lower extremity neurologic impairment after fenestrated endovascular aneurysm repair. *J Vasc Surg* 2019;70:23–30.
- [556] Behrendt CA, Dayama A, Debus ES, Heidemann F, Matolo NM, Kölbel T et al. Lower extremity ischemia after abdominal aortic aneurysm repair. *Ann Vasc Surg* 2017;45:206–12.
- [557] Kaki A, Alraies MC, Kajj M, Blank N, Glazier JJ, Mohamad T et al. Large bore occlusive sheath management. *Catheter Cardiovasc Interv* 2019;93:678–84.
- [558] Hanley SC, Neequaye SK, Steinmetz O, Obrand D, Mackenzie K, Abraham CZ. Sheath-shunt technique for avoiding lower limb ischemia during complex endovascular aneurysm repair. *J Vasc Surg* 2015;62:762–6.
- [559] Werner P, Gritsch J, Kaider A, Coti I, Osorio E, Mahr S et al. Long term results of the modified Bentall procedure with mechanical and biological composite valve grafts. *Front Cardiovasc Med* 2022;9:867732.
- [560] Elbatarny M, Tam DY, Edelman JJ, Rocha RV, Chu MWA, Peterson MD et al. Canadian Thoracic Aortic Collaborative (CTAC) Investigators. Valve-sparing root replacement versus composite valve grafting in aortic root dilation: a meta-analysis. *Ann Thorac Surg* 2020;110:296–306.
- [561] Di Marco L, Pacini D, Pantaleo A, Leone A, Barberio G, Marinelli G et al. Composite valve graft implantation for the treatment of aortic valve and root disease: results in 1045 patients. *J Thorac Cardiovasc Surg* 2016;152:1041–8.e1.
- [562] Ouzounian M, Rao V, Manlihot C, Abraham N, David C, Feindel CM et al. Valve-sparing root replacement compared with composite valve graft procedures in patients with aortic root dilation. *J Am Coll Cardiol* 2016;68:1838–47.
- [563] Rashid HN, Chehab O, Hurrell H, Androschuk V, Sularz A, Patterson T et al. Conventional aortic root vs valve-sparing root replacement surgery in aortic dilatation syndromes: a comparison of mortality and post-operative complications. *Expert Rev Cardiovasc Ther* 2023;21:57–65.
- [564] Froede L, Abeln KB, Ehrlich T, Feldner SK, Schäfers HJ. Twenty-five years' experience with root remodeling and bicuspid aortic valve repair. *Ann Cardiothorac Surg* 2022;11:418–25.
- [565] Leontyev S, Schamberger L, Davierwala PM, Von Aspern K, Etz C, Lehmann S et al. Early and late results after David vs Bentall procedure: a propensity matched analysis. *Ann Thorac Surg* 2020;110:120–6.
- [566] Ellauzi H, Zafar MA, Wu J, Papanikolaou D, Buntin J, Ziganshin BA et al. Fate of preserved aortic root following acute type A aortic dissection repair. *Semin Thorac Cardiovasc Surg* 2022;34:419–27.
- [567] Castrovinci S, Pacini D, Di Marco L, Berretta P, Cefarelli M, Murana G et al. Surgical management of aortic root in type A acute aortic dissection: a propensity-score analysis. *Eur J Cardiothorac Surg* 2016;50:223–9.
- [568] Kunihara T, Arimura S, Sata F, Giebels C, Schneider U, Schäfers HJ. Aortic annulus does not dilate over time after aortic root remodeling with or without annuloplasty. *J Thorac Cardiovasc Surg* 2018;155:885–94.e3.
- [569] Chauvette V, Kluin J, de Kerchove L, El Khoury G, Schäfers HJ, Lansac E et al. Outcomes of valve-sparing surgery in heritable aortic disorders: results from the AVIATOR registry. *Eur J Cardiothorac Surg* 2022;62:ezac366.
- [570] Yamabe T, Zhao Y, Kurlansky PA, Patel V, George I, Smith CR et al. Extent of aortic replacement and operative outcome in open proximal thoracic aortic aneurysm repair. *JTCVS Open* 2022;12:1–12.
- [571] Peterss S, Bhandari R, Rizzo JA, Fang H, Kuzmik GA, Ziganshin BA et al. The aortic root: natural history after root-sparing ascending replacement in nonsyndromic aneurysmal patients. *Ann Thorac Surg* 2017;103:828–33.
- [572] Hui DS, Chen EP, DeAnda A, Girardi LN, Kim KM, Woo YJ et al. The aortic root does not dilate over time after replacement of the aortic valve and ascending aorta in patients with bicuspid or tricuspid aortic valves. *J Thorac Cardiovasc Surg* 2018;166:1413.e1.
- [573] Cangut B, Greason KL, Todd A, Arghami A, Krishnan P, Crestanello JA et al. Aortic root replacement in the setting of a mildly dilated nonsyndromic ascending aorta. *J Thorac Cardiovasc Surg* 2022;166:983–93.
- [574] Milewski RK, Habrheuer A, Bavaria JE, Siki M, Szeto WY, Krause E et al. Fate of remnant sinuses of Valsalva in patients with bicuspid and trileaflet valves undergoing aortic valve, ascending aorta, and aortic arch replacement. *J Thorac Cardiovasc Surg* 2017;154:421–32.
- [575] Pearsall C, Blitzer D, Zhao Y, Yamabe T, Rajesh K, Kim I et al. Long-term outcome of hemiarch replacement in a proximal aortic aneurysm repair: analysis of over 1000 patients. *Eur J Cardiothorac Surg* 2022;62:ezab571.
- [576] Usui A, Ueda Y, Watanabe T, Kawaguchi O, Ohara Y, Takagi Y et al. Clinical results of implantation of an endovascular covered stent-graft via midsternotomy for distal aortic arch aneurysm. *Cardiovasc Surg* 2000;8:545–9.
- [577] Karck M, Chavan A, Hagl C, Friedrich H, Galanski M, Haverich A. The frozen elephant trunk technique: a new treatment for thoracic aortic aneurysms. *J Thorac Cardiovasc Surg* 2003;125:1550–3.
- [578] Shrestha M, Martens A, Kaufeld T, Beckmann E, Bertele S, Krueger H et al. Single-centre experience with the frozen elephant trunk technique in 251 patients over 15 years. *Eur J Cardiothorac Surg* 2017;52:858–66.
- [579] Berger T, Weiss G, Voetsch A, Arnold Z, Kreibich M, Rylski B et al. Multicentre experience with two frozen elephant trunk prostheses in the treatment of acute aortic dissection. *Eur J Cardiothorac Surg* 2019;56:572–8.
- [580] Berger T, Kreibich M, Morlock J, Kondov S, Scheumann J, Kari FA et al. True-lumen and false-lumen diameter changes in the downstream aorta after frozen elephant trunk implantation. *Eur J Cardiothorac Surg* 2018;54:375–81.
- [581] Beckmann E, Martens A, Kaufeld T, Natanov R, Krueger H, Haverich A et al. Is total aortic arch replacement with the frozen elephant trunk procedure reasonable in elderly patients? *Eur J Cardiothorac Surg* 2021;60:131–7.
- [582] Wallen T, Carter T, Habrheuer A, Badhwar V, Jacobs JP, Yerokun B et al. National outcomes of elective hybrid arch debranching with endograft exclusion versus total arch replacement procedures: analysis of the Society of Thoracic Surgeons Adult Cardiac Surgery Database. *Aorta (Stamford)* 2021;9:21–9.
- [583] Weigang E, Parker JA, Czerny M, Lonn L, Bonser RS, Carrel TP et al. Should intentional endovascular stent-graft coverage of the left subclavian artery be preceded by prophylactic revascularisation? *Eur J Cardiothorac Surg* 2011;40:858–68.
- [584] Kondov S, Beyersdorf F, Braun N, Höhn R, Schlett C, Rylski B et al. Morphology of the left subclavian artery: implications for single-branched endovascular aortic arch repair. *Eur J Cardiothorac Surg* 2022;61:348–54.
- [585] Heuls S, Carlouz R, Brandstatt P, Loose C, Mace L, Burlaton JP. [Incidental CT discovery of an isolated thrombus in the aortic arch]. *Ann Cardiol Angeiol (Paris)* 1998;47:340–2.
- [586] Jayle C, Denis C, Saïs T, Charrière JM, Menu P, Piette JC et al. [Rupture of ascending aortic aneurysm revealing Takayasu's arteritis]. *Arch Mal Coeur Vaiss* 2002;95:955–8.
- [587] Mestres CA, Greco E, Madrid CG, Pomar JL. The ability of Salmonella to drill holes in the aorta. *Eur J Cardiothorac Surg* 2002;22:145.
- [588] Ventosa-Fernandez G, Milisenda JC, Pereda D, Mestres CA. Infected false aneurysm of the aortic arch after endoscopic transurethral instillation of Bacillus Calmette-Guérin. *Ann Thorac Surg* 2015;100:717–20.
- [589] Koechlin L, Schuerpf J, Bremerich J, Sommer G, Gahl B, Reuthebuch O et al. Acute aortic dissection with entry tear at the aortic arch: long-term outcome. *Interact CardioVasc Thorac Surg* 2021;32:89–96.
- [590] Sethi S, Parekh U. Aortic Arch Aneurysm. [Updated 2023 Jul 24]. In: StatPearls [Internet]. Treasure Island (FL): StatPearls Publishing; 2023 Jan-. Available from: <https://www.ncbi.nlm.nih.gov/books/NBK563170/>.
- [591] Ghoneim MM, Hinrichs JV, Chiang CK, Loke WH. Pharmacokinetic and pharmacodynamic interactions between caffeine and diazepam. *J Clin Psychopharmacol* 1986;6:75–80.
- [592] Tokuda Y, Narita Y, Fujimoto K, Mutsuga M, Terazawa S, Ito H et al. Neurologic deficit after aortic arch replacement: the influence of the aortic atherosclerosis. *Ann Thorac Surg* 2019;108:107–14.
- [593] Beckmann E, Shrestha ML. The 7 pillars of the frozen elephant trunk. *Innovations (Phila)* 2022;17:255–8.
- [594] Borst HG, Waltherbusch G, Schaps D. Extensive aortic replacement using "elephant trunk" prosthesis. *Thorac Cardiovasc Surg* 1983;31:37–40.
- [595] Shrestha M, Bachtel J, Bavaria J, Carrel TP, De Paulis R, Di Bartolomeo R et al. Current status and recommendations for use of the frozen elephant trunk technique: a position paper by the Vascular Domain of EACTS. *Eur J Cardiothorac Surg* 2015;47:759–69.
- [596] D'Onofrio A, Lachat M, Mangialardi N, Antonello M, Schelzig H, Chaykovska L et al. Three-year follow-up of aortic arch endovascular stent grafting with the Nexus device: results from a prospective multicentre study. *Eur J Cardiothorac Surg* 2022;63:ezac561.
- [597] Rong D, Zhang H, Guo W. Aortic arch aneurysm isolated by percutaneous total endovascular arch replacement. *Eur Heart J* 2022;43:2905.

- [598] Kreibich M, Rylski B, Kondov S, Morlock J, Scheumann J, Kari FA et al. Endovascular treatment of acute type A aortic dissection—the Endo Bentall approach. *J Vis Surg* 2018;4:69.
- [599] Gouveia EMR, Stana J, Prendes CF, Kölbl T, Peterss S, Stavroulakis K et al. Current state and future directions of endovascular ascending and arch repairs: the motion towards an endovascular Bentall procedure. *Semin Vasc Surg* 2022;35:350–63.
- [600] Rylski B, Berkarda Z, Beyersdorf F, Kondov S, Czerny M, Majcherek J et al. Efficacy and safety of percutaneous access via large-bore sheaths (22–26F diameter) in endovascular therapy. *J Endovasc Ther* 2023;15266028231161490.
- [601] Zeeshan A, Woo EY, Bavaria JE, Fairman RM, Desai ND, Pochettino A et al. Thoracic endovascular aortic repair for acute complicated type B aortic dissection: superiority relative to conventional open surgical and medical therapy. *J Thorac Cardiovasc Surg* 2010;140:S109–15.
- [602] Fattori R, Tsai TT, Myrmet T, Evangelista A, Cooper JV, Trimarchi S et al. Complicated acute type B dissection: is surgery still the best option?: a report from the International Registry of Acute Aortic Dissection. *JACC Cardiovasc Interv* 2008;1:395–402.
- [603] DuBois BG, Houben IB, Khaja MS, Yang B, Kim KM, van Herwaarden JA et al. Thoracic endovascular aortic repair in the setting of compromised distal landing zones. *Ann Thorac Surg* 2021;111:237–45.
- [604] Zhao Y, Yin H, Chen Y, Wang M, Zheng L, Li Z et al. Restrictive bare stent prevents distal stent graft-induced new entry in endovascular repair of type B aortic dissection. *J Vasc Surg* 2018;67:93–103.
- [605] Mascia D, Rinaldi E, Salvati S, Melloni A, Kahlberg A, Bertoglio L et al. Thoracic endovascular aortic repair with additional distal bare stents in type B aortic dissection does not prevent long-term aneurysmal degeneration. *J Endovasc Ther* 2021;28:425–33.
- [606] Rong D, Ge Y, Liu J, Liu X, Guo W. Combined proximal descending aortic endografting plus distal bare metal stenting (PETTICOAT technique) versus conventional proximal descending aortic stent graft repair for complicated type B aortic dissections. *Cochrane Database Syst Rev* 2019;2019:CD013149.
- [607] Tsilimparis N, Debus S, Chen M, Zhou Q, Seale MM, Kölbl T. Results from the study to assess outcomes after endovascular repair for multiple thoracic aortic diseases (SUMMIT). *J Vasc Surg* 2018;68:1324–34.
- [608] Patel AY, Eagle KA, Vaishnava P. Acute type B aortic dissection: insights from the International Registry of Acute Aortic Dissection. *Ann Cardiothorac Surg* 2014;3:368–74.
- [609] Benfor B, Stana J, Fernandez Prendes C, Pichlmaier M, Mehmedovic A, Banafsche R et al. A single-center experience with total percutaneous implantation of a low-profile thoracic aortic stent-graft. *J Endovasc Ther* 2023;30:214–22.
- [610] Szeto WY, Vallabhajosyula P, Matsuda H, Moainie SL, Sharafuddin MJ, Corvera J et al. RelayPro-A Investigators. One-year results with a low-profile endograft in subjects with thoracic aortic aneurysm and ulcer pathologies. *J Thorac Cardiovasc Surg* 2022;163:1739–50.e4.
- [611] Mustafi M, Andic M, Bartos O, Grözinger G, Schlensak C, Lescan M. Comparison of aortic remodelling after conservative treatment or thoracic endovascular repair in type B dissections. *Interact CardioVasc Thorac Surg* 2020;30:458–64.
- [612] Marrocco-Trischitta MM, Romarowski RM, de Beaufort HW, Conti M, Vitale R, Secchi F et al. The Modified Arch Landing Areas Nomenclature identifies hostile zones for endograft deployment: a confirmatory biomechanical study in patients treated by thoracic endovascular aortic repair. *Eur J Cardiothorac Surg* 2019;55:990–7.
- [613] Piazza M, Squizzato F, Xodo A, Saviane G, Forcella E, Dal Pont C et al. Determination of optimal and safest proximal sealing length during thoracic endovascular aortic repair. *Eur J Vasc Endovasc Surg* 2021;62:423–30.
- [614] Marrocco-Trischitta MM, Spampinato B, Mazzeo G, Mazzaccaro D, Milani V, Alaidroos M et al. Impact of the bird-beak configuration on postoperative outcome after thoracic endovascular aortic repair: a meta-analysis. *J Endovasc Ther* 2019;26:771–8.
- [615] Moulakakis KG, Mylonas SN, Markatis F, Kotsis T, Kakisis J, Liapis CD. A systematic review and meta-analysis of hybrid aortic arch replacement. *Ann Cardiothorac Surg* 2013;2:247–60.
- [616] Kölbl T, Eleshra A, Aldag M, Rohlfss F, Debus SE, Honig S et al. Endovascular treatment of aortic pathologies in patients with Marfan syndrome: single-center experience. *J Endovasc Ther* 2022;29:602–10.
- [617] Eleshra A, Panuccio G, Spanos K, Rohlfss F, von Kodolitsch Y, Kölbl T. Safety and effectiveness of TEVAR in native proximal landing zone 2 for chronic type B aortic dissection in patients with genetic aortic syndrome. *J Endovasc Ther* 2022;29:717–23.
- [618] Eggebrecht H, Thompson M, Rousseau H, Czerny M, Lönn L, Mehta RH et al. European Registry on Endovascular Aortic Repair Complications. Retrograde ascending aortic dissection during or after thoracic aortic stent graft placement: insight from the European registry on endovascular aortic repair complications. *Circulation* 2009;120:S276–81.
- [619] Dong Z, Fu W, Wang Y, Wang C, Yan Z, Guo D et al. Stent graft-induced new entry after endovascular repair for Stanford type B aortic dissection. *J Vasc Surg* 2010;52:1450–7.
- [620] Bonci G, Steigner ML, Hanley M, Braun AR, Desjardins B, Gaba RC et al. Expert Panels on Vascular Imaging and Interventional Radiology. ACR appropriateness criteria® thoracic aorta interventional planning and follow-up. *J Am Coll Radiol* 2017;14:S570–83.
- [621] Kuo EC, Veranyan N, Johnson CE, Weaver FA, Ham SW, Rowe VL et al. Impact of proximal seal zone length and intramural hematoma on clinical outcomes and aortic remodeling after thoracic endovascular aortic repair for aortic dissections. *J Vasc Surg* 2019;69:987–95.
- [622] Chen Y, Zhang S, Liu L, Lu Q, Zhang T, Jing Z. Retrograde type A aortic dissection after thoracic endovascular aortic repair: a systematic review and meta-analysis. *J Am Heart Assoc* 2017;6:e004649.
- [623] Liu L, Zhang S, Lu Q, Jing Z, Zhang S, Xu B. Impact of oversizing on the risk of retrograde dissection after TEVAR for acute and chronic type B dissection. *J Endovasc Ther* 2016;23:620–5.
- [624] Lescan M, Mustafi M, Wilhelm V, Keller M, Schlensak C, Rosenberger P et al. The impact of dissection membrane motility on mid-term aortic remodelling after thoracic endovascular repair. *Eur J Cardiothorac Surg* 2022;61:869–76.
- [625] Czerny M, Eggebrecht H, Rousseau H, Mouroz PR, Janosi RA, Lescan M et al. Distal stent graft-induced new entry after TEVAR or FET: insights into a new disease from EuREC. *Ann Thorac Surg* 2020;110:1494–500.
- [626] Ma T, Dong ZH, Fu WG, Guo DQ, Xu X, Chen B et al. Incidence and risk factors for retrograde type A dissection and stent graft-induced new entry after thoracic endovascular aortic repair. *J Vasc Surg* 2018;67:1026–33.e2.
- [627] Andic M, Mustafi M, Bonorden C, Grözinger G, Artzner C, Schlensak C et al. Longitudinal morphological changes of the aorta and the endograft position before and after distal stent graft-induced new entry in aortic dissections. *Eur J Cardiothorac Surg* 2022;63:ezac547.
- [628] Lescan M, Czerny M, Berezowski M, Andic M, Bamberg F, Beyersdorf F et al. Morphologic performance analysis of the Relay nonbare stent graft in dissected thoracic aorta. *J Vasc Surg* 2019;70:1390–8.
- [629] Faure EM, El Batti S, Abou Rjeili M, Julia P, Alsac JM. Mid-term outcomes of stent assisted balloon induced intimal disruption and relamination in aortic dissection repair (STABILISE) in acute type B aortic dissection. *Eur J Vasc Endovasc Surg* 2018;56:209–15.
- [630] Czerny M, Reser D, Eggebrecht H, Janata K, Sodeck G, Etz C et al. Aorto-bronchial and aorto-pulmonary fistulation after thoracic endovascular aortic repair: an analysis from the European Registry of Endovascular Aortic Repair Complications. *Eur J Cardiothorac Surg* 2015;48:252–7.
- [631] Rocha RV, Friedrich JO, Elbatarny M, Yanagawa B, Al-Omran M, Forbes TL et al. A systematic review and meta-analysis of early outcomes after endovascular versus open repair of thoracoabdominal aortic aneurysms. *J Vasc Surg* 2018;68:1936–45.e5.
- [632] Varkevisser RRB, O'Donnell TFX, Swerdlow NJ, Liang P, Li C, Ultee KHJ et al. Fenestrated endovascular aneurysm repair is associated with lower perioperative morbidity and mortality compared with open repair for complex abdominal aortic aneurysms. *J Vasc Surg* 2019;69:1670–8.
- [633] Coselli JS, de la Cruz KI, Preventza O, LeMaire SA, Weldon SA. Extent II thoracoabdominal aortic aneurysm repair: how I do it. *Semin Thorac Cardiovasc Surg* 2016;28:221–37.
- [634] Lopez-Marco A, Adams B, Oo AY. Thoracoabdominal aneurysmectomy: operative steps for Crawford extent II repair. *JTCVS Tech* 2020;3:25–36.
- [635] Tanaka A, Estrera AL, Safi HJ. Open thoracoabdominal aortic aneurysm surgery technique: how we do it. *J Cardiovasc Surg (Torino)* 2021;62:295–301.
- [636] Schepens MA. Left heart bypass for thoracoabdominal aortic aneurysm repair: technical aspects. *Multimed Man Cardiothorac Surg* 2016;2016:mmv039.
- [637] Etz CD, Plestis KA, Kari FA, Luehr M, Bodian CA, Spielvogel D et al. Staged repair of thoracic and thoracoabdominal aortic aneurysms using the elephant trunk technique: a consecutive series of 215 first stage and 120 complete repairs. *Eur J Cardiothorac Surg* 2008;34:605–14.
- [638] Berger T, Kreibich M, Rylski B, Kondov S, Fagu A, Beyersdorf F et al. The 3-step approach for the treatment of multisegmental thoracoabdominal aortic pathologies. *Interact CardioVasc Thorac Surg* 2021;33:269–75.

- [639] Thompson MA, Lowry AM, Caputo F, Johnston DR, Smolock C, Vargo P et al. Collaborators in the Cleveland Clinic Aorta Center. Ultra-hybrid repair: open thoracoabdominal completion after descending stent grafting. *Semin Thorac Cardiovasc Surg* 2022;51043-0679(22)00256-8.
- [640] Loschi D, Melloni A, Grandi A, Baccellieri D, Monaco F, Melissano G et al. Open or endovascular treatment of downstream thoracic or thoraco-abdominal aortic pathology after frozen elephant trunk: perioperative and mid-term outcomes. *Eur J Cardiothorac Surg* 2021;61:120-9.
- [641] Waked K, Schepens M. State-of-the-art review on the renal and visceral protection during open thoracoabdominal aortic aneurysm repair. *J Vis Surg* 2018;4:31.
- [642] Squizzato F, Antonello M, Forcella E, Coppadoro S, Colacchio C, Xodo A et al. Geometrical determinants of target vessel instability in fenestrated endovascular aortic repair. *J Vasc Surg* 2022;76:335-43.e2.
- [643] Eleshra A, Oderich GS, Spanos K, Panuccio G, Kärkkäinen JM, Tenorio ER et al. Short-term outcomes of the t-branch off-the-shelf multi-branched stent graft for reintervention after previous infrarenal aortic repair. *J Vasc Surg* 2020;72:1558-66.
- [644] Piazza M, Squizzato F, Xodo A, Gubert A, Grego F, Antonello M. Effect of branch length and tortuosity on the outcomes of branched endovascular repair of thoracoabdominal aneurysms using self-expandable bridging stent graft. *J Vasc Surg* 2021;74:363-71.e3.
- [645] Mezzetto L, Scorsone L, Silingardi R, Gennai S, Piffaretti G, Mantovani A et al. Bridging stents in fenestrated and branched endovascular aneurysm repair: a systematic review. *Ann Vasc Surg* 2021;73:454-62.
- [646] Kärkkäinen JM, Tenorio ER, Pather K, Mendes BC, Macedo TA, Wigham J et al. Outcomes of small renal artery targets in patients treated by fenestrated-branched endovascular aortic repair. *Eur J Vasc Endovasc Surg* 2020;59:910-7.
- [647] Motta F, Parodi FE, Knowles M, Crouner JR, Pascarella L, McGinigle KL et al. Performance of Viabahn balloon-expandable stent compared with self-expandable covered stents for branched endovascular aortic repair. *J Vasc Surg* 2021;73:410-6.e2.
- [648] Mastracci TM, Carrell T, Constantinou J, Dias N, Martin-Gonzalez T, Katsargyris A et al. Editor's choice—effect of branch stent choice on branch-related outcomes in complex aortic repair. *Eur J Vasc Endovasc Surg* 2016;51:536-42.
- [649] Chamseddin K, Timaran CH, Oderich GS, Tenorio ER, Farber MA, Parodi FE et al. U.S. Aortic Research Consortium. Comparison of upper extremity and transfemoral access for fenestrated-branched endovascular aortic repair. *J Vasc Surg* 2023;77:704-11.
- [650] O'Callaghan A, Mastracci TM, Eagleton MJ. Staged endovascular repair of thoracoabdominal aortic aneurysms limits incidence and severity of spinal cord ischemia. *J Vasc Surg* 2015;61:347-54.e1.
- [651] Powell JT, Sweeting MJ, Ulug P, Blankensteijn JD, Lederle FA, Becquemini JP et al. EVAR-1, DREAM, OVER and ACE Trialists. Meta-analysis of individual-patient data from EVAR-1, DREAM, OVER and ACE trials comparing outcomes of endovascular or open repair for abdominal aortic aneurysm over 5 years. *Br J Surg* 2017;104:166-78.
- [652] Patel R, Sweeting MJ, Powell JT, Greenhalgh RM; EVAR trial investigators. Endovascular versus open repair of abdominal aortic aneurysm in 15-years' follow-up of the UK endovascular aneurysm repair trial 1 (EVAR trial 1): a randomised controlled trial. *Lancet* 2016;388:2366-74.
- [653] Lederle FA, Kyriakides TC, Stroupe KT, Freischlag JA, Padberg FT Jr, Matsumura JS et al. OVER Veterans Affairs Cooperative Study Group. Open versus endovascular repair of abdominal aortic aneurysm. *N Engl J Med* 2019;380:2126-35.
- [654] van Schaik TG, Meekel JP, Hoksbergen AWJ, de Vries R, Blankensteijn JD, Yeung KK. Long-term survival and secondary procedures after open or endovascular repair of abdominal aortic aneurysms. *J Vasc Surg* 2017;74:1024-32.
- [655] Kristensen SD, Knuuti J, Saraste A, Anker S, Bøtker HE, Hert SD et al. 2014 ESC/ESA Guidelines on non-cardiac surgery: cardiovascular assessment and management: the Joint Task Force on non-cardiac surgery: cardiovascular assessment and management of the European Society of Cardiology (ESC) and the European Society of Anaesthesiology (ESA). *Eur Heart J* 2014;35:2383-431.
- [656] Brady AR, Fowkes FG, Greenhalgh RM, Powell JT, Ruckley CV, Thompson SG. Risk factors for postoperative death following elective surgical repair of abdominal aortic aneurysm: results from the UK Small Aneurysm Trial. On behalf of the UK Small Aneurysm Trial participants. *Br J Surg* 2000;87:742-9.
- [657] Hallin A, Bergqvist D, Holmberg L. Literature review of surgical management of abdominal aortic aneurysm. *Eur J Vasc Endovasc Surg* 2001;22:197-204.
- [658] Mei F, Hu K, Zhao B, Gao Q, Chen F, Zhao L et al. Retroperitoneal versus transperitoneal approach for elective open abdominal aortic aneurysm repair. *Cochrane Database Syst Rev* 2021;6:CD010373.
- [659] Buck DB, Ultee KH, Zettervall SL, Soden PA, Darling J, Wyers M et al. Transperitoneal versus retroperitoneal approach for open abdominal aortic aneurysm repair in the targeted vascular National Surgical Quality Improvement Program. *J Vasc Surg* 2016;64:585-91.
- [660] Deery SE, Zettervall SL, O'Donnell TFX, Goodney PP, Weaver FA, Teixeira PG et al. Transabdominal open abdominal aortic aneurysm repair is associated with higher rates of late reintervention and readmission compared with the retroperitoneal approach. *J Vasc Surg* 2020;71:39-45.e1.
- [661] Pandirajan K, Katsogridakis E, Sidloff D, Sayers RD, Bown MJ, Saratzis A. Effects of left renal vein ligation during open abdominal aortic aneurysm repair on renal function. *Eur J Vasc Endovasc Surg* 2020;60:829-35.
- [662] Marconi M, Ceragioli S, Mocellin DM, Alberti A, Tomei F, Adami D et al. Open surgical management of hypogastric artery during aortic surgery: ligate or not ligate? *Ann Vasc Surg* 2015;29:780-5.
- [663] Lee KB, Lu J, Macsata RA, Patel D, Yang A, Ricotta JJ et al. Inferior mesenteric artery replantation does not decrease the risk of ischemic colitis after open infrarenal abdominal aortic aneurysm repair. *J Vasc Surg* 2019;71:718-9.
- [664] Jayaraj A, DeMartino RR, Bower TC, Oderich GS, Gloviczki P, Kalra M et al. Outcomes following inferior mesenteric artery reimplantation during elective aortic aneurysm surgery. *Ann Vasc Surg* 2020;66:65-9.
- [665] Franks SC, Sutton AJ, Bown MJ, Sayers RD. Systematic review and meta-analysis of 12 years of endovascular abdominal aortic aneurysm repair. *Eur J Vasc Endovasc Surg* 2007;33:154-71.
- [666] Antoniou GA, Juszczak MT, Nasr H, Narlawar R, Antoniou SA, Matsagkas M et al. Prognosis review and time-to-event data meta-analysis of endovascular aneurysm repair outside versus within instructions for use of aortic endograft devices. *J Vasc Surg* 2020;71:1415-31.e15.
- [667] AbuRahma AF, Yacoub M, Mousa AY, Abu-Halimah S, Hass SM, Kazil J et al. Aortic neck anatomic features and predictors of outcomes in endovascular repair of abdominal aortic aneurysms following vs not following instructions for use. *J Am Coll Surg* 2016;222:579-89.
- [668] Herman CR, Charbonneau P, Hongku K, Dubois L, Hossain S, Lee K et al. Any nonadherence to instructions for use predicts graft-related adverse events in patients undergoing elective endovascular aneurysm repair. *J Vasc Surg* 2018;67:126-33.
- [669] Antoniou GA, Antoniou SA. Editor's choice—percutaneous access does not confer superior clinical outcomes over cutdown access for endovascular aneurysm repair: meta-analysis and trial sequential analysis of randomised controlled trials. *Eur J Vasc Endovasc Surg* 2021;61:383-94.
- [670] Lareyre F, Panthier F, Jean-Baptiste E, Hassen-Khodja R, Raffort J. Coverage of accessory renal arteries during endovascular aortic aneurysm repair: what are the consequences and the implications for clinical practice? *Angiology* 2019;70:12-9.
- [671] Mascoli C, Freyrie A, Gargiulo M, Gallitto E, Pini R, Faggioli G et al. Selective intra-procedural AAA sac embolization during EVAR reduces the rate of type II endoleak. *Eur J Vasc Endovasc Surg* 2016;51:632-9.
- [672] Mascoli C, Faggioli G, Gallitto E, Pini R, Fenelli C, Cerenelli L et al. Tailored sac embolization during EVAR for preventing persistent type II endoleak. *Ann Vasc Surg* 2021;76:293-301.
- [673] Giosdekos A, Antonopoulos CN, Sfyroeras GS, Moulakakis KG, Tsilimparis N, Kakisis JD et al. The use of iliac branch devices for preservation of flow in internal iliac artery during endovascular aortic aneurysm repair. *J Vasc Surg* 2020;71:2133-44.
- [674] Sweeting MJ, Patel R, Powell JT, Greenhalgh RM; EVAR Trial Investigators. Endovascular repair of abdominal aortic aneurysm in patients physically ineligible for open repair: very long-term follow-up in the EVAR-2 randomized controlled trial. *Ann Surg* 2017;266:713-9.
- [675] Patel R, Powell JT, Sweeting MJ, Epstein DM, Barrett JK, Greenhalgh RM. The UK Endovascular Aneurysm Repair (EVAR) randomised controlled trials: long-term follow-up and cost-effectiveness analysis. *Health Technol Assess* 2018;22:1-132.
- [676] Rao R, Lane TR, Franklin IJ, Davies AH. Open repair versus fenestrated endovascular aneurysm repair of juxtarenal aneurysms. *J Vasc Surg* 2015;61:242-55.

- [677] Patel SR, Ormisher DC, Griffin R, Jackson RJ, Lip GYH, Vallabhaneni SR; UK-COMPASS Trial. Editor's choice—comparison of open, standard, and complex endovascular aortic repair treatments for juxtarenal/short neck aneurysms: a systematic review and network meta-analysis. *Eur J Vasc Endovasc Surg* 2022;63:696–706.
- [678] Jongkind V, Yeung KK, Akkersdijk GJ, Heidsieck D, Reitsma JB, Tangelder GJ et al. Juxtarenal aortic aneurysm repair. *J Vasc Surg* 2010;52:760–7.
- [679] Katsargyris A, Oikonomou K, Klonaris C, Töpel I, Verhoeven EL. Comparison of outcomes with open, fenestrated, and chimney graft repair of juxtarenal aneurysms: are we ready for a paradigm shift? *J Endovasc Ther* 2013;20:159–69.
- [680] Jones AD, Waduud MA, Walker P, Stocken D, Bailey MA, Scott DJA. Meta-analysis of fenestrated endovascular aneurysm repair versus open surgical repair of juxtarenal abdominal aortic aneurysms over the last 10 years. *BJS Open* 2019;3:572–84.
- [681] Doonan RJ, Girsowicz E, Dubois L, Gill HL. A systematic review and meta-analysis of endovascular juxtarenal aortic aneurysm repair demonstrates lower perioperative mortality compared with open repair. *J Vasc Surg* 2019;70:2054–64.e3.
- [682] Caradu C, Berard X, Sassoust G, Midy D, Ducasse E. Chimney versus fenestrated endovascular aortic repair for juxta-renal aneurysms. *J Cardiovasc Surg (Torino)* 2018;59:600–10.
- [683] Qamhawi Z, Barge TF, Makris GC, Patel R, Wigham A, Anthony S et al. Editor's choice—systematic review of the use of endoanchors in endovascular aortic aneurysm repair. *Eur J Vasc Endovasc Surg* 2020;59:748–56.
- [684] Sweeting MJ, Balm R, Desgranges P, Ulug P, Powell JT; Ruptured Aneurysm Trialists. Individual-patient meta-analysis of three randomized trials comparing endovascular versus open repair for ruptured abdominal aortic aneurysm. *Br J Surg* 2015;102:1229–39.
- [685] Badger S, Forster R, Blair PH, Ellis P, Kee F, Harkin DW. Endovascular treatment for ruptured abdominal aortic aneurysm. *Cochrane Database Syst Rev* 2017;5:CD005261.
- [686] Amato B, Fugetto F, Compagna R, Zurlo V, Barbeta A, Petrella G et al. Endovascular repair versus open repair in the treatment of ruptured aortic aneurysms: a systematic review. *Minerva Chir* 2019;74:472–80.
- [687] Roosendaal LC, Kramer GM, Wiersema AM, Wisselink W, Jongkind V. Outcome of ruptured abdominal aortic aneurysm repair in octogenarians: a systematic review and meta-analysis. *Eur J Vasc Endovasc Surg* 2020;59:16–22.
- [688] Kontopodis N, Tavlakos E, Ioannou CV, Giannoukas AD, Geroulakos G, Antoniou GA. Systematic review and meta-analysis of outcomes of open and endovascular repair of ruptured abdominal aortic aneurysm in patients with hostile vs. friendly aortic anatomy. *Eur J Vasc Endovasc Surg* 2020;59:717–28.
- [689] D'Oria M, Hanson KT, Shermerhorn M, Bower TC, Mendes BC, Shuja F et al. Editor's choice—short term and long term outcomes after endovascular or open repair for ruptured infrarenal abdominal aortic aneurysms in the vascular quality initiative. *Eur J Vasc Endovasc Surg* 2020;59:703–16.
- [690] Oderich GS, Panneton JM, Bower TC, Cherry KJ Jr, Rowland CM, Noel AA et al. Infected aortic aneurysms: aggressive presentation, complicated early outcome, but durable results. *J Vasc Surg* 2001;34:900–8.
- [691] Sörelius K, Budtz-Lilly J, Mani K, Wanhainen A. Systematic review of the management of mycotic aortic aneurysms. *Eur J Vasc Endovasc Surg* 2019;58:426–35.
- [692] Shirasu T, Kuno T, Yasuhara J, Yokoyama Y, Takagi H, Cullen MJ et al. Meta-analysis finds recurrent infection is more common after endovascular than after open repair of infected abdominal aortic aneurysm. *J Vasc Surg* 2022;75:348–55.e10.
- [693] Lomazzi C, Piffaretti G, D'Oria M, Benedetto F, Stilo F, Mezzetto L et al. Collaborators. Early and midterm results after endovascular repair of non-infected sacular lesions of the infrarenal aorta. *Eur J Vasc Endovasc Surg* 2022;63:808–16.
- [694] Jonker FH, Schloesser FJ, Moll FL, Muhs BE. Dissection of the abdominal aorta. Current evidence and implications for treatment strategies: a review and meta-analysis of 92 patients. *J Endovasc Ther* 2009;16:71–80.
- [695] Jean-Baptiste E, Brizzi S, Bartoli MA, Sadaghianloo N, Baqué J, Magnan PE et al. Pelvic ischemia and quality of life scores after interventional occlusion of the hypogastric artery in patients undergoing endovascular aortic aneurysm repair. *J Vasc Surg* 2014;60:40–9, 49.e1.
- [696] Laine MT, Björck M, Beiles CB, Szeberin Z, Thomson I, Altreuther M et al. Few internal iliac artery aneurysms rupture under 4 cm. *J Vasc Surg* 2017;65:76–81.
- [697] Jalalzadeh H, Indrakusuma R, Koelmay MJW, Balm R, Van den Akker LH, Van den Akker PJ et al. Collaborators. Editor's choice—nationwide analysis of patients undergoing iliac artery aneurysm repair in the Netherlands. *Eur J Vasc Endovasc Surg* 2020;60:49–55.
- [698] Chaer RA, Barbato JE, Lin SC, Zenati M, Kent KC, McKinsey JF. Isolated iliac artery aneurysms: a contemporary comparison of endovascular and open repair. *J Vasc Surg* 2008;47:708–13.
- [699] Kouvelos GN, Katsargyris A, Antoniou GA, Oikonomou K, Verhoeven EL. Outcome after interruption or preservation of internal iliac artery flow during endovascular repair of abdominal aorto-iliac aneurysms. *Eur J Vasc Endovasc Surg* 2016;52:621–34.
- [700] Bosanquet DC, Ansell J, Abdelrahman T, Cornish J, Harries R, Stimpson A et al. Systematic review and meta-regression of factors affecting midline incisional hernia rates: analysis of 14,618 patients. *PLoS One* 2015;10:e0138745.
- [701] Eagleton MJ, Shah S, Petkosevek D, Mastracci TM, Greenberg RK. Hypogastric and subclavian artery patency affects onset and recovery of spinal cord ischemia associated with aortic endografting. *J Vasc Surg* 2014;59:89–94.
- [702] Kasirajan V, Hertzner NR, Beven EG, O'Hara PJ, Krajewski LP, Sullivan TM. Management of isolated common iliac artery aneurysms. *Cardiovasc Surg* 1998;6:171–7.
- [703] Buck DB, Bensley RP, Darling J, Curran T, McCallum JC, Moll FL et al. The effect of endovascular treatment on isolated iliac artery aneurysm treatment and mortality. *J Vasc Surg* 2015;62:331–5.
- [704] Patel NV, Long GW, Cheema ZF, Rimar K, Brown OW, Shanley CJ. Open vs. endovascular repair of isolated iliac artery aneurysms: a 12-year experience. *J Vasc Surg* 2009;49:1147–53.
- [705] Pitoulis GA, Donas KP, Schulte S, Horsch S, Papadimitriou DK. Isolated iliac artery aneurysms: endovascular versus open elective repair. *J Vasc Surg* 2007;46:648–54.
- [706] Simonte G, Parlani G, Farchioni L, Isernia G, Cieri E, Lenti M et al. Lesson learned with the use of iliac branch devices: single centre 10 year experience in 157 consecutive procedures. *Eur J Vasc Endovasc Surg* 2017;54:95–103.
- [707] Taudorf M, Grønvall J, Schroeder TV, Lönn L. Endovascular aneurysm repair treatment of aortoiliac aneurysms: can iliac branched devices prevent gluteal claudication? *J Vasc Interv Radiol* 2016;27:174–80.
- [708] Sousa LHD, Baptista-Silva JC, Vasconcelos V, Flumignan RL, Nakano LC. Internal iliac artery revascularisation versus internal iliac artery occlusion for endovascular treatment of aorto-iliac aneurysms. *Cochrane Database Syst Rev* 2020;7:CD013168.
- [709] Lawrence PF, Gazak C, Bhirangi L, Jones B, Bhirangi K, Oderich G et al. The epidemiology of surgically repaired aneurysms in the United States. *J Vasc Surg* 1999;30:632–40.
- [710] Armon MP, Wenham PW, Whitaker SC, Gregson RH, Hopkinson BR. Common iliac artery aneurysms in patients with abdominal aortic aneurysms. *Eur J Vasc Endovasc Surg* 1998;15:255–7.
- [711] Gray D, Shahverdyan R, Reifferscheid V, Gawenda M, Brunkwall JS. EVAR with flared iliac limbs has a high risk of late type 1b endoleak. *Eur J Vasc Endovasc Surg* 2017;54:170–6.
- [712] Bahrolloomi D, Qato K, Nguyen N, Schreiber-Gregory D, Conway AM, Giangola G et al. External iliac artery extension causes greater aneurysm sac regression than the bell-bottom technique or iliac branch endoprosthesis for repair of concomitant infrarenal aortic and iliac artery aneurysm. *J Vasc Surg* 2022;76:132–40.
- [713] Franklin RN, Timi JRR, Baumgardt G, Bortoluzzi C, Galego G, Oderich GS et al. Laboratory "in vitro" evaluation of the parallel stent graft association for the iliac sandwich technique. *Cardiovasc Intervent Radiol* 2022;45:1377–84.
- [714] Lobato AC, Camacho-Lobato L. The sandwich technique to treat complex aortoiliac or isolated iliac aneurysms: results of midterm follow-up. *J Vasc Surg* 2013;57:265–345.
- [715] Fujimura N, Matsubara K, Takahara M, Harada H, Asami A, Shibutani S et al. Early sac shrinkage is a good surrogate marker of durable success after endovascular aneurysm repair in Japanese patients. *J Vasc Surg* 2018;67:1410–8.e1.
- [716] Bastos Gonçalves F, van de Luijtgarden KM, Hoeks SE, Hendriks JM, ten Raa S, Rouwet EV et al. Adequate seal and no endoleak on the first post-operative computed tomography angiography as criteria for no additional imaging up to 5 years after endovascular aneurysm repair. *J Vasc Surg* 2013;57:1503–11.
- [717] Li C, Teter K, Rockman C, Garg K, Cayne N, Sadek M et al. Abdominal aortic aneurysm neck dilatation and sac remodeling in

- fenestrated compared to standard endovascular aortic repair. *Vascular* 2023;31:3-9.
- [718] Schlösser FJ, Gusberg RJ, Dardik A, Lin PH, Verhagen HJ, Moll FL et al. Aneurysm rupture after EVAR: can the ultimate failure be predicted? *Eur J Vasc Endovasc Surg* 2009;37:15-22.
- [719] Franssen GA, Vallabhaneni SR Sr, van Marrewijk CJ, Laheij RJ, Harris PL, Buth J; EUROSTAR. Rupture of infra-renal aortic aneurysm after endovascular repair: a series from EUROSTAR registry. *Eur J Vasc Endovasc Surg* 2003;26:487-93.
- [720] Lal BK, Zhou W, Li Z, Kyriakides T, Matsumura J, Lederle FA et al. OVER Veterans Affairs Cooperative Study Group. Predictors and outcomes of endoleaks in the Veterans Affairs Open Versus Endovascular Repair (OVER) trial of abdominal aortic aneurysms. *J Vasc Surg* 2015;62:1394-404.
- [721] Lo RC, Buck DB, Herrmann J, Hamdan AD, Wyers M, Patel VI et al. Vascular Study Group of New England. Risk factors and consequences of persistent type II endoleaks. *J Vasc Surg* 2016;63:895-901.
- [722] Sidloff DA, Stather PW, Choke E, Bown MJ, Sayers RD. Type II endoleak after endovascular aneurysm repair. *Br J Surg* 2013;100:1262-70.
- [723] Kontopodis N, Galanakis N, Kiparakis M, Ioannou CV, Kakisis I, Geroulakos G et al. Pre-emptive embolization of the aneurysm sac or aortic side branches in endovascular aneurysm repair: meta-analysis and trial sequential analysis of randomized controlled trials. *Ann Vasc Surg* 2023;91:90-107.
- [724] Yu HYH, Lindström D, Wanhainen A, Tegler G, Ascianto G, Mani K. An updated systematic review and meta-analysis of pre-emptive aortic side branch embolization to prevent type II endoleaks after endovascular aneurysm repair. *J Vasc Surg* 2022;77:1815-21.
- [725] Cornelissen SA, Verhagen HJ, Prokop M, Moll FL, Bartels LW. Visualizing type IV endoleak using magnetic resonance imaging with a blood pool contrast agent. *J Vasc Surg* 2008;47:861-4.
- [726] Dossabhoy SS, Simons JP, Diamond KR, Flahive JM, Aiello FA, Arous EJ et al. Reinterventions after fenestrated or branched endovascular aortic aneurysm repair. *J Vasc Surg* 2018;68:669-81.
- [727] Kärkkäinen JM, Tenorio ER, Jain A, Mendes BC, Macedo TA, Pather K et al. Outcomes of target vessel endoleaks after fenestrated-branched endovascular aortic repair. *J Vasc Surg* 2020;72:445-55.
- [728] Koole D, Moll FL, Buth J, Hobo R, Zandvoort HJ, Bots ML et al. European Collaborators on Stent-Graft Techniques for Aortic Aneurysm Repair (EUROSTAR). Annual rupture risk of abdominal aortic aneurysm enlargement without detectable endoleak after endovascular abdominal aortic repair. *J Vasc Surg* 2011;54:1614-22.
- [729] Husmann L, Huellner MW, Gruenig H, Ledergerber B, Messerli M, Mestres CA et al. Imaging characteristics and diagnostic accuracy of FDG-PET/CT, contrast enhanced CT and combined imaging in patients with suspected mycotic or inflammatory abdominal aortic aneurysms. *PLoS One* 2022;17:e0272772.
- [730] Lyons OT, Baguneid M, Barwick TD, Bell RE, Foster N, Homer-Vanniasinkam S et al. Diagnosis of aortic graft infection: a case definition by the management of aortic graft infection collaboration (MAGIC). *Eur J Vasc Endovasc Surg* 2016;52:758-63.
- [731] Anagnostopoulos A, Mayer F, Ledergerber B, Bergada-Pijuan J, Husmann L, Mestres CA et al. VASGRA Cohort Study. Editor's choice—validation of the management of aortic graft infection collaboration (MAGIC) criteria for the diagnosis of vascular graft/endograft infection: results from the prospective vascular graft cohort study. *Eur J Vasc Endovasc Surg* 2021;62:251-7.
- [732] Kahlberg A, Grandi A, Loschi D, Vermassen F, Moreels N, Chakfé N et al. A systematic review of infected descending thoracic aortic grafts and endografts. *J Vasc Surg* 2019;69:1941-51.e1.
- [733] Chong JH, Zhang Y, Harky A, Field M. Management and outcomes of proximal aortic graft infection: a systematic review. *Heart Lung Circ* 2022;31:49-58.
- [734] Delgado V, Ajmone Marsan N, de Waha S, Bonaros N, Brida M, Burri H et al. 2023 ESC Guidelines for the management of endocarditis: developed by the task force on the management of endocarditis of the European Society of Cardiology (ESC) Endorsed by the European Association for Cardio-Thoracic Surgery (EACTS) and the European Association of Nuclear Medicine (EANM). *Eur Heart J* 2023;44:3948-4042.
- [735] Gharamti A, Kanafani ZA. Vascular graft infections: an update. *Infect Dis Clin North Am* 2018;32:789-809.
- [736] Hasse B, Husmann L, Zinkernagel A, Weber R, Lachat M, Mayer D. Vascular graft infections. *Swiss Med Wkly* 2013;143:w13754.
- [737] Chakfé N, Diener H, Lejay A, Assadian O, Berard X, Caillon J et al. Editor's choice—European Society for Vascular Surgery (ESVS) 2020 clinical practice guidelines on the management of vascular graft and endograft infections. *Eur J Vasc Endovasc Surg* 2020;59:339-84.
- [738] Ajdler-Schaeffler E, Scherrer AU, Keller PM, Anagnostopoulos A, Hofmann M, Rancic Z et al. and the VASGRA Cohort. Increased pathogen identification in vascular graft infections by the combined use of tissue cultures and 16S rRNA gene polymerase chain reaction. *Front Med (Lausanne)* 2018;5:169.
- [739] Couture T, Gaudric J, Davaine JM, Jayet J, Chiche L, Jarraya M et al. Results of cryopreserved arterial allograft replacement for thoracic and thoracoabdominal aortic infections. *J Vasc Surg* 2021;73:626-34.
- [740] Vogt PR, Brunner-La Rocca HP, Carrel T, von Segesser LK, Ruff C, Debatin J et al. Cryopreserved arterial allografts in the treatment of major vascular infection: a comparison with conventional surgical techniques. *J Thorac Cardiovasc Surg* 1998;116:965-72.
- [741] Vogt PR, Brunner-LaRocca HP, Lachat M, Ruff C, Turina MI. Technical details with the use of cryopreserved arterial allografts for aortic infection: influence on early and midterm mortality. *J Vasc Surg* 2002;35:80-6.
- [742] Masabni K, Weaver MR, Kandagatla P, Shepard AD, Huang J, Al Adas Z et al. Cryopreserved allograft in the management of native and prosthetic aortic infections. *Ann Vasc Surg* 2019;56:1-10.
- [743] Bisdas T, Wilhelmi M, Haverich A, Teebken OE. Cryopreserved arterial homografts vs silver-coated Dacron grafts for abdominal aortic infections with intraoperative evidence of microorganisms. *J Vasc Surg* 2011;53:1274-81.e4.
- [744] Mufty H, Van den Bergh M, Meuris B, Metsemakers WJ, Fourneau I. Clinical studies reporting on vascular graft coatings for the prevention of aortic graft infection: a systematic review and meta-analysis. *Eur J Vasc Endovasc Surg* 2022;63:112-8.
- [745] Alonso W, Ozdemir B, Chassin-Trubert L, Ziza V, Alric P, Canaud L. Early outcomes of native and graft-related abdominal aortic infection managed with orthotopic xenopericardial grafts. *J Vasc Surg* 2021;73:222-31.
- [746] Kreibich M, Siepe M, Berger T, Pingpoh C, Puii P, Morlock J et al. Treatment of infectious aortic disease with bovine pericardial tube grafts. *Eur J Cardiothorac Surg* 2021;60:155-61.
- [747] Weiss S, Tobler EL, von Tengg-Kobligk H, Makaloski V, Becker D, Carrel TP et al. Self made xeno-pericardial aortic tubes to treat native and aortic graft infections. *Eur J Vasc Endovasc Surg* 2017;54:646-52.
- [748] Post I, Vos CG. Systematic review and meta-analysis on the management of open abdominal aortic graft infections. *Eur J Vasc Endovasc Surg* 2019;58:258-81.
- [749] Sarac TP, Augustinos P, Lyden S, Ouriel K. Use of fascia-peritoneum patch as a pledget for an infected aortic stump. *J Vasc Surg* 2003;38:1404-6.
- [750] Kaza AK, Cope JT, Kern JA, Cassada DC, Long SM, Fiser SM et al. A technique for adequate coverage of the proximal suture line during abdominal aortic aneurysm repair. *J Vasc Surg* 2001;34:367-8.
- [751] Janko MR, Woo K, Hacker RI, Baril D, Bath J, Smeds MR et al. In situ bypass and extra-anatomic bypass procedures result in similar survival in patients with secondary aortoenteric fistulas. *J Vasc Surg* 2021;73:210-21.e1.
- [752] Anastasiadou C, Trellopoulos G, Kastora S, Kakisis I, Papapetrou A, Galyfos G et al. A systematic review of therapies for aortobronchial fistulae. *J Vasc Surg* 2022;75:753-61.e3.
- [753] Jonker FH, Heijmen R, Trimarchi S, Verhagen HJ, Moll FL, Muhs BE. Acute management of aortobronchial and aorto-esophageal fistulas using thoracic endovascular aortic repair. *J Vasc Surg* 2009;50:999-1004.
- [754] Canaud L, Ozdemir BA, Bee WW, Bahia S, Holt P, Thompson M. Thoracic endovascular aortic repair in management of aorto-esophageal fistulas. *J Vasc Surg* 2014;59:248-54.
- [755] Czerny M, Eggebrecht H, Sodeck G, Weigang E, Livi U, Verzini F et al. New insights regarding the incidence, presentation and treatment options of aorto-oesophageal fistulation after thoracic endovascular aortic repair: the European Registry of Endovascular Aortic Repair Complications. *Eur J Cardiothorac Surg* 2014;45:452-7.
- [756] Georvasili VK, Bali C, Peroulis M, Kouvelos G, Avgos S, Godevenos D et al. Management of an aorto-esophageal fistula, complicating a descending thoracic aortic aneurysm endovascularly repaired. *Gen Thorac Cardiovasc Surg* 2016;64:216-9.
- [757] Sladojevic M, Bjelovic M, Ilic N, Mutavdzic P, Koncar I, Dragas M et al. Open surgical treatment of secondary aorto-esophageal and

- aortobronchial fistula after thoracic endovascular aortic repair and esophagocoloplasty in a second procedure. *Ann Vasc Surg* 2017;44:417.e11-16.
- [758] Donato F, Boskoski I, Vincenzoni C, Montanari F, Tinelli G, Donati T et al. A new mini-invasive approach for a catastrophic disease: staged endovascular and endoscopic treatment of aorto-esophageal fistulas. *J Pers Med* 2022;12:1735.
- [759] Oderich GS, Bower TC, Cherry KJ Jr, Panneton JM, Sullivan TM, Noel AA et al. Evolution from axillofemoral to in situ prosthetic reconstruction for the treatment of aortic graft infections at a single center. *J Vasc Surg* 2006;43:1166-74.
- [760] Hosoyama K, Kawamoto S, Motoyoshi N, Saiki Y. Intraoperative vacuum-assisted closure following in situ graft replacement for an infected thoracic aortic graft. *J Thorac Cardiovasc Surg* 2015;150:e36-8.
- [761] Nakajima N, Masuda M, Ichinose M, Ando M. A new method for the treatment of graft infection in the thoracic aorta: in situ preservation. *Ann Thorac Surg* 1999;67:1994-6.
- [762] Mirzaie M, Schmitt JD, Tirilomis T, Fatehpur S, Liakopoulos OJ, Teucher N et al. Surgical management of vascular graft infection in severely ill patients by partial resection of the infected prosthesis. *Eur J Vasc Endovasc Surg* 2007;33:610-3.
- [763] Hannon RJ, Wolfe JH, Mansfield AO. Aortic prosthetic infection: 50 patients treated by radical or local surgery. *Br J Surg* 1996;83:654-8.
- [764] Janko M, Hubbard G, Woo K, Kashyap VS, Mitchell M, Murugesan A et al. Contemporary outcomes after partial resection of infected aortic grafts. *Ann Vasc Surg* 2021;76:202-10.
- [765] Kouijzer IJE, Baranelli CT, Maat I, van den Heuvel FMA, Aarntzen E, Smith T et al. Thoracic aortic vascular graft infection: outcome after conservative treatment without graft removal. *Eur J Cardiothorac Surg* 2022;63:ezac551.
- [766] Akowuah E, Narayan P, Angelini G, Bryan AJ. Management of prosthetic graft infection after surgery of the thoracic aorta: removal of the prosthetic graft is not necessary. *J Thorac Cardiovasc Surg* 2007;134:1051-2.
- [767] Keidar Z, Pirmisashvili N, Leiderman M, Nitecki S, Israel O. 18F-FDG uptake in noninfected prosthetic vascular grafts: incidence, patterns, and changes over time. *J Nucl Med* 2014;55:392-5.
- [768] Husmann L, Huellner MW, Ledergerber B, Anagnostopoulos A, Stolzmann P, Sah BR et al. and the Vasgra Cohort. Comparing diagnostic accuracy of (18)F-FDG-PET/CT, contrast enhanced CT and combined imaging in patients with suspected vascular graft infections. *Eur J Nucl Med Mol Imaging* 2019;46:1359-68.
- [769] Erb S, Sidler JA, Elzi L, Gurke L, Battagay M, Widmer AF et al. Surgical and antimicrobial treatment of prosthetic vascular graft infections at different surgical sites: a retrospective study of treatment outcomes. *PLoS One* 2014;9:e112947.
- [770] Cinà CS, Althani H, Pasenau J, Abouzahr L. Kommerell's diverticulum and right-sided aortic arch: a cohort study and review of the literature. *J Vasc Surg* 2004;39:131-9.
- [771] Yang C, Shu C, Li M, Li Q, Kopp R. Aberrant subclavian artery pathologies and Kommerell's diverticulum: a review and analysis of published endovascular/hybrid treatment options. *J Endovasc Ther* 2012;19:373-82.
- [772] Tanaka A, Milner R, Ota T. Kommerell's diverticulum in the current era: a comprehensive review. *Gen Thorac Cardiovasc Surg* 2015;63:245-59.
- [773] Erben Y, Brownstein AJ, Velasquez CA, Li Y, Rizzo JA, Mojibian H et al. Natural history and management of Kommerell's diverticulum in a single tertiary referral center. *J Vasc Surg* 2020;71:2004-11.
- [774] Bath J, D'Oria M, Rogers RT, Colglazier JJ, Braet DJ, Coleman DM et al. Contemporary outcomes after treatment of aberrant subclavian artery and Kommerell's diverticulum. *J Vasc Surg* 2023;77:1339-48.e6.
- [775] Loschi D, Santoro A, Rinaldi E, Bilman V, Chiesa R, Melissano G. A systematic review of open, hybrid, and endovascular repair of aberrant subclavian artery and Kommerell's diverticulum treatment. *J Vasc Surg* 2023;77:642-9.e4.
- [776] Tallarita T, Rogers RT, Bower TC, Stone W, Farres H, Money SR et al. Characterization and surgical management of aberrant subclavian arteries. *J Vasc Surg* 2023;77:1006-15.
- [777] Dong S, Alarhayem AQ, Meier G, Hardy DM, Lyden SP, Farivar BS. Contemporary management and natural history of aberrant right subclavian artery. *J Vasc Surg* 2022;75:1343-8.e2.
- [778] Upchurch GR Jr, Escobar GA, Azzadeh A, Beck AW, Conrad MF, Matsumura JS et al. Society for Vascular Surgery clinical practice guidelines of thoracic endovascular aortic repair for descending thoracic aortic aneurysms. *J Vasc Surg* 2021;73:55s-83s.
- [779] Ben Ahmed S, Settembre N, Touma J, Brouat A, Favre JP, Jean Baptiste E et al. Outcomes in the treatment of aberrant subclavian arteries using the hybrid approach. *Interact CardioVasc Thorac Surg* 2022;35:ivac230.
- [780] Kouchoukos NT, Masetti P. Aberrant subclavian artery and Kommerell aneurysm: surgical treatment with a standard approach. *J Thorac Cardiovasc Surg* 2007;133:888-92.
- [781] van der Linde D, Konings EE, Slager MA, Witsenburg M, Helbing WA, Takkenberg JJ et al. Birth prevalence of congenital heart disease worldwide: a systematic review and meta-analysis. *J Am Coll Cardiol* 2011;58:2241-7.
- [782] Wren C, Reinhardt Z, Khawaja K. Twenty-year trends in diagnosis of life-threatening neonatal cardiovascular malformations. *Arch Dis Child Fetal Neonatal Ed* 2008;93:F33-5.
- [783] Samánek M, Slavík Z, Zborilová B, Hrobonová V, Vorísková M, Skovránek J. Prevalence, treatment, and outcome of heart disease in live-born children: a prospective analysis of 91,823 live-born children. *Pediatr Cardiol* 1989;10:205-11.
- [784] Hoffman JJ, Kaplan S. The incidence of congenital heart disease. *J Am Coll Cardiol* 2002;39:1890-900.
- [785] Allen HD. Moss and Adams' Heart Disease in Infants, Children, and Adolescents: Including the Fetus and Young Adult. Lippincott Williams & Wilkins, 2008, ISBN: 978-1-97-511660-6.
- [786] Stout KK, Daniels CJ, Aboulhosn JA, Bozkurt B, Broberg CS, Colman JM et al. 2018 AHA/ACC guideline for the management of adults with congenital heart disease: executive summary: a report of the American College of Cardiology/American Heart Association Task Force on Clinical Practice Guidelines. *Circulation* 2019;139:e637-97.
- [787] Baumgartner H, De Backer J. The ESC clinical practice guidelines for the management of adult congenital heart disease 2020. *Eur Heart J* 2020;41:4153-4.
- [788] Gach P, Dabadie A, Sorensen C, Quarello E, Bonello B, Pico H et al. Multimodality imaging of aortic coarctation: from the fetus to the adolescent. *Diagn Interv Imaging* 2016;97:581-90.
- [789] Malahfji M, Chamsi-Pasha MA. Advanced cardiac imaging for complex adult congenital heart diseases. *Methodist Debakey Cardiovasc J* 2019;15:99-104.
- [790] Rizk J. 4D flow MRI applications in congenital heart disease. *Eur Radiol* 2021;31:1160-74.
- [791] Rengier F, Geisbüsch P, Schoenhagen P, Müller-Eschner M, Vosshenrich R, Karmonik C et al. State-of-the-art aortic imaging: part II—applications in transcatheter aortic valve replacement and endovascular aortic aneurysm repair. *Vasa* 2014;43:6-26.
- [792] Reifenstein GH, Levine SA, Gross RE. Coarctation of the aorta; a review of 104 autopsied cases of the adult type, 2 years of age or older. *Am Heart J* 1947;33:146-68.
- [793] Campbell M. Natural history of atrial septal defect. *Br Heart J* 1970;32:820-6.
- [794] Gross RE. Surgical correction for coarctation of the aorta. *Surgery* 1945;18:673-8.
- [795] Crafoord C. The surgical treatment of coarctation of the aorta. *Surgery* 1947;21:146.
- [796] Blalock A, Park EA. The surgical treatment of experimental coarctation (atresia) of the aorta. *Ann Surg* 1944;119:445-56.
- [797] Singer MI, Rowen M, Dorsey TJ. Transluminal aortic balloon angioplasty for coarctation of the aorta in the newborn. *Am Heart J* 1982;103:131-2.
- [798] Hartman EM, Groenendijk IM, Heuvelman HM, Roos-Hesselink JW, Takkenberg JJ, Witsenburg M. The effectiveness of stenting of coarctation of the aorta: a systematic review. *EuroIntervention* 2015;11:660-8.
- [799] Erben Y, Oderich GS, Verhagen HJM, Witsenburg M, van den Hoven AT, Debus ES et al. Multicenter experience with endovascular treatment of aortic coarctation in adults. *J Vasc Surg* 2019;69:671-9.e1.
- [800] Roselli EE, Qureshi A, Idrees J, Lima B, Greenberg RK, Svensson LG et al. Open, hybrid, and endovascular treatment for aortic coarctation and postrepair aneurysm in adolescents and adults. *Ann Thorac Surg* 2012;94:751-6.
- [801] del Nido PJ, Williams WG, Wilson GJ, Coles JG, Moes CA, Hosokawa Y et al. Synthetic patch angioplasty for repair of coarctation of the aorta: experience with aneurysm formation. *Circulation* 1986;74(3 Pt 2):132-6.

- [802] Owens WA, Tolan MJ, Cleland J. Late results of patch repair of coarctation of the aorta in adults using autogenous arterial wall. *Ann Thorac Surg* 1997;64:1072-4.
- [803] Walhout RJ, Lekkerkerker JC, Oron GH, Hitchcock FJ, Meijboom EJ, Bennink GB. Comparison of polytetrafluoroethylene patch aortoplasty and end-to-end anastomosis for coarctation of the aorta. *J Thorac Cardiovasc Surg* 2003;126:521-8.
- [804] Yousif A, Kloppenburg G, Morshuis WJ, Heijmen R. Repair of adult aortic coarctation by resection and interposition grafting. *Interact CardioVasc Thorac Surg* 2016;23:526-30.
- [805] Sadeghipour P, Mohebbi B, Firouzi A, Khajali Z, Saedi S, Shafe O et al. Balloon-expandable cheatham-platinum stents versus self-expandable nitinol stents in coarctation of aorta: a randomized controlled trial. *JACC Cardiovasc Interv* 2022;15:308-17.
- [806] Pellenc Q, Girault A, Roussel A, Milleron O, Jondeau G, Castier Y. Preliminary experience with custom made hourglass shaped thoracic stent grafts for endovascular thoracic aortic coarctation repair in adults. *Eur J Vasc Endovasc Surg* 2021;62:1000-1.
- [807] Holzer RJ, Gauvreau K, McEnaney K, Watanabe H, Ringel R. Long-term outcomes of the coarctation of the aorta stent trials. *Circ Cardiovasc Interv* 2021;14:e010308.
- [808] Butera G, Manica JL, Marini D, Piazza L, Chessa M, Filho RI et al. From bare to covered: 15-year single center experience and follow-up in trans-catheter stent implantation for aortic coarctation. *Catheter Cardiovasc Interv* 2014;83:953-63.
- [809] Nogic J, McCormick LM, Francis R, Nerlekar N, Jaworski C, West NEJ et al. Novel bioabsorbable polymer and polymer-free metallic drug-eluting stents. *J Cardiol* 2018;71:435-43.
- [810] Choudhary P, Canniffe C, Jackson DJ, Tanous D, Walsh K, Celermajer DS. Late outcomes in adults with coarctation of the aorta. *Heart* 2015;101:1190-5.
- [811] Turek JW, Conway BD, Cavanaugh NB, Meyer AM, Aldoss O, Reinking BE et al. Bovine arch anatomy influences recoarctation rates in the era of the extended end-to-end anastomosis. *J Thorac Cardiovasc Surg* 2018;155:1178-83.
- [812] Brown ML, Burkhart HM, Connolly HM, Dearani JA, Cetta F, Li Z et al. Coarctation of the aorta: lifelong surveillance is mandatory following surgical repair. *J Am Coll Cardiol* 2013;62:1020-5.
- [813] Abjigitova D, Mokhles MM, Witsenburg M, van de Woestijne PC, Bekkers JA, Bogers A. Surgical repair of aortic coarctation in adults: half a century of a single centre clinical experience. *Eur J Cardiothorac Surg* 2019;56:1178-85.
- [814] Rajbanshi BG, Joshi D, Pradhan S, Gautam NC, Timala R, Shakya U et al. Primary surgical repair of coarctation of the aorta in adolescents and adults: intermediate results and consequences of hypertension. *Eur J Cardiothorac Surg* 2018;55:323-30.
- [815] Melissano G, Canaud L, Pacini D, Bilman V, Erben Y, Oo AY et al. International Rare Aortic Conditions (IRAC) Consortium. Surgical and endovascular treatment of late postcoarctation repair aortic aneurysms: results from an international multicenter study. *J Vasc Surg* 2022;76:1449-57.e4.
- [816] Koo BS, Koh YW, Hong S, Kim YJ, Kim YG, Lee CK et al. Frequency of immunoglobulin G4-related aortitis in cases with aortic resection and their clinical characteristics compared to other aortitises. *Int J Rheum Dis* 2014;17:420-4.
- [817] Svensson LG, Arafat A, Roselli EE, Idrees J, Clifford A, Tan C et al. Inflammatory disease of the aorta: patterns and classification of giant cell aortitis, Takayasu arteritis, and nonsyndromic aortitis. *J Thorac Cardiovasc Surg* 2015;149:S170-5.
- [818] Erkhem-Ochir B, Tatsuishi W, Yokobori T, Gombodorj N, Saeki H, Shirabe K et al. Immunohistochemical detection of bacteria in the resected valves was associated with stromal immune checkpoint protein expression that may contribute to calcific aortic stenosis. *Semin Thorac Cardiovasc Surg* 2022;34:1170-7.
- [819] Mestres CA, Quintana E. Commentary: are explanted aortic valves always infected? *Semin Thorac Cardiovasc Surg* 2022;34:1180-1.
- [820] Moazed TC, Kuo C, Grayston JT, Campbell LA. Murine models of *Chlamydia pneumoniae* infection and atherosclerosis. *J Infect Dis* 1997;175:883-90.
- [821] Juvonen J, Juvonen T, Laurila A, Alakärppä H, Lounatmaa K, Surcel HM et al. Demonstration of *Chlamydia pneumoniae* in the walls of abdominal aortic aneurysms. *J Vasc Surg* 1997;25:499-505.
- [822] Blessing E, Lin TM, Campbell LA, Rosenfeld ME, Lloyd D, Kuo C. *Chlamydia pneumoniae* induces inflammatory changes in the heart and aorta of normocholesterolemic C57BL/6J mice. *Infect Immun* 2000;68:4765-8.
- [823] Mazur E, Niedźwiadek J, Wolski A, Siezieniewska-Skowrońska Z, Zywick W, Korolczuk A et al. Chlamydia pneumoniae infection in abdominal aortic aneurysm (AAA) patients and its clinical impact. *Pol J Pathol* 2004;55:155-64.
- [824] Takaoka N, Campbell LA, Lee A, Rosenfeld ME, Kuo CC. *Chlamydia pneumoniae* infection increases adherence of mouse macrophages to mouse endothelial cells *in vitro* and to aortas *ex vivo*. *Infect Immun* 2008;76:510-4.
- [825] Nagarajan UM, Sikes JD, Burris RL, Jha R, Popovic B, Fraungruber P et al. Genital Chlamydia infection in hyperlipidemic mouse models exacerbates atherosclerosis. *Atherosclerosis* 2019;290:103-10.
- [826] Espitia O, Samson M, Le Gallou T, Connault J, Landron C, Lavigne C et al. Comparison of idiopathic (isolated) aortitis and giant cell arteritis-related aortitis. A French retrospective multicenter study of 117 patients. *Autoimmun Rev* 2016;15:571-6.
- [827] Nuenninghoff DM, Hunder GG, Christianson TJ, McClelland RL, Matteson EL. Incidence and predictors of large-artery complication (aortic aneurysm, aortic dissection, and/or large-artery stenosis) in patients with giant cell arteritis: a population-based study over 50 years. *Arthritis Rheum* 2003;48:3522-31.
- [828] Nuenninghoff DM, Hunder GG, Christianson TJ, McClelland RL, Matteson EL. Mortality of large-artery complication (aortic aneurysm, aortic dissection, and/or large-artery stenosis) in patients with giant cell arteritis: a population-based study over 50 years. *Arthritis Rheum* 2003;48:3532-7.
- [829] Hiratzka LF, Bakris GL, Beckman JA, Bersin RM, Carr VF, Casey DE Jr, et al. 2010 ACCF/AHA/AATS/ACR/ASA/SCA/SCAI/SIR/STS/SVM guidelines for the diagnosis and management of patients with Thoracic Aortic Disease: a report of the American College of Cardiology Foundation/American Heart Association Task Force on Practice Guidelines, American Association for Thoracic Surgery, American College of Radiology, American Stroke Association, Society of Cardiovascular Anesthesiologists, Society for Cardiovascular Angiography and Interventions, Society of Interventional Radiology, Society of Thoracic Surgeons, and Society for Vascular Medicine. *Circulation* 2010;121:e266-369.
- [830] Pacini D, Leone O, Turci S, Camurri N, Giunchi F, Martinelli GN et al. Incidence, etiology, histologic findings, and course of thoracic inflammatory aortopathies. *Ann Thorac Surg* 2008;86:1518-23.
- [831] Delaval L, Daumas A, Samson M, Ebbo M, De Boysson H, Liozon E et al. Large-vessel vasculitis diagnosed between 50 and 60 years: case-control study based on 183 cases and 183 controls aged over 60 years. *Autoimmun Rev* 2019;18:714-20.
- [832] Caterson HC, Li A, March L, Bannon PG, Marshman D, Wolfenden HD et al. Post-operative outcomes of inflammatory thoracic aortitis: a study of 41 patients from a cohort of 1119 surgical cases. *Clin Rheumatol* 2022;41:1219-26.
- [833] Lupi-Herrera E, Sánchez-Torres G, Marcushamer J, Mispireta J, Horwitz S, Vela JE. Takayasu's arteritis. Clinical study of 107 cases. *Am Heart J* 1977;93:94-103.
- [834] Moriwaki R, Numano F. Takayasu arteritis: follow-up studies for 20 years. *Heart Vessels Suppl* 1992;7:138-45.
- [835] Ishikawa K, Maetani S. Long-term outcome for 120 Japanese patients with Takayasu's disease. Clinical and statistical analyses of related prognostic factors. *Circulation* 1994;90:1855-60.
- [836] Subramanyan R, Joy J, Balakrishnan KG. Natural history of aortoarteritis (Takayasu's disease). *Circulation* 1989;80:429-37.
- [837] Dabague J, Reyes PA. Takayasu arteritis in Mexico: a 38-year clinical perspective through literature review. *Int J Cardiol* 1996;54 Suppl:S103-9.
- [838] Takayasu M. A case with curious change in the central retinal vessel. *Nippon Ganka Gakkai Zasshi (J Jpn Ophthalmol Soc)* 1908;12:554-5.
- [839] Hotchi M. Pathological studies on Takayasu arteritis. *Heart Vessels Suppl* 1992;7:11-7.
- [840] Ishikawa K. Diagnostic approach and proposed criteria for the clinical diagnosis of Takayasu's arteriopathy. *J Am Coll Cardiol* 1988;12:964-72.
- [841] Hata A, Noda M, Moriwaki R, Numano F. Angiographic findings of Takayasu arteritis: new classification. *Int J Cardiol* 1996;54 Suppl:S155-63.
- [842] Matsuura K, Ogino H, Kobayashi J, Ishibashi-Ueda H, Matsuda H, Minatoya K et al. Surgical treatment of aortic regurgitation due to Takayasu arteritis: long-term morbidity and mortality. *Circulation* 2005;112:3707-12.

- [843] Kaku Y, Aomi S, Tomioka H, Yamazaki K. Surgery for aortic regurgitation and aortic root dilatation in Takayasu arteritis. *Asian Cardiovasc Thorac Ann* 2015;23:901–6.
- [844] Matsuura K, Ogino H, Matsuda H, Minatoya K, Sasaki H, Yagihara T et al. Surgical outcome of aortic arch repair for patients with Takayasu arteritis. *Ann Thorac Surg* 2006;81:178–82.
- [845] Sundt TM. Clinical-pathologic conference in thoracic surgery: proximal pulmonary artery obstruction secondary to Takayasu arteritis. *J Thorac Cardiovasc Surg* 2001;121:163–75.
- [846] Nakajima N, Masuda M, Imamaki M, Ishida A, Tanabe N, Kuriyama T. A case of pulmonary artery bypass surgery for a patient with isolated Takayasu pulmonary arteritis and a review of the literature. *Ann Thorac Cardiovasc Surg* 2007;13:267–71.
- [847] Kim YW, Kim DI, Park YJ, Yang SS, Lee GY, Kim DK et al. Surgical bypass vs endovascular treatment for patients with supra-aortic arterial occlusive disease due to Takayasu arteritis. *J Vasc Surg* 2012;55:693–700.
- [848] Saadoun D, Lambert M, Mirault T, Resche-Rigon M, Koskas F, Cluzel P et al. Retrospective analysis of surgery versus endovascular intervention in Takayasu arteritis: a multicenter experience. *Circulation* 2012;125:813–9.
- [849] Lee GY, Jeon P, Do YS, Sung K, Kim DI, Kim YW et al. Comparison of outcomes between endovascular treatment and bypass surgery in Takayasu arteritis. *Scand J Rheumatol* 2014;43:153–61.
- [850] Labarca C, Makol A, Crowson CS, Kermani TA, Matteson EL, Warrington KJ. Retrospective comparison of open versus endovascular procedures for Takayasu arteritis. *J Rheumatol* 2016;43:427–32.
- [851] Rosa Neto NS, Shinjo SK, Levy-Neto M, Pereira RMR. Vascular surgery: the main risk factor for mortality in 146 Takayasu arteritis patients. *Rheumatol Int* 2017;37:1065–73.
- [852] Meng X, Zhao L, Dong X, Jiang X, Cai J, Zhang H et al. Mid-aortic syndrome is associated with increased left ventricular mass index in Takayasu arteritis. *Ann Transl Med* 2021;9:1124.
- [853] Joseph G, Goel R, Thomson VS, Joseph E, Danda D. Takayasu arteritis: JACC focus seminar 3/4. *J Am Coll Cardiol* 2023;81:172–86.
- [854] Hutchinson J. On a peculiar form of thrombotic arteritis of the aged which is sometimes productive of gangrene. *Arch Surg* 1890;1:323–9.
- [855] Horton B. An undescribed form of arteritis of temporal vessels. *Proc Staff Mayo Clin Proc* 1932;7:700–1.
- [856] Horton BT. Temporal arteritis; report of 39 cases. *Proc Annu Meet Cent Soc Clin Res U S* 1946;19:78.
- [857] Ostberg G. Temporal arteritis in a large necropsy series. *Ann Rheum Dis* 1971;30:224–35.
- [858] Ness T, Bley TA, Schmidt WA, Lamprecht P. The diagnosis and treatment of giant cell arteritis. *Dtsch Arztebl Int* 2013;110:376–85.
- [859] Butendieck R Jr, Calamia K, Sandin A. A study of temporal artery biopsy for the diagnosis of giant cell arteritis. *Clin Rheumatol* 2023;42:159–66.
- [860] Espitia O, Blonz G, Urbanski G, Landron C, Connault J, Lavigne C et al. French Study Group for Large Vessel Vasculitis (GEFA). Symptomatic aortitis at giant cell arteritis diagnosis: a prognostic factor of aortic event. *Arthritis Res Ther* 2021;23:14.
- [861] Koster MJ, Achenbach SJ, Crowson CS, Maradit-Kremers H, Matteson EL, Warrington KJ. Healthcare use and direct cost of giant cell arteritis: a population-based study. *J Rheumatol* 2017;44:1044–50.
- [862] Zehr KJ, Mathur A, Orszulak TA, Mullany CJ, Schaff HV. Surgical treatment of ascending aortic aneurysms in patients with giant cell aortitis. *Ann Thorac Surg* 2005;79:1512–7.
- [863] Mennander AA, Miller DV, Liang KP, Warrington KJ, Connolly HM, Schaff HV et al. Surgical management of ascending aortic aneurysm due to non-infectious aortitis. *Scand Cardiovasc J* 2008;42:417–24.
- [864] de Mornac D, Agard C, Hardouin JB, Hamidou M, Connault J, Masseur A et al. Risk factors for symptomatic vascular events in giant cell arteritis: a study of 254 patients with large-vessel imaging at diagnosis. *Ther Adv Musculoskelet Dis* 2021;13:1759720x211006967.
- [865] de Boysson H, Espitia O, Samson M, Tieulié N, Bachmeyer C, Moulinet T et al. French study group for large-vessel arteritis (GEFA). Giant cell arteritis-related aortic dissection: a multicenter retrospective study. *Semin Arthritis Rheum* 2021;51:430–5.
- [866] Clifford AH, Arafat A, Idrees JJ, Roselli EE, Tan CD, Rodriguez ER et al. Outcomes among 196 patients with noninfectious proximal aortitis. *Arthritis Rheumatol* 2019;71:2112–20.
- [867] Gagné-Loranger M, Dumont É, Voisine P, Mohammadi S, Garceau C, Dion B et al. Giant cell aortitis: clinical presentation and outcomes in 40 patients consecutively operated on. *Eur J Cardiothorac Surg* 2016;50:555–9.
- [868] Osler W. The gulstonian lectures, on malignant endocarditis. *Br Med J* 1885;1:467–70.
- [869] Sörelius K, Wyss TR, Adam D, Beck AW, Berard X, Budtz-Lilly J et al. Academic Research Consortium of Infective Native Aortic Aneurysm (ARC of INAA). Editor's choice—infected native aortic aneurysms: a Delphi consensus document on terminology, definition, classification, diagnosis, and reporting standards. *Eur J Vasc Endovasc Surg* 2023;65:323–9.
- [870] Foote EA, Postier RG, Greenfield RA, Bronze MS. Infectious aortitis. *Curr Treat Options Cardiovasc Med* 2005;7:89–97.
- [871] Osler W. The Schorstein lecture ON SYPHILIS AND ANEURYSM: delivered at the London Hospital, October, 1909. *Br Med J* 1909;2:1509–14.
- [872] Revest M, Decaux O, Cazalets C, Verohye JP, Jégo P, Grosbois B. [Thoracic infectious aortitis: microbiology, pathophysiology and treatment]. *Rev Med Interne* 2007;28:108–15.
- [873] Schmidt J, Sunesen K, Kornum JB, Duhaut P, Thomsen RW. Predictors for pathologically confirmed aortitis after resection of the ascending aorta: a 12-year Danish nationwide population-based cross-sectional study. *Arthritis Res Ther* 2011;13:R87.
- [874] Mestres CA, Ninot S, de Lacy AM, Castel MT, Iranzo P, Azon A et al. AIDS and Salmonella-infected abdominal aortic aneurysm. *Aust N Z J Surg* 1990;60:225–6.
- [875] Journeau L, de la Chapelle M, Guimard T, Ferfar Y, Saadoun D, Mahé I et al. A strobe multicenter descriptive study of 55 infectious aortitis. *Medicine (Baltimore)* 2020;99:e22422.
- [876] Pugh D, Grayson P, Basu N, Dhaun N. Aortitis: recent advances, current concepts and future possibilities. *Heart* 2021;107:1620–9.
- [877] Mikail N, Benali K, Dossier A, Bouleti C, Hyafil F, Le Guludec D et al. Additional diagnostic value of combined angio-computed tomography and (18)F-fluorodeoxyglucose positron emission tomography in infectious aortitis. *JACC Cardiovasc Imaging* 2018;11:361–4.
- [878] Husmann L, Huellner MW, Ledergerber B, Eberhard N, Kaelin MB, Anagnostopoulos A et al. Vasgra Cohort. Diagnostic accuracy of PET/CT and contrast enhanced CT in patients with suspected infected aortic aneurysms. *Eur J Vasc Endovasc Surg* 2020;59:972–81.
- [879] Husmann L, Huellner MW, Eberhard N, Ledergerber B, Kaelin MB, Anagnostopoulos A et al. PET/CT in therapy control of infective native aortic aneurysms. *Sci Rep* 2021;11:5065.
- [880] Husmann L, Huellner MW, Gruenig H, Eberhard N, Mestres CA, Rancic Z et al. Impact of PET/CT among patients with suspected mycotic aortic aneurysms. *PLoS One* 2021;16:e0258702.
- [881] Yu SY, Hsieh HC, Ko PJ, Huang YK, Chu JJ, Lee CH. Surgical outcome for mycotic aortic and iliac aneurysm. *World J Surg* 2011;35:1671–8.
- [882] Lau C, Gaudio M, de Biasi AR, Munjal M, Girardi LN. Outcomes of open repair of mycotic descending thoracic and thoracoabdominal aortic aneurysms. *Ann Thorac Surg* 2015;100:1712–7.
- [883] Yu SY, Lee CH, Hsieh HC, Chou AH, Ko PJ. Treatment of primary infected aortic aneurysm without aortic resection. *J Vasc Surg* 2012;56:943–50.
- [884] Sörelius K, Wanhainen A, Wahlgren CM, Langenskiöld M, Roos H, Resch T et al. Nationwide study on treatment of mycotic thoracic aortic aneurysms. *Eur J Vasc Endovasc Surg* 2019;57:239–46.
- [885] Obel LM, Diederichsen AC, Steffensen FH, Frost L, Lambrechtsen J, Busk M et al. Population-based risk factors for ascending, arch, descending, and abdominal aortic dilations for 60–74-year-old individuals. *J Am Coll Cardiol* 2021;78:201–11.
- [886] Cote CL, De Waard D, Kivell M, Fagan A, Horne G, Hassan A et al. Sex differences in trends in incidence of thoracic aortic aneurysm repair and aortic dissection: 2005–2015. *CJC Open* 2022;4:1081–9.
- [887] Rylski B, Georgieva N, Beyersdorf F, Büsch C, Boening A, Haunschild J et al. German Registry for Acute Aortic Dissection Type A Working Group of the German Society of Thoracic, Cardiac, and Vascular Surgery. Gender-related differences in patients with acute aortic dissection type A. *J Thorac Cardiovasc Surg* 2021;162:528–35.e1.
- [888] Nasiell J, Lindqvist PG. Aortic dissection in pregnancy: the incidence of a life-threatening disease. *Eur J Obstet Gynecol Reprod Biol* 2010;149:120–1.
- [889] Kamel H, Roman MJ, Pitcher A, Devereux RB. Pregnancy and the risk of aortic dissection or rupture: a cohort-crossover analysis. *Circulation* 2016;135:e782.
- [890] Carlson M, Silberbach M. Dissection of the aorta in Turner syndrome: two cases and review of 85 cases in the literature. *J Med Genet* 2007;44:745–9.

- [891] Grootenboer N, Bosch JL, Hendriks JM, van Sambeek MR. Epidemiology, aetiology, risk of rupture and treatment of abdominal aortic aneurysms: does sex matter? *Eur J Vasc Endovasc Surg* 2009;38:278–84.
- [892] Wanhainen A. How to define an abdominal aortic aneurysm—influence on epidemiology and clinical practice. *Scand J Surg* 2008;97:105–9.
- [893] Brown PM, Zelt DT, Sobolev B. The risk of rupture in untreated aneurysms: the impact of size, gender, and expansion rate. *J Vasc Surg* 2003;37:280–4.
- [894] Naylor AR, Forbes TL. Trans-Atlantic debate: whether evidence supports reducing the threshold diameter to 5 cm for elective interventions in women with abdominal aortic aneurysms. *Eur J Vasc Endovasc Surg* 2014;48:611.
- [895] Mwiipatayi BP, Anwari T, Wong J, Verhoeven E, Dubencs S, Heyligers JM et al. Sex-related outcomes after endovascular aneurysm repair within the global registry for endovascular aortic treatment. *Ann Vasc Surg* 2020;67:242–53.e4.
- [896] Ramkumar N, Suckow BD, Arya S, Sedrakyan A, Mackenzie TA, Goodney PP et al. Association of sex with repair type and long-term mortality in adults with abdominal aortic aneurysm. *JAMA Netw Open* 2020;3:e1921240.
- [897] Indrakusuma R, Jalalzadeh H, Vahl AC, Koelemay MJW, Balm R. Editor's choice—sex related differences in peri-operative mortality after elective repair of an asymptomatic abdominal aortic aneurysm in the Netherlands: a retrospective analysis of 2013 to 2018. *Eur J Vasc Endovasc Surg* 2019;58:813–20.
- [898] Chartier AL, Bouvier MJ, McPherson DR, Stepenosky JE, Taysom DA, Marks RM. The safety of maternal and fetal MRI at 3 T. *AJR Am J Roentgenol* 2019;213:1170–3.
- [899] Cauldwell M, Steer PJ, Curtis SL, Mohan A, Dockree S, Mackillop L et al. Maternal and fetal outcomes in pregnancies complicated by Marfan syndrome. *Heart* 2019;105:1725–31.
- [900] Campens L, Baris L, Scott NS, Broberg CS, Bondue A, Jondeau G et al. ROPAC investigators group. Pregnancy outcome in thoracic aortic disease data from the Registry Of Pregnancy And Cardiac disease. *Heart* 2021;107:1704–9.
- [901] Braverman AC, Mittauer E, Harris KM, Evangelista A, Pyeritz RE, Brinster D et al. Clinical features and outcomes of pregnancy-related acute aortic dissection. *JAMA Cardiol* 2021;6:58–66.
- [902] Cauldwell M, Steer PJ, Curtis S, Mohan AR, Dockree S, Mackillop L et al. Maternal and fetal outcomes in pregnancies complicated by the inherited aortopathy Loays-Dietz syndrome. *BJOG* 2019;126:1025–31.
- [903] Murray ML, Pepin M, Peterson S, Byers PH. Pregnancy-related deaths and complications in women with vascular Ehlers-Danlos syndrome. *Genet Med* 2014;16:874–80.
- [904] Roos-Hesselink JW, Budts W, Walker F, De Backer JFA, Swan L, Stones W et al. Organisation of care for pregnancy in patients with congenital heart disease. *Heart* 2017;103:1854–9.
- [905] Roman MJ, Pugh NL, Hendershot TP, Devereux RB, Dietz H, Holmes K et al. Aortic complications associated with pregnancy in marfan syndrome: the NHLBI National Registry of Genetically Triggered Thoracic Aortic Aneurysms and Cardiovascular Conditions (GenTAC). *J Am Heart Assoc* 2016;5:e004052.
- [906] MacCarrick G, Black JH 3rd, Bowdin S, El-Hamamsy I, Frischmeyer-Guerrero PA, Guerrero AL et al. Loays-Dietz syndrome: a primer for diagnosis and management. *Genet Med* 2014;16:576–87.
- [907] Donnelly RT, Pinto NM, Kocolas I, Yetman AT. The immediate and long-term impact of pregnancy on aortic growth rate and mortality in women with Marfan syndrome. *J Am Coll Cardiol* 2012;60:224–9.
- [908] Kuperstein R, Cahan T, Yoeli-Ullman R, Ben Zekry S, Shinfeld A, Simchen MJ. Risk of aortic dissection in pregnant patients with the Marfan syndrome. *Am J Cardiol* 2017;119:132–7.
- [909] Regitz-Zagrosek V, Roos-Hesselink JW, Bauersachs J, Blomström-Lundqvist C, Cifková R, De Bonis M et al. ESC Scientific Document Group. 2018 ESC Guidelines for the management of cardiovascular diseases during pregnancy. *Eur Heart J* 2018;39:3165–241.
- [910] Silberbach M, Roos-Hesselink JW, Andersen NH, Braverman AC, Brown N, Collins RT et al. Cardiovascular health in turner syndrome: a scientific statement from the American Heart Association. *Circ Genom Precis Med* 2018;11:e000048.
- [911] Seely EW, Ecker J. Chronic hypertension in pregnancy. *Circulation* 2014;129:1254–61.
- [912] Loays BL, Dietz HC, Braverman AC, Callewaert BL, De Backer J, Devereux RB et al. The revised Ghent nosology for the Marfan syndrome. *J Med Genet* 2010;47:476–85.
- [913] Suzuki K, Yamashita S. Low-dose radiation exposure and carcinogenesis. *Jpn J Clin Oncol* 2012;42:563–8.
- [914] Mollet NR, Cademartiri F, van Mieghem CA, Runza G, McFadden EP, Baks T et al. High-resolution spiral computed tomography coronary angiography in patients referred for diagnostic conventional coronary angiography. *Circulation* 2005;112:2318–23.
- [915] Harbron RW, Abdelhalim M, Ainsbury EA, Eakins JS, Alam A, Lee C et al. Patient radiation dose from x-ray guided endovascular aneurysm repair: a Monte Carlo approach using voxel phantoms and detailed exposure information. *J Radiol Prot* 2020;40:704–26.
- [916] Tuthill E, O'Hara L, O'Donohoe M, Panci S, Gilligan P, Campion D et al. Investigation of reference levels and radiation dose associated with abdominal EVAR (endovascular aneurysm repair) procedures across several European Centres. *Eur Radiol* 2017;27:4846–56.
- [917] El-Sayed T, Patel AS, Cho JS, Kelly JA, Ludwinski FE, Saha P et al. Guy's and St Thomas' Cardiovascular Research Collaborative. Radiation-induced DNA damage in operators performing endovascular aortic repair. *Circulation* 2017;136:2406–16.
- [918] McNally MM, Scali ST, Feezor RJ, Neal D, Huber TS, Beck AW. Three-dimensional fusion computed tomography decreases radiation exposure, procedure time, and contrast use during fenestrated endovascular aortic repair. *J Vasc Surg* 2015;61:309–16.
- [919] Tacher V, Lin M, Desgranges P, Deux JF, Grünhagen T, Becquemin JP et al. Image guidance for endovascular repair of complex aortic aneurysms: comparison of two-dimensional and three-dimensional angiography and image fusion. *J Vasc Interv Radiol* 2013;24:1698–706.
- [920] Mohapatra A, Greenberg RK, Mastracci TM, Eagleton MJ, Thornsberry B. Radiation exposure to operating room personnel and patients during endovascular procedures. *J Vasc Surg* 2013;58:702–9.
- [921] Karkouti K, Callum J, Wijesundera DN, Rao V, Crowther M, Grocott HP et al. TACS Investigators. Point-of-care hemostatic testing in cardiac surgery: a stepped-wedge clustered randomized controlled trial. *Circulation* 2016;134:1152–62.
- [922] Deppe AC, Weber C, Zimmermann J, Kuhn EW, Slotosch I, Liakopoulos OJ et al. Point-of-care thromboelastography/thromboelastometry-based coagulation management in cardiac surgery: a meta-analysis of 8332 patients. *J Surg Res* 2016;203:424–33.
- [923] Fuda G, Denault A, Deschamps A, Bouchard D, Fortier A, Lambert J et al. Risk factors involved in central-to-radial arterial pressure gradient during cardiac surgery. *Anesth Analg* 2016;122:624–32.
- [924] Bouchard-Dechêne V, Couture P, Su A, Deschamps A, Lamarche Y, Desjardins G et al. Risk factors for radial-to-femoral artery pressure gradient in patients undergoing cardiac surgery with cardiopulmonary bypass. *J Cardiothorac Vasc Anesth* 2018;32:692–8.
- [925] Hypothermia: prevention and management in adults having surgery. London: National Institute for Health and Care Excellence (NICE); 2016 Dec. (NICE Clinical Guidelines, No. 65.) Available from: <https://www.ncbi.nlm.nih.gov/books/NBK554181/> (8 February 2024, date last accessed).
- [926] Geirsson A, Szeto WY, Pochettino A, McGarvey ML, Keane MG, Woo YJ et al. Significance of malperfusion syndromes prior to contemporary surgical repair for acute type A dissection: outcomes and need for additional revascularizations. *Eur J Cardiothorac Surg* 2007;32:255–62.
- [927] Chandra VM, Norton EL, Khaja MS, Herrera DG, Williams DM, Yang B. Surgical and endovascular repair for type B aortic dissections with mesenteric malperfusion syndrome: a systematic review of in-hospital mortality. *JTCVS Open* 2022;12:37–50.
- [928] Kaufeld T, Beckmann E, Rudolph L, Krüger H, Natanov R, Arar M et al. Impact of preoperative malperfusion on postoperative outcomes in type A aortic dissection—importance of serum lactate estimation in ongoing malperfusion. *Perfusion* 2023;2676591231157545.
- [929] McGinigle KL, Spangler EL, Pichel AC, Ayyash K, Arya S, Settembrini AM et al. Perioperative care in open aortic vascular surgery: a consensus statement by the Enhanced Recovery After Surgery (ERAS) Society and Society for Vascular Surgery. *J Vasc Surg* 2022;75:1796–820.
- [930] Agüero-Martínez MO, Tapia-Figueroa VM, Hidalgo-Costa T. Improved recovery protocols in cardiac surgery: a systematic review and meta-analysis of observational and quasi-experimental studies. *MEDICC Rev* 2021;23:46–53.
- [931] Pagano D, Milojevic M, Meesters MI, Benedetto U, Bolliger D, von Heymann C et al. 2017 EACTS/EACTA Guidelines on patient blood management for adult cardiac surgery. *Eur J Cardiothorac Surg* 2018;53:79–111.
- [932] Kaufman RM, Djulbegovic B, Gernsheimer T, Kleinman S, Tinmouth AT, Capocelli KE et al. AABB. Platelet transfusion: a clinical practice guideline from the AABB. *Ann Intern Med* 2015;162:205–13.

- [933] Stephens RS, Whitman GJ. Postoperative critical care of the adult cardiac surgical patient. Part I: routine postoperative care. *Crit Care Med* 2015;43:1477–97.
- [934] Benedetto U, Dimagli A, Kaura A, Sinha S, Mariscalco G, Krasopoulos G et al. Determinants of outcomes following surgery for type A acute aortic dissection: the UK National Adult Cardiac Surgical Audit. *Eur Heart J* 2021;43:44–52.
- [935] Mariani C, Botta L, Leone A, Murana G, Berardi M, Coppola G et al. Visceral malperfusion after frozen elephant trunk in chronic aortic dissection: post-operative predictors and outcomes. *Int J Cardiol* 2021;335:26–31.
- [936] Westaby S. Coagulation disturbance in profound hypothermia: the influence of anti-fibrinolytic therapy. *Semin Thorac Cardiovasc Surg* 1997;9:246–56.
- [937] Guo J, Cao L, Wang H, Liu G, Zhou Y, Yang L et al. High-dose tranexamic acid in patients underwent surgical repair of aortic dissection might reduce postoperative blood loss: a cohort analysis. *Front Surg* 2022;9:898579.
- [938] Martens A, Beckmann E, Kaufeld T, Arar M, Natanov R, Fleissner F et al. Features and risk factors of early intraluminal thrombus formation within the frozen elephant trunk stent graft. *J Thorac Cardiovasc Surg* 2023;S0022-5223(23)00082-X.
- [939] Rahe-Meyer N, Hanke A, Schmidt DS, Hagl C, Pichlmaier M. Fibrinogen concentrate reduces intraoperative bleeding when used as first-line hemostatic therapy during major aortic replacement surgery: results from a randomized, placebo-controlled trial. *J Thorac Cardiovasc Surg* 2013;145:S178–85.
- [940] Grottko O, Schöchel H, Levy JH, Hunt BJ. Supplementary fibrinogen in the management of bleeding: re-evaluation of data from clinical trials. *Br J Anaesth* 2018;120:407–9.
- [941] Green MS, Sehgal S, Tariq R. Near-infrared spectroscopy: the new must have tool in the intensive care unit? *Semin Cardiothorac Vasc Anesth* 2016;20:213–24.
- [942] Felli A, Skhirtladze-Dworschak K, Opfermann P, Dworschak M. Limitations of cerebral oximetry in a patient with an intracerebral hemorrhage and brain edema on extracorporeal membrane oxygenation: a case report. *A A Pract* 2019;12:390–2.
- [943] Tsagakis K, Osswald A, Weymann A, Demircioglu A, Schmack B, Wendt D et al. The frozen elephant trunk technique: impact of proximalization and the four-sites perfusion technique. *Eur J Cardiothorac Surg* 2021;61:195–203.
- [944] Leontyev S, Tsagakis K, Pacini D, Di Bartolomeo R, Mohr FW, Weiss G et al. Impact of clinical factors and surgical techniques on early outcome of patients treated with frozen elephant trunk technique by using EVITA open stent-graft: results of a multicentre study. *Eur J Cardiothorac Surg* 2016;49:660–6.
- [945] Leontyev S, Misfeld M, Daviewala P, Borger MA, Eitz CD, Belae S et al. Early- and medium-term results after aortic arch replacement with frozen elephant trunk techniques—a single center study. *Ann Cardiothorac Surg* 2013;2:606–11.
- [946] Katayama K, Uchida N, Katayama A, Takahashi S, Takasaki T, Kurosaki T et al. Multiple factors predict the risk of spinal cord injury after the frozen elephant trunk technique for extended thoracic aortic disease. *Eur J Cardiothorac Surg* 2015;47:616–20.
- [947] Kreibich M, Berger T, Rylski B. The frozen elephant trunk: a one-stage, two-stage or even three-stage treatment? *Eur J Cardiothorac Surg* 2021;60:352–3.
- [948] Liebrich M, Charitos EI, Schlereth S, Meißner H, Trabold T, Geisbüsch P et al. The zone 2 concept and distal stent graft positioning in TH 2-3 are associated with high rates of secondary aortic interventions in frozen elephant trunk surgery. *Eur J Cardiothorac Surg* 2021;60:343–51.
- [949] Theodore N, Martirosyan N, Hersh AM, Ehresman J, Ahmed AK, Danielson J et al. Cerebrospinal fluid drainage in patients with acute spinal cord injury: a multi-center randomized controlled trial. *World Neurosurg* 2023;177:e472–e479.
- [950] Chatterjee S, Preventza O, Coselli JS. Commentary: the aggregation of marginal gains for spinal cord protection. *JTCVS Tech* 2021;6:9–10.
- [951] Leung AD, Bartline PB, Acher CW, Yamanouchi D. Spinal cord ischemia rescue after hybrid total arch repair with frozen elephant trunk: a case report. *Ann Vasc Surg* 2020;66:669.e5–e9.
- [952] Spratt JR, Walker KL, Neal D, Arnaoutakis GJ, Martin TD, Back MR et al. Rescue therapy for symptomatic spinal cord ischemia after thoracic endovascular aortic repair. *J Thorac Cardiovasc Surg* 2022;S0022-5223(22)01168-0.
- [953] Walter T, Berger T, Kondov S, Gottardi R, Benk J, Rylski B et al. Postoperative in-stent thrombus formation following frozen elephant trunk total arch repair. *Front Cardiovasc Med* 2022;9:921479.
- [954] Misfeld M, Marin-Cuartas M, Ramirez P, Wehrmann K, Renatus K, Deo SV et al. Early intraluminal frozen elephant trunk stent graft thrombosis after aortic arch surgery. *Ann Thorac Surg* 2023;116:450–57.
- [955] Chan YC, Morales JP, Reidy JF, Taylor PR. Management of spontaneous and iatrogenic retroperitoneal haemorrhage: conservative management, endovascular intervention or open surgery? *Int J Clin Pract* 2008;62:1604–13.
- [956] Buth J, Harris PL, Hobo R, van Eps R, Cuypers P, Duijm L et al. Neurologic complications associated with endovascular repair of thoracic aortic pathology: incidence and risk factors. a study from the European Collaborators on Stent/Graft Techniques for Aortic Aneurysm Repair (EUROSTAR) registry. *J Vasc Surg* 2007;46:1103–10; discussion 1110–1.
- [957] Greenberg RK, Lu Q, Roselli EE, Svensson LG, Moon MC, Hernandez AV et al. Contemporary analysis of descending thoracic and thoracoabdominal aneurysm repair: a comparison of endovascular and open techniques. *Circulation* 2008;118:808–17.
- [958] Aucoin VJ, Eagleton MJ, Farber M, Oderich GS, Schanzer A, Timaran CH et al. Spinal cord protection practices used during endovascular repair of complex aortic aneurysms by the U.S. Aortic Research Consortium. *J Vasc Surg* 2021;73:323–30.
- [959] Vandy FC, Girotti M, Williams DM, Eliason JL, Dasika NL, Michael Deeb G et al. Iliofemoral complications associated with thoracic endovascular aortic repair: frequency, risk factors, and early and late outcomes. *J Thorac Cardiovasc Surg* 2014;147:960–5.
- [960] Nelson PR, Kracjer Z, Kansal N, Rao V, Bianchi C, Hashemi H et al. A multicenter, randomized, controlled trial of totally percutaneous access versus open femoral exposure for endovascular aortic aneurysm repair (the PEVAR trial). *J Vasc Surg* 2014;59:1181–93.
- [961] Suzuki T, Mehta RH, Ince H, Nagai R, Sakomura Y, Weber F et al. International Registry of Aortic Dissection. Clinical profiles and outcomes of acute type B aortic dissection in the current era: lessons from the International Registry of Aortic Dissection (IRAD). *Circulation* 2003;108 Suppl 1:II312–7.
- [962] Wang GJ, Cambria RP, Lombardi JV, Azzizadeh A, White RA, Abel DB et al. Thirty-day outcomes from the Society for Vascular Surgery Vascular Quality Initiative thoracic endovascular aortic repair for type B dissection project. *J Vasc Surg* 2019;69:680–91.
- [963] Brook RD, Appel LJ, Rubenfire M, Ogedegbe G, Bisognano JD, Elliott WJ et al. American Heart Association Professional Education Committee of the Council for High Blood Pressure Research, Council on Cardiovascular and Stroke Nursing, Council on Epidemiology and Prevention, and Council on Nutrition, Physical Activity. Beyond medications and diet: alternative approaches to lowering blood pressure: a scientific statement from the American heart association. *Hypertension* 2013;61:1360–83.
- [964] MacDougall JD, Tuxen D, Sale DG, Moroz JR, Sutton JR. Arterial blood pressure response to heavy resistance exercise. *J Appl Physiol* (1985) 1985;58:785–90.
- [965] Braverman AC, Harris KM, Kovacs RJ, Maron BJ; American Heart Association and American College of Cardiology. Eligibility and disqualification recommendations for competitive athletes with cardiovascular abnormalities: task force 7: aortic diseases, including marfan syndrome: a scientific statement from the American Heart Association and American College of Cardiology. *Circulation* 2015;132:e303–9.
- [966] Thijssen CGE, Bons LR, Gökalp AL, Van Kimmenade RRJ, Mokhles MM, Pelliccia A et al. Exercise and sports participation in patients with thoracic aortic disease: a review. *Expert Rev Cardiovasc Ther* 2019;17:251–66.
- [967] de Souza Nery S, Gomides RS, da Silva GV, de Moraes Forjaz CL, Mion D Jr, Tinucci T. Intra-arterial blood pressure response in hypertensive subjects during low- and high-intensity resistance exercise. *Clinics (Sao Paulo)* 2010;65:271–7.
- [968] Chaddha A, Kline-Rogers E, Woznicki EM, Brook R, Housholder-Hughes S, Braverman AC et al. Cardiology patient page. Activity recommendations for post-aortic dissection patients. *Circulation* 2014;130:e140–2.
- [969] Fuglsang S, Heiberg J, Hjortdal VE, Laustsen S. Exercise-based cardiac rehabilitation in surgically treated type-A aortic dissection patients. *Scand Cardiovasc J* 2017;51:99–105.

- [970] Spanos K, Tsilimparis N, Kölbel T. Exercise after aortic dissection: to run or not to run. *Eur J Vasc Endovasc Surg* 2018;55:755–6.
- [971] Lin Y, Chen Y, Zhang H, Peng Y, Li S, Huang X et al. Predictors of return to work after open triple-branched stent graft placement for acute type A aortic dissection. *Interact CardioVasc Thorac Surg* 2019;30:99–106.
- [972] Norton EL, Wu KH, Rubenfire M, Fink S, Sitzmann J, Hobbs RD et al. Cardiorespiratory fitness after open repair for acute type A aortic dissection—a prospective study. *Semin Thorac Cardiovasc Surg* 2022;34:827–39.
- [973] Corone S, Iliou MC, Pierre B, Feige JM, Odjinkem D, Farrokhi T et al. Cardiac Rehabilitation working Group of the French Society of Cardiology. French registry of cases of type I acute aortic dissection admitted to a cardiac rehabilitation center after surgery. *Eur J Cardiovasc Prev Rehabil* 2009;16:91–5.
- [974] Schwaab B, Rauch B, Völler H, Benzer W, Schmid JP. Beyond randomised studies: recommendations for cardiac rehabilitation following repair of thoracic aortic aneurysm or dissection. *Eur J Prev Cardiol* 2022;28:e17–19.
- [975] Rylski B, Hahn N, Beyersdorf F, Kondov S, Wolkewitz M, Blanke P et al. Fate of the dissected aortic arch after ascending replacement in type A aortic dissection. *Eur J Cardiothorac Surg* 2017;51:1127–34.
- [976] Ikeno Y, Yokawa K, Yamanaka K, Inoue T, Tanaka H, Okada K et al. The fate of the downstream aorta after total arch replacement. *Eur J Cardiothorac Surg* 2022;62:ezac443.
- [977] Berger T, Kreibich M, Mueller F, Rylski B, Kondov S, Schröfel H et al. The frozen elephant trunk technique for aortic dissection is safe after previous aortic repair. *Eur J Cardiothorac Surg* 2021;59:130–6.
- [978] Berger T, Graap M, Rylski B, Fagu A, Gottardi R, Walter T et al. Distal aortic failure following the frozen elephant trunk procedure for aortic dissection. *Front Cardiovasc Med* 2022;9:911548.
- [979] Kreibich M, Berger T, Rylski B, Chen Z, Beyersdorf F, Siepe M et al. Aortic reinterventions after the frozen elephant trunk procedure. *J Thorac Cardiovasc Surg* 2020;159:392–9.e1.
- [980] Cheng L, Xiang D, Zhang S, Zheng C, Wu X. Reintervention after thoracic endovascular aortic repair of uncomplicated type B aortic dissection. *J Clin Med* 2023;12:1418.
- [981] Xiang D, Chai B, Gui Y, Huang J, Liang H, Liang B et al. Risk factors for distal stent graft-induced new entry after endovascular repair in uncomplicated type B aortic dissection. *J Vasc Surg* 2023;77:37–45.e1.
- [982] Li C, de Guerre L, Dansey K, Lu J, Patel PB, Yao M et al. The impact of completion and follow-up endoleaks on survival, reintervention, and rupture. *J Vasc Surg* 2023;77:1676–84.
- [983] Chaddha A, Kline-Rogers E, Braverman AC, Erickson SR, Jackson EA, Franklin BA et al. Survivors of aortic dissection: activity, mental health, and sexual function. *Clin Cardiol* 2015;38:652–9.